

# Trephine craniotomy for evacuation of posterior fossa extradural hematoma

Sunil Kumar Singh M Ch, Bal Krishna Ojha M Ch, Manu Rastogi M Ch  
Anil Chandra M Ch, Mazhar Husain M Ch

Department of Neurosurgery, King George's Medical University, Lucknow- 226003

**Abstract:** Extradural hematomas (EDH) commonly occur in the supratentorial region where these are evacuated by trephine or craniotomy. Posterior fossa EDH (PFEDH) account for 4% to 12.9% of all cranial EDH and the standard method for evacuation of PFEDH involves a suboccipital craniectomy. Use of a trephine craniotomy for evacuation of PFEDH has not yet been described. This is the first report describing our experience in 8 patients with PFEDH where a sub occipital trephine craniotomy was used for evacuation of PFEDH. Eight patients with PFEDH were operated at our institution using a trephine for making a sub occipital craniotomy. Park bench position was used in all patients. The procedure was safely and expeditiously completed with no significant peri-operative complications related to the procedure. Operative time was comparatively shorter than for traditionally described procedures. Replacing the bone flap also avoids any scope for the possibility of occurrence of the sinking skin flap syndrome. We think that using a trephine for making a sub occipital craniotomy for evacuation of PFEDH is a feasible and safe option. There is no added risk of venous sinus injury. Replacing the bone flap helps to restore the normal anatomy. Use of central and peripheral dural hitch sutures in patients of traumatic PFEDH is feasible and avoids any possible reaccumulation of hematoma.

**Keywords:** epidural hematoma, posterior fossa surgery, trephine

## INTRODUCTION

Extradural haematomas of the posterior fossa are a rare but serious complication of head injuries. Extradural hematomas (EDH) occur in less than 2% of patients admitted with cranio-cerebral trauma<sup>1,2</sup>, while in most series, posterior fossa extradural haematomas (PFEDH) themselves account for 4% to 12.9% of all EDH<sup>1,3</sup>. Mortality rates for this type of injury have been reported to be 15.6% to 50%<sup>4,5</sup>. Bleeding in PFEDH is thought to be venous in most cases<sup>2</sup>. A tear in the venous sinuses is the commonest site of bleeding in PFEDH<sup>6</sup>. Surgical evacuation of PFEDH involves performing a craniectomy over the hematoma, or a formal craniotomy may be made if the hematoma is seen extending into the supratentorial region<sup>7,8,9</sup>. We present here 8 cases of PFEDH that were evacuated using a trephine craniotomy with favorable outcome in all cases.

## MATERIAL AND METHODS

### Patient characteristics

Eight patients (All males, 8-50 years, mean 29.5, median

#### Address for Correspondence:

Dr. S K Singh  
Department of Neurosurgery,  
King George's Medical University, Lucknow- 226003  
Ph: +91 11-29849010, Fax +91- 11-29849028  
E-mail address: drsksingh2k@gmail.com

31) with traumatic PFEDH (Fig 1) who were admitted in the Department of Neurosurgery between December 2004 and May 2006 formed the study group. Clinical details of the patients are summarized in Table 1. Two patients had CSF otorrhoea, one had fracture shaft femur and two had evidence of aspiration pneumonia. Two patients required tracheostomy during management.

### General Management Protocol

After initial resuscitation and clinical assessment, CT scan head was obtained and the patient was admitted to the neurosurgical intensive care unit. The type of head injury as determined from initial CT scan, time of injury and mode of injury were recorded. All patients were managed according to a standard protocol, including intensive care management, mechanical ventilation and intracranial pressure (ICP) monitoring whenever needed. Blood pressure, arterial oxygen saturation and temperature were monitored non-invasively. Sedatives, vasopressors (e.g. Dopamine), mannitol, blood products, antiepileptics, H<sub>2</sub>-receptor blockers were administered as and when required. Serial CT scans were obtained and craniotomies were performed for removal of other hematomas and/or other decompressive procedures as and when clinically indicated.

### Surgical details

All patients were operated in park bench position under

Table 1:

C.No.	Age/Sex	Mode Of Injury	GCS <sup>â</sup> - Admission	Associated Injuries	GCS <sup>â</sup> - Discharge	OP. TIME
1	M/20	RTA <sup>â†</sup>	E3V4M5	CSF OTORRHOEA	E4V5M6	55 Mins
2	M/32	RTA	E3V4M5	CSF OTORRHOEA	E4V5M6	40 Mins
3	M/37	FALL OF TREE BRANCH	E1V1M5	ASPIRATION PNEUMONIA, FEBRILE, TACHYPNOIC	E4V5M6	30 Mins
4	M/38	RTA	E3V3M5	NONE	E4V5M6	45 Mins
5	M/22	RTA	E3V4M6	NONE	E4V5M6	40 Mins
6	M/30	RTA	E1VTM2	ASPIRATION PNEUMONIA (SPO2 -68%), # RT SHAFT FEMUR, AND MULTIPLE RIBS	E4V <sub>T</sub> M5	40 Mins
7	M/8	FFH <sup>â§</sup>	E1V1M3	LOWER CRANIAL NERVES PALSY	E4V <sub>T</sub> M4	45 Mins
8	M/50	RTA	E2V2M5	NONE	E4V5M6	35 Mins

\* C. No.- Case Number, â• GCS- Glasgow Coma Scale, â† RTA- Road Traffic Accident, â§ FFH- Fall From Height

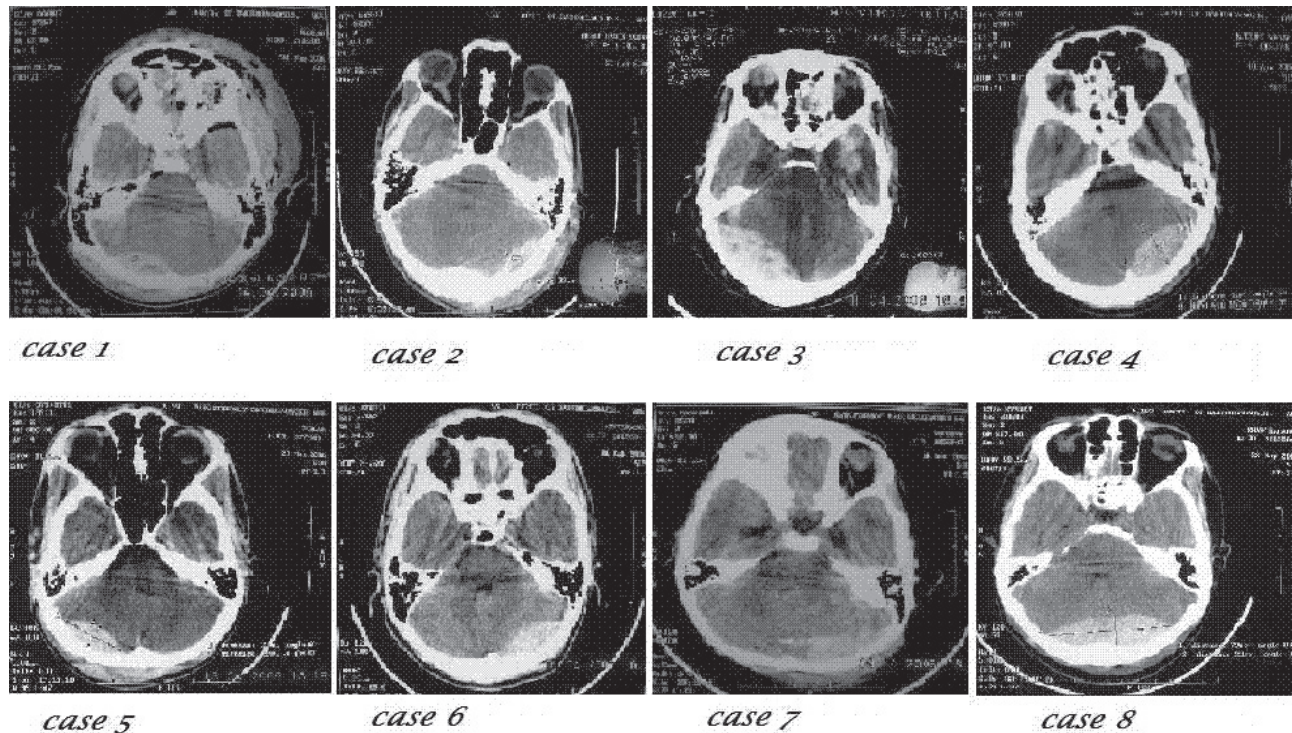


Fig 1: Pre operative axial CT scan (representative posterior fossa cuts) of C. No. 1- 8 showing posterior fossa EDH

GA. On the basis of CT scan findings the trephine margin was planned to overlie the thickest part of the EDH. A linear paramedian incision was used and muscle and periosteum were retracted using a mastoid retractor. We used a Skull Trephine Craniotome (*Gesco, India*) of 30mm / 50mm size to perform a craniotomy. No effort

was made to specifically avoid the venous sinus area when the EDH seemed to be crossing it, and, the trephine was in fact placed over the transverse sinus (C. No. 3) and over the torcula herophili (C. No. 5 and 8). We did not try to forcefully remove parts of the clot adherent over the venous sinuses. After evacuation of EDH

hemostasis was easily achieved in all patients. We used central and peripheral dural hitch sutures in all these patients of traumatic PFEDH to avoid any reaccumulation of blood. The bone flap was replaced in 7 patients. In one patient, fracture of the occipital bone (C. No. 3) was comminuted necessitating removal of the bone pieces. Evacuation of the frontal contusion was carried out in one patient (C. No. 4) after posterior fossa surgery.

#### Clinical Outcome:

A Glasgow Outcome Scale score (GOS) was determined at 3-12 months (mean 4.12 months) follow-up after injury. Patients were assigned to one of five categories: death, persistent vegetative state, severe disability, moderate disability or good recovery. Patients were considered to have achieved a "good" outcome if they were assigned to the moderate disability or good recovery categories, and a "poor" outcome if they died or were assigned to the persistent vegetative state or severe disability groups.

## RESULTS

Four patients (C. No. 3, 4, 5 and 7) had hydrocephalus, of which two (C. No. 3 and 4) resolved post operatively, one patient (C. No. 7) required insertion of a VP shunt and the other patient (C. No. 5) remained asymptomatic (arrested type) and needed no intervention. Two patients (C. No. 3 and 6) with severe respiratory problems recovered well post operatively following improvement in GCS. Four patients (50%) had an associated frontal contusion (three contralateral (C. No. 4, 5 and 6) and one ipsilateral (C. No. 2)), whereas one had a contralateral temporal contusion (C. No. 3). Two patients (C. No. 7 and 8) had an underlying cerebellar contusion (25%), which however did not require surgical intervention and resolved spontaneously. Two patients (C. No. 1 and 2) had pneumocephalus associated with CSF otorrhoea (25%), of which one required insertion of a lumbar drain for 3 days. CT findings at the time of admission are summarized in Table 2.

Six patients were operated upon within 24 hours of injury whereas C. No. 3 and 6 presented 48 to 72 hours after injury and surgery was performed thereafter. There were no significant per operative difficulties encountered. None of the patients had an associated foramen magnum fracture or upper cervical spine injury.

Six patients had a good outcome (75%), while two

Table 2

C.No.	CT Scan Findings	PFEDH-TYPE	GOS
1	LT PFEDH WITH PNEUMOCEPHALUS	MIXED	5
2	LT PFEDH WITH LT FRONTAL CONTUSION AND SAH WITH PNEUMOCEPHALUS AND # OCCIPITAL BONE	PURE	5
3	LT PFEDH + RT TEMPORAL CONTUSION WITH COMMUNATED # LT OCCIPITAL BONE	MIXED	5
4	LT PFEDH WITH RT FRONTAL CONTUSION AND # LT OCCIPITAL BONE	MIXED	5
5	RT PFEDH WITH ARRESTED HYDROCEPHALUS WITH LT FRONTAL CONTUSION AND # OCCIPITAL BONE	MIXED	5
6	LT PFEDH + RT FRONTAL CONTUSION	PURE	3
7	PFEDH WITH UNDERLYING CONTUSION WITH # LT OCCIPITAL BONE AND HYDROCEPHALUS	MIXED	3
8	PFEDH WITH UNDERLYING CONTUSION WITH # OCCIPITAL BONE	MIXED, BILATERAL	5

\* PFEDH – Posterior Fossa Epidural Hematoma

\*\* 'PURE' PFEDH refers to those which lie entirely below the tent, while 'mixed' PFEDH refers to those which lie partly above the tent.

patients (cases 6 and 7) had a poor outcome. Both the patients with a poor outcome had a low GCS (4/15 & 5/15) at the time of admission.

There was no problem in making the trephine craniotomy in any of the patients. During evacuation of PFEDH significant bleeding from a torn transverse sinus occurred in only one patient (C. No. 8), which was controlled with *SURGICEL*\* *Absorbable Hemostat* and dural hitch sutures. Diffuse oozing from the dural surface was present in almost all cases. Though hemostasis was easily achieved in all other patients, central and peripheral dural hitch sutures were applied at the end of the procedure. The bone flap was replaced in all patients (Figs 2, 3 & 4) except one (C. No. 3) who had a comminuted fracture of the occipital bone. Postoperative C T scan, obtained in all patients in 48-72 hours, did not reveal any significant residual EDH. During follow-up, none of the 8 patients developed a disfiguring sunken sub occipital scar. Even though patient in whom bone flap could not be replaced (C. No. 8) did not develop a disfiguring sunken sub occipital scar, he continued to experience suboccipital headache and discomfort. During this study, the average time taken in evacuation of the PFEDH by using a trephine sub occipital craniotomy was 40 minutes (range 30-55 minutes).

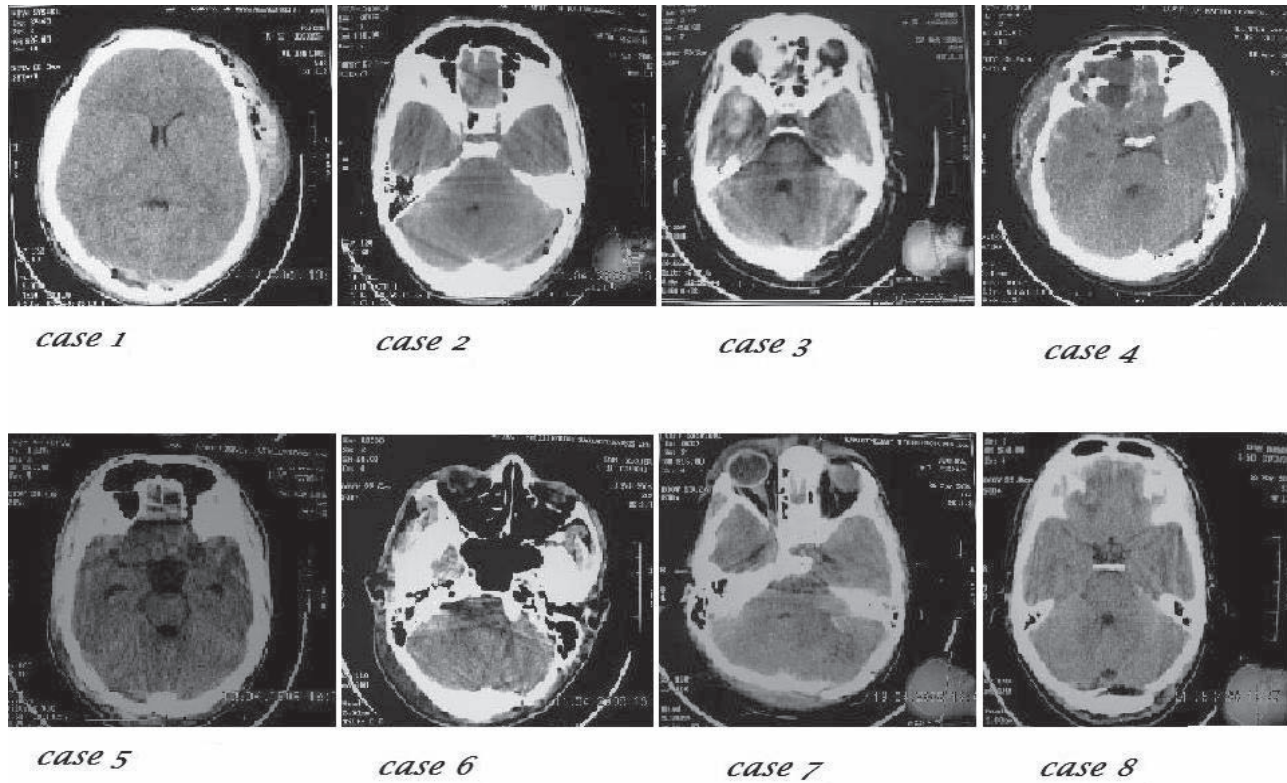


Fig 2: Post operative axial CT scan (representative posterior fossa cuts) of C. No. 1-8

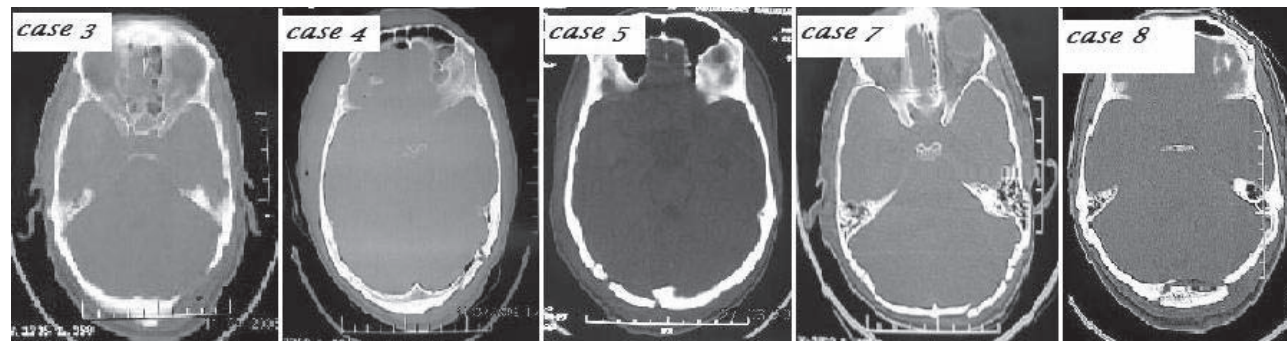


Fig 3: Post operative CT scans (bone window). Scans of C.No.1, 2 and 6 were not available.

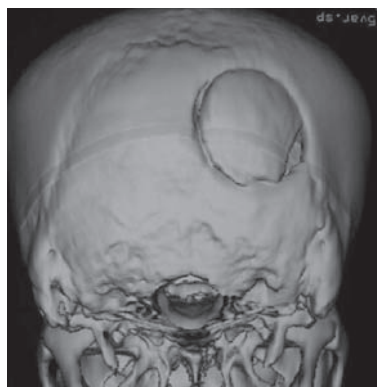


Fig 4: Post operative 3D CT scan of case 5

### DISCUSSION

Traditionally, surgical evacuation of posterior fossa epidural hematoma involves performing a craniectomy over the hematoma. A formal craniotomy using drill/burr holes & Gigli saw has also been advocated for evacuation of ‘pure’ (EDH confined to the infratentorial region) and ‘mixed’ (EDH extending to the supratentorial region) PFEDH<sup>6,7,8,9,10</sup>. However the use of a trephine (fig. 5) for making a craniotomy has not been previously described. The fear of iatrogenic damage to the dural venous sinuses is probably responsible for this. This fear is unfounded because an epidural hematoma inherently



Fig 5: Picture of a trephine craniotome.

pushes the dura and sinuses away from the bone thereby protecting it from injury when performing a properly placed trephine craniotomy. Patients of posterior fossa EDH are especially prone to rapid neurological deterioration<sup>2,9</sup>, and calculated speed during surgery is of paramount importance.

We used a trephine (50mm or 30mm) to perform an adequate craniotomy in all our cases. The craniotomy site was marked on the basis of CT scans. The procedure was easily accomplished and no perioperative difficulties were encountered. Moreover, in case of inadequate exposure, there is always an opportunity of extending the opening as required. The reduced operative time (30 – 55 minutes) and the simplicity of the procedure allow it to be easily and expeditiously performed. Even a 'pure' bilateral PFEDH (case 8) was removed using a trephine craniotomy. A definite bleeding source could be identified in only one of our cases, while diffuse oozing from the dural surface was present in almost all cases. Other sources of PFEDH may be diffuse venous oozing from the fracture line, posterior branch of the middle meningeal artery, dural branch of the vertebral artery and emissary veins<sup>7</sup>.

An important advantage of use of suboccipital trephine craniotomy over suboccipital craniectomy is the feasibility of applying central dural hitch sutures to avoid the possibility of reaccumulation of hematoma. Reported rate of recurrence of EDH or significant residual EDH requiring reoperation is 7.8%<sup>11</sup>. Replacing the bone flap also protects the posterior fossa contents from direct compression during the postoperative phase.

Another disadvantage of a craniectomy is the

theoretical possibility of a syndrome akin to the 'sinking skin flap syndrome'. Every cranial defect allows transmission of direct atmospheric pressure onto the intracranial contents, especially on the blood vessels<sup>12</sup>. The gradient between the intra cranial pressure and atmospheric pressure causes the inward displacement of the scalp over the cranial defect and the occurrence of a cosmetic/ neurological deficit is conceivable<sup>13</sup>. This mechanism of neurological deficit ('syndrome of trephined') has been described previously only after supra tentorial surgery. However avoiding an infra tentorial bone defect would leave no scope for occurrence of such a complication.

Two cases (No. 6 and 7) in our series had a poor outcome, with a Glasgow outcome scale of 3. Both of these cases had a poor GCS on admission, which has been considered the main factor leading to a poor outcome<sup>2</sup>. Occipital fracture in PFEDH occurs in 75% cases<sup>4</sup>. We encountered an occipital fracture in 6 of our 8 patients, which is consistent with reports in earlier studies<sup>9</sup>.

## CONCLUSION

Using a trephine for making a sub occipital craniotomy for evacuation of PFEDH is a feasible and safe option. In the context of the Indian subcontinent where most emergency surgery for head injured patients is done at centers where advanced facilities like motorized craniotomes and high power drills may usually not be available for fashioning suboccipital craniotomies, this technique can be easily adopted and used successfully in the surgical approach to posterior fossa extradural hematomas, especially by those surgeons who most often deal with traumatic intracranial hematomas. There is no added risk of venous sinus injury. Replacing the bone flap helps to restore the normal anatomy. Use of central and peripheral dural hitch sutures in patients of traumatic PFEDH is feasible and avoids any possible reaccumulation of hematoma.

## REFERENCES

1. Mahajan RK, Sharma BS, Khosla VK, et al. Posterior fossa extradural haematoma—experience of nineteen cases. *Ann Acad Med Singapore* 1993; 22(3 Suppl): 410-3.1
2. Wang E C M, Lim A Y T, Yeo T T. Traumatic Posterior Fossa Extradural Haematomas (PFEDH). *Singapore Medical Journal* 1998; 9(3):107-11.2
3. Garza-Mercado R. Extradural haematoma of the posterior cranial fossa: Report of seven cases with survival.

- J Neurosurg* 1983; 59: 664-72. 3
4. Holzschuh M, Schuknecht. Traumatic epidural haematomas of the posterior fossa: 20 new cases and a review of the literature since 1961.  
*Br J Neurosurg* 1989; 3(2): 171-80.4
  5. Pozzati E, Tognetti F, Cavallo M, Acciarri N. Extradural hematomas of the posterior cranial fossa: Observations on a series of 32 consecutive cases treated after the introduction of computed tomography scanning.  
*Surg Neurol* 1989; 32(4): 300-3.5
  6. Lui TN, Lee ST, Chang CN, Cheng WC. Epidural haematomas in the posterior cranial fossa.  
*J Trauma* 1993; 34(2): 211-5.
  7. Apuzzo M (ed). Brain Surgery: complication avoidance and management. Livingstone, NY, Churchill, 1993: 1947.7
  8. Schmidek HH, Sweet WH. Operative Neurosurgical Techniques: Indication, Methods and results. (3<sup>rd</sup> edition): pp 69 – 74. 8
  9. Taþkýn Yurtseven , Sertaç Ýplekel , Ender Tabur. Successfull management of adults traumatic posterior fossa haematomas with zero mortality.  
*Journal of Neurological Sciences (Turkish)* 2004 ; 21: 2. [Http://www.Med.Ege.Edu.Tr/Norolbil/2004/Nbd28504.Htm](http://www.Med.Ege.Edu.Tr/Norolbil/2004/Nbd28504.Htm). (Accessed 11.5.2006)9
  10. Berker M, Cataltepe O, Ozcan OE. Traumatic epidural haematoma of the posterior fossa in childhood: 16 new cases and a review of the literature.  
*Br J Neurosurg* 2003; 17(3):226-9.10
  11. Lobato RD, Rivas JJ, Cordobes F, Alted E, Perez C, Sarabia R. Acute epidural hematoma: an analysis of factors influencing the outcome of patients undergoing surgery in coma.  
*J Neurosurg* 1988; 68(1):48-57.
  12. Erdogan E, Düz B, Kocaoglu M, Izci Y, Sirin S, Timurkaynak E. The effect of cranioplasty on cerebral hemodynamics: Evaluation with transcranial doppler sonography.  
*Neurol India* 2003; 51: 479-81. 12
  13. Tabaddor K, LaMorgese J. Complication of a large cranial defect - Case report.  
*J Neurosurg* 1976; 44: 506-8. 13