

Delayed intraventricular hemorrhage with hydrocephalus following evacuation of post traumatic acute subdural hematoma

Raj Kumar M Ch, Samir Kumar Kalra M Ch, Rupant Kumar Das MS,
Vivek Kumar Vaid MS, Ashok Kumar Mahapatra M Ch
Department of Neurosurgery,
Sanjay Gandhi Postgraduate Institute of Medical Sciences,
Lucknow-226014, U.P

Abstract: The incidence of intraventricular hemorrhage (IVH) has been increasing recently due to increased detection. The occurrence following evacuation of an acute subdural hematoma (SDH) is extremely rare. The exact mechanism of traumatic IVH in these cases has not been well documented; the erosion of the ventricular wall by adjacent hematoma has been described as the most plausible cause. The rupture of unsuspected vascular malformation following head injury has also been suggested.

A case with a delayed IVH following evacuation of acute SDH is reported and the underlying pathophysiology is discussed. This entity needs to be recognized and kept in mind as a potential cause of post surgical deterioration in such patients.

Keywords: intraventricular hemorrhage, head injury

INTRODUCTION

The incidence of intraventricular hemorrhage has been progressively increasing over the years¹. This is primarily due to increased detection using current radiological modalities like Computerized Tomography (CT) as well as Magnetic Resonance Imaging (MRI)^{2,3} and partly by increased incidence of head injury. The traumatic intracranial hemorrhages are generally classified on the basis of anatomical location of bleed as subarachnoid, subdural, extradural and intracerebral; and on basis of time factor as acute, subacute, and chronic. Such distinction has useful diagnostic and prognostic significance. Acute subdural hematomas connote the hematomas within the potential subdural space and detected within 3 days of their occurrence. The most common cause is head trauma; however nontraumatic hematomas are also common¹. They are commonly associated with other intracranial lesions like another hematoma or fracture. The prognosis in such patients is

understandably poorer in comparison to those without any associated lesions.

Patients with head injuries who sustain sublethal intracranial damage normally tend to recover unless certain secondary complications set in. These complications often herald the perpetuation of the post traumatic sequel and are referred to as epiphenomena or the second accident^{2,4}.

The association of traumatic intraventricular hemorrhage with acute subdural hematoma is well described^{1,5,6,7,8,9}. Primary IVH is very rare. Occurrence of IVH following evacuation of an acute subdural hematoma is a distinctly rare¹⁰. We report an unusual case of delayed intraventricular hemorrhage following evacuation of acute subdural hematoma and discuss the pathogenetic mechanism of such an occurrence.

CASE REPORT

A 64-year-old-female sustained head injury after being hit on the head by a bull. She vomited repeatedly, and rapidly lost consciousness. There was no external scalp injury and after consultation from a local peripheral hospital she was referred to our institute for neurosurgical care within three hours of injury. Her blood pressure was 138/84 mm Hg and she was breathing spontaneously. An urgent CT scan was done at our hospital which revealed a large acute subdural hematoma in the right

Address for Correspondence:

Dr. Rajkumar, Professor
Department of Neurosurgery
Sanjay Gandhi Postgraduate Institute of Medical Sciences
Lucknow -226014, U.P. [INDIA]
Phone No.0522-2668700, 2668800 Ext. 2157(C), 2158(R),
2107(OT), 2741(O)
Fax No: 91(522)2668129 & 2668017
E mail: rajkumar@sgpgi.ac.in

frontotemporoparietal region with massive midline shift. The volumetric analysis showed a hematoma of 65-75 ml. There was associated frontal contusion, measuring 2.1 X 2 X 1.5 cm. There was no subarachnoid or intraventricular blood. There was no associated fracture (Figure 1). She had to be put on elective ventilatory support prior to surgery on account of her inability to maintain adequate oxygenation. Surgery was performed within five hours of her sustaining injury: a right frontotemporoparietal craniotomy was performed and hematoma evacuated. Continuous intraoperative monitoring of blood pressure, oxygen saturation and ECG were done. There were no significant intraoperative sequel and the hematoma was drained adequately.

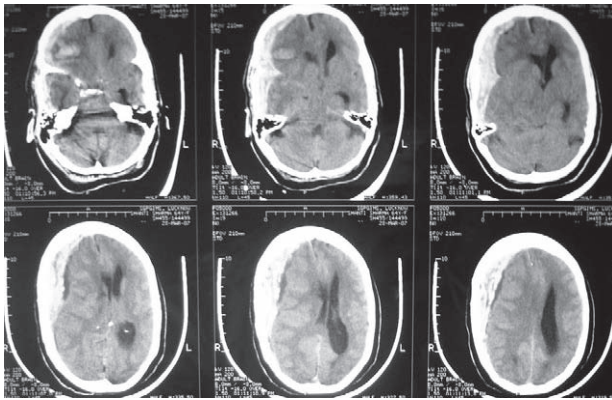


Fig 1: Non-contrast CT showing a large frontoparietal acute subdural hematoma with hemispheric mass effect and massive midline shift. There is associated right frontal contusion and no intraventricular blood.

Postoperatively she improved and was weaned off the ventilatory support. After 12 hours of injury, she was off ventilator and started opening eyes spontaneously and moving her limbs equally. Follow-up CT showed presence of blood in both lateral ventricles and ventricular enlargement as compared to the presurgical CT (Figure 2). An external ventricular drainage was inserted, with improvement in her neurological status. She became conscious and started following commands by day second postoperative day. The cerebrospinal fluid initially hemorrhagic, became clear, and removal of EVD was planned. However, after blocking the EVD she became drowsy, and CT showed increase in ventriculomegaly and intraventricular hemorrhage as well (Figure 3). Size of frontal contusion was however had reduced. Ventriculoperitoneal shunt was inserted on the third postoperative day. Recovery thereafter was uneventful, and at the time of discharge on twelfth postoperative day, she was conscious, followed commands and was

ambulatory with support. Frontal contusion and ventriculomegaly had resolved by tenth postoperative day (Figure 4).

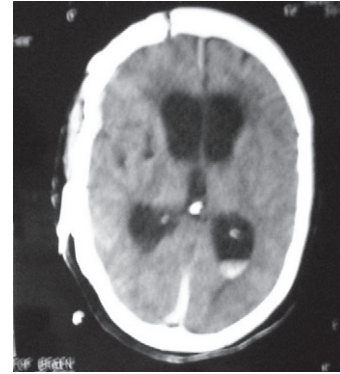


Fig 2: Non-contrast CT showing resolution of acute subdural hematoma and mass effect. There is increase in ventricular size with presence of intraventricular blood.

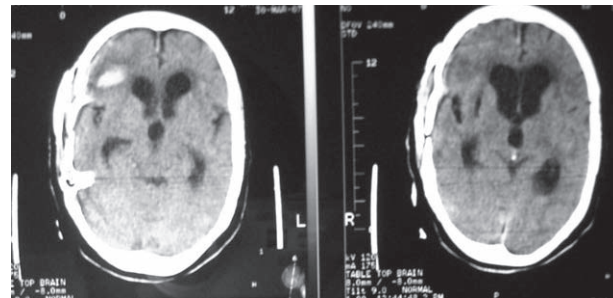


Fig 3: Repeat CT showing increased ventricular size and resolution of intraventricular blood following the blockade of external ventricular drain.

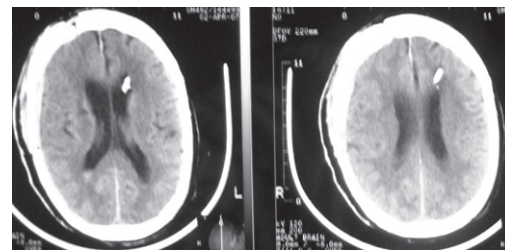


Fig 4: Follow-up CT showing resolution of ventricular size following an indwelling ventriculoperitoneal shunt.

DISCUSSION

The frequency of IVH following head trauma has been quantified over the years following the use of CT as a routine modality for diagnosis in head injured patients. The incidence of primary IVH following head injury is very less compared to secondary intraventricular bleeds. Most often the presence of IVH heralds poor prognosis for the patient^{8,11}. Hashimoto T et al¹¹ studied 329 cases

with head injury and found that 32% had primary intraventricular hemorrhage on initial CT scan. They concluded that anatomical structure of the fornix and septum pellucidum were weak points for shearing forces to act and produced IVH. There was a high incidence of associated traumatic lesions namely contusions of white matter and grey matter, brainstem lesions and cerebellar contusions caused by shearing injury.

The incidence of secondary IVH is relatively more common and various pathogenic mechanisms have been proposed¹. Piek and Bock described 9 cases of traumatic secondary IVH and reported 2 cases in whom IVH occurred after a lucid interval of 10 hours following injury¹². Sato et al concluded from their study of 19 patients of traumatic IVH that final outcome of such patients was mainly influenced by the severity of co-existing intracranial lesions¹³.

Most cases of traumatic IVH are associated with other CT abnormalities such as diffuse brain injury, hemorrhages in the corpus callosum, diffuse brain swelling and subarachnoid hemorrhage. There is usually an absence of focal and specific mass lesions in these^{2,3}.

The presence of intracranial hematoma is a common and potentially treatable cause of posttraumatic intracranial hypertension. Survival rate of victims sustaining a sublethal intracranial injury largely depends upon their timely recognition and treatment of intracranial hemorrhage. Acute subdural hematoma signifies blood in the potential subdural space and is an indicator of very severe underlying brain injury^{5,14,15}. The associated intraparenchymal contusions and IVH are well described in association. The exact mechanism of traumatic IVH in these cases has not been well documented. The erosion of the ventricular wall by the adjacent hematoma has been described by many as the most plausible cause^{1,5,6,7,8}.

The rupture of unsuspected vascular malformation following head injury has also been suggested^{2,6}. This however is controversial since the incidence of traumatic IVH is significantly higher than that of arteriovenous malformations.

Tsai and Huprich⁷ observed irregular contrast enhancement of ventricular margins and concluded that damaged subependymal vessels through which the contrast leaked was primarily responsible for IVH. The incidence of IVH in association with head injury is presented as Table 1.

Table 1: Literature review of traumatic intraventricular hemorrhage

Author	Total head injury	IVH	Associated lesions
Merino-de Villasante & Taveras ⁶	100	3	2
Tsai et al ⁷	210	17	11
Zuccarello et al ⁸	350	10	8
Atzema et al ¹	8374	118	-

Abbreviations: CT computed tomography, EVD external ventricular drainage, IVH intraventricular hemorrhage, MRI magnetic resonance imaging

In the case report by Kojima et al¹⁰, there was a similar development of IVH following evacuation of acute subdural hematoma. They proposed the shearing strain injury which might have damaged the subependymal structures containing the subependymal veins. The presence of acute SDH and consequent brain edema might have caused increased intracranial pressure and stasis in these veins and thus prevented IVH. Consequent to the decompression of the hematoma and resultant ventricular dilatation, the subependymal veins may have ruptured producing IVH. This seems to be the plausible explanation in our case as well as since the hematoma was in the subdural space and the frontal contusion was far away from the ventricular cavity. There was no radiological evidence of subarachnoid hemorrhage as well. The IVH was not documented in the CT scan prior to surgery and was demonstrated following evacuation of the acute SDH.

This has also been suggested by Zucarello et al⁸ and Borovich et al¹⁶ and the latter noted development of extradural hematoma within 24 hours of evacuation of the previous subdural hematoma or extradural hematoma. This was explained to be due to disturbances in the brain equilibrium and haemostatic effects of intracranial pressure, intracranial hypoperfusion and rapid recovery from peripheral vascular collapse could likewise contribute to delayed IVH.

CONCLUSIONS

To conclude the occurrence of delayed IVH following evacuation of SDH is a rare entity. The most common cause is due to rupture of subependymal veins following evacuation and hence release of the tamponade effect of acute SDH. This entity needs to be recognized and kept in mind as a potential cause of post surgical deterioration in such patients.

REFERENCES

1. Cordobes F, de la Fuente M, Lobato RD et al. Intraventricular

- hemorrhage in severe head injury.
J Neurosurg. 1983; 58:217-22.
2. Danziger A, Price H. The evaluation of head trauma by computed tomography.
J Trauma 1979;19: 1-5.
 3. Dublin AB, French BN, Rennick JM. Computed tomography in head trauma.
Radiology 1977; 122: 365 -9.
 4. Atzema C, Mower WR, Hoffman JR, Holmes JF, Killian AJ, Wolfson AB. National Emergency X-Radiography Utilization Study (NEXUS) II Group Prevalence and prognosis of traumatic intraventricular hemorrhage in patients with blunt head trauma.
J Trauma 2006; 60:1010-72.
 5. French BN, Dublin AB. The value of computerized tomography in the management of 1,000 consecutive head injuries.
Surg Neurol 1977; 7: 171-83.
 6. Merino-de Villasante J, Taveras JM. Computerized tomography in acute head trauma.
Am J Roentgenol 1976;126: 765-78.
 7. Tsai FY, Huprich JE. Further experience with contrast enhanced CT in head trauma.
Neuroradiology 1978;16: 314-7.
 8. Zuccarello M, Iavicoli R, Pardatscher K et al. Posttraumatic intraventricular haemorrhages.
Acta Neurochir (Wien) 1981; 55:283-93.
 9. Zimmerman RA, Bilaniuk LT, Gennarelli T. Computed tomography of shearing injuries of cerebral white matter.
Radiology 1978; 127: 393-6.
 10. Kojima N, Tamaki N, Matsumoto S, Fujiwara M. Delayed onset of intraventricular hemorrhage following removal of acute subdural hematoma
Neurol Med Chir (Tokyo) 1991; 31:165-8.
 11. Hashimoto T, Nakamura N, Ke R, Ra F. Traumatic intraventricular hemorrhage in severe head injury.
No Shinkei Geka 1992; 20:209-15.
 12. Piek J, Bock WJ. Secondary intraventricular haemorrhage in blunt head trauma.
Acta Neurochir (Wien) 1986; 83:105-7.
 13. Sato M, Tanaka S, Kohama A, Fujii C. Traumatic intraventricular haemorrhage.
Acta Neurochir (Wien) 1987; 88:95-103.
 14. Fleischer AS, Huhn SL, Meislin H. Post-traumatic acute obstructive hydrocephalus.
Ann Emerg Med 1988; 17:165-7.
 15. Karavelis A, Sirnos C. Primary post-traumatic intraventricular hemorrhage.
J Neurosurg Sci 1995;39:253-6.
 16. Borovich B, Braun J, Guilburd JN et al. Delayed onset of traumatic extradural hematoma.
J Neurosurg 1985;63: 30-34.