

Midline depressed fracture involving a venous sinus

Aliasgar V Moiyadi M Ch, B Indira Devi M Ch, K V R Sastry M Ch

Department of Neurosurgery,
National Institute of Mental Health and Neurosciences,
Bangalore 560029

Simple depressed fractures involving the midline superior sagittal sinus are usually treated conservatively unless accompanied by focal deficits^{1,2}. Our patient, a 4-year-old child, presented with asymmetric paraparesis associated with a midline simple depressed fracture overlying the middle third of the superior sagittal sinus. Hence it was elevated with improvement in the deficits, preservation of sinus patency, and acceptable cosmetic result.

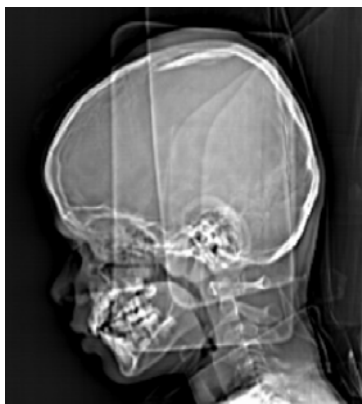

FIGURE 1 : Topogram showing midline depressed fracture overlying the middle third of superior sagittal sinus.

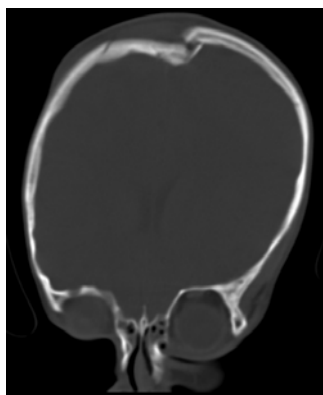


FIGURE 2 : Coronal view of CT scan (bone window) showing the depressed fragment crossing the midline.

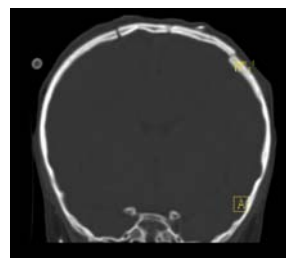


FIGURE 3 : Postoperative CT scan coronal slice showing realignment of the fracture fragments.

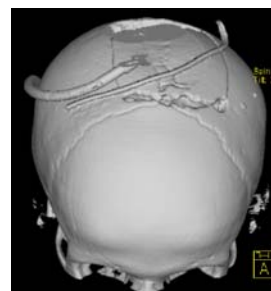


FIGURE 4 : Postoperative shaded surface display (SSD) reconstruction of the skull, showing the craniotomy around the depressed fragment.

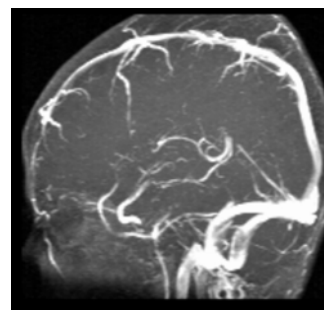


FIGURE 5 : Postoperative magnetic resonance venogram showing patency of the superior sagittal sinus.

REFERENCES

1. Steinbok P, Flodmark O, Martens D, Germann ET. Management of simple depressed fractures in children. *J Neurosurg* 1987; 66: 506-10.
2. LeFeuvre D, Taylor A, Peter JC. Compound depressed fractures involving a venous sinus. *Surg Neurol* 2004; 62: 121-6.

Address for correspondence : Dr.B Indira Devi, Department of Neurosurgery, National Institute of Mental Health and Neurosciences, Bangalore 560029, India.
Phone: 91-080-6995409/5403, Fax: 91-080-6564830
Email : bindira@nimhans.kar.nic.in