

Post head injury hydrocephalus

Harjinder Singh Bhatoe M Ch, Varinder Kumar Batish M Ch

Departments of Neurosurgery
Army Hospital (R & R), Delhi Cantt 110010 &
Command Hospital (WC) Chandimandir

Abstract: Hydrocephalus is one of the treatable sequelae of head injury. Onset of hydrocephalus is indicated by plateauing of recovery, or by neurological deterioration. Etiology can be linked to subarachnoid hemorrhage or infection. Ventriculoperitoneal shunting provides immediate improvement and long-term relief.

Keywords : head injury, hydrocephalus

INTRODUCTION

The wide spectrum of post-traumatic sequelae presented by the victim of craniocerebral injury is impressive, and ranges from a comatose, purely vegetative akinetic mutism to neurological syndromes of varying severity and mild personality disorders. The main organic cause of disability after a head injury is disturbance of mental capacity. This disturbance may occur at various levels of mental activity and may range from affection of well established skills such as speech, reading, calculating and orientation, to disturbances of higher capacities such as memory, abstract thinking and reasoning.

The recognition of hydrocephalus developing after head injury is often clouded by attributing the unresolved or added symptoms to the original trauma or to the operation thereof. They may be passed off as a result of cerebral edema, ischemia, infection, hypoxia or other factors complicating head injury. The awareness of hydrocephalus acquired as a consequence of head injury lags behind these explanations for neurological plateauing or deterioration. Identification of this process may lead to institution of shunting procedures that may dramatically reverse an otherwise dismal predicament. However, failure to identify hydrocephalus is not uncommon and this is especially true when the surgeon has adopted a fatalistic acceptance of an unfortunate outcome.

MATERIAL AND METHODS

We managed twenty five patients with post-head-injury hydrocephalus (PHIH) over the past fourteen years in three different service hospitals. There were twenty four

males and one female. The youngest patient was a boy aged 12 years, while the eldest was a 65-year-old woman (Table 1). Twenty patients sustained closed head injury, while five sustained craniocerebral missile injury (CMI). In the closed head injury cases, the initial injury was severe (Glasgow Coma Score 8 or below) in 15, and mild in five. CT findings at the time of initial injury in these 20 cases were:

Diffuse edema	:	7
Cerebral contusion	:	6
Subarachnoid hemorrhage	:	3
Normal scan	:	4

Table 1. PHIH: Age distribution

Age Group (years)	Number
10 – 20	2
21 – 30	4
31 – 40	8
41 – 50	7
51 – 60	3
More than 60	1

Five patients with cerebral contusion were operated upon. Fifteen patients were managed conservatively with cerebral decongestants, oxygenation, etc., and were closely observed for any possible deterioration. Only one of the five patients with CMI underwent exploration and debridement; rest were treated with antibiotics and cerebral decongestants in the acute phase.

Presentation (Table 2): Earliest detection of hydrocephalus was in a patient with bilateral supratentorial hematomas, who was in vegetative state seven days after the injury. Majority of the patients were detected to be having PHIH within three months of the initial injury. Two of the patients with CMI developed recurrent bouts of meningitis, and one of them developed PHIH nearly eight

Address for correspondence: Harjinder Singh Bhatoe M Ch
Department of Neurosurgery, Army Hospital (Research & Referral)
Delhi Cantt. 110010, New Delhi, E-mail: hsbhatoe@indiatimes.com
Tel: 91-11-28638095, 28638096, Fax: 91-11-25681893,

years later. Most of the patients had features of normal pressure hydrocephalus in the form of dementia, gait apraxia, altered behaviour, etc. Six patients were persistently vegetative.

Table 2. PHIH: Presentation

Group	Number
Persistently vegetative	6
Varying degree of obtundation	10
Cognitive dysfunction & dementia	9

Imaging: All patients were evaluated by CT scan. The findings were:

Dilatation of ventricles, periventricular lucencies: in all 25

Obliteration of basal cisterns and subarachnoid spaces : in 15

Widening of subarachnoid spaces : in 5

Management : Twenty four patients underwent ventriculoperitoneal shunt. One patient with acute PHIH was given hyperventilation for 48 hours.

Table 3. Time interval

Time interval	Number
7 days	1
Upto 4 weeks	10
1 – 3 months	9
3 – 12 months	4
> 12 months	1

RESULTS

The final outcome is given in Table 4. All patients showed improvement after surgery. Patient treated with hyperventilation also showed recovery and could be discharged two weeks later.

Table 4. PHIH: outcome

	Asymptomatic	Independent	Improved	Total
Persistently vegetative	2	2	2	6
Obtundation	4	3	3	10
Cognitive deficits	4	3	2	9
Total	10	8	7	25

DISCUSSION

PHIH is not reported very often in literature. Kishor et al¹ reported its incidence to be up to 15% among all patients with severe head injury. According to Zander & Foroglou², about 10% of patients in large series of head injured with prolonged coma develop some degree of hydrocephalus. Baltas et al³ reported their experiences with 15 such patients

out of 860 patients with moderate and severe head injury (1.74%); two of these had received intrathecal amikacin for post-traumatic meningitis. Bhatoe & Mukherji⁴ reported PHIH following CMI. PHIH may develop acutely, especially in the presence of subarachnoid hemorrhage. There may be aseptic inflammation of the meninges leading to occlusion of basal cisterns. Similarly, meningitis following head injury can lead to communicating hydrocephalus. Hydrocephalus may be seen acutely in the presence of intracerebral hematoma causing obstruction to CSF flow by mass effect. Communicating hydrocephalus with rapidly enlarging ventricles may develop within hours of severe head injury⁵.

Typically, however, PHIH develops in the post-acute phase of head injury, weeks or months later. Characteristic Symptoms consist of dementia, apraxia, motor disturbances, urinary incontinence, cognitive dysfunction, etc. Motor disturbances are primarily of gait. Often the patients who following head injury, may be improving slowly in terms of state of consciousness, stop improving and take a turn for the worse, again become drowsy, lethargic or comatose with evidence of increasing intracranial pressure.

Development of PHIH is presumed to be due to subarachnoid hemorrhage². Subarachnoid spaces in patients dying after head injury and hydrocephalus are obliterated with fibrosis; ependymal destruction and presence of subependymal gliosis together with loss of white matter especially around the ventricles are other prominent findings. Experimental studies have shown that there is an increase in the outflow resistance and CSF pressure in rats following subarachnoid infusion of plasma or whole blood, and this is due to decrease in transport of fluid across the epithelium of arachnoid villi⁶. However, direct evidence of obstruction to CSF pathways in man is sparse. In patients dying soon after subarachnoid hemorrhage, RBCs but little fibrin are seen in the drainage channel within arachnoid granulations⁷. To what extent fibrosis and obliteration of the subarachnoid granulations⁸ or that of the subarachnoid space are contributory factors in the late onset of PHIH following subarachnoid hemorrhage is unknown⁹.

Management

Diagnosis of PHIH is made by CT or MRI in patients with appropriate clinical profile. CSF diversion by ventriculoperitoneal shunting is simple, cheap and effective therapeutic option. Following the shunting procedure, conscious patients no longer complain of headaches; there is improvement in cognitive functions. Some show rapid and complete regression of cognitive impairment, while

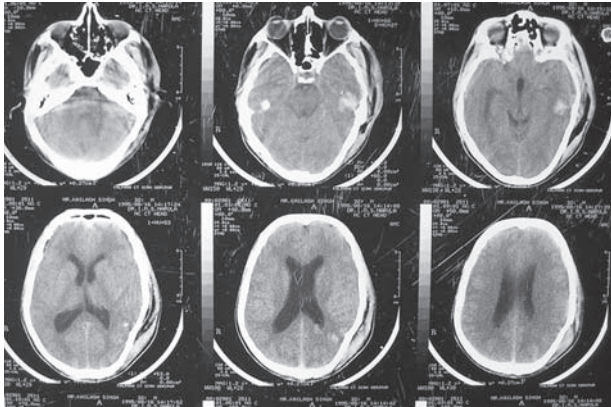


FIGURE 1 : CT showing left temporal contusion

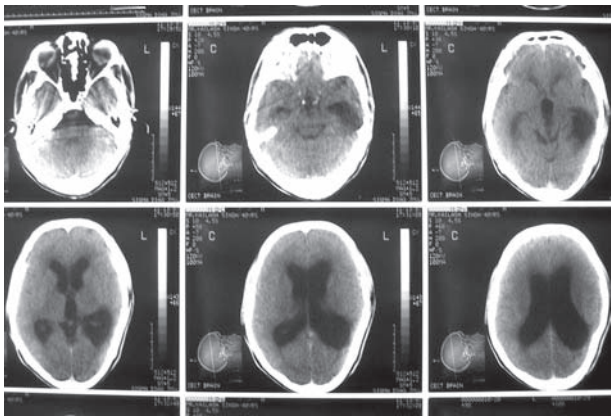


FIGURE 2 : CT in the same patient six weeks later showing hydrocephalus

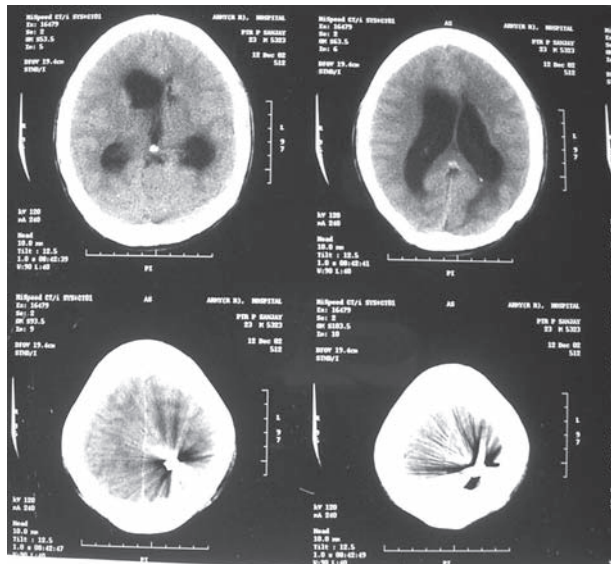


FIGURE 3 : CT showing retained intracranial shrapnel and hydrocephalus

others show slow improvement over a period of weeks or months. Some patients have returned to their previous occupations. Such success have encouraged us to continue our efforts to treat even patients who have been in prolonged coma, no matter how uncompromising the task appears.

REFERENCES

1. Kishor PRS, Lipper MH, Miller JD, Girevendulis AK, Becker DP, Vines FS. Post-traumatic hydrocephalus in patients with severe head injury. *Neuroradiology* 1978; 16:261-5.
2. Zander E, Foroglou G. Post head injury hydrocephalus. In, Vinken PJ, Bruyn GW (Eds). *Handbook of Clinical Neurology* Vol 26. North Holland Publishing Co., Amsterdam 1976: 231-53.
3. Baltas I, Tsouslfa S, Sakellariou P, Vogas V, Fylaktakin M, Kondodimou A. Post-traumatic meningitis: Bacteriology, hydrocephalus and outcome. *Neurosurgery* 1994; 35: 422-7.
4. Bhatoe HS, Mukherji JD. Hydrocephalus following missile injuries to the brain. Etiology and management. *International Reviews of Armed Forces Medical Services* 2004; 77:149-52.
5. Takagi H, Tamaki Y, Morii S, Ohwada T. Rapid enlargement of ventricles within seven hours after head injury. *Surg Neurol* 1981; 16:103-5.
6. Butler AB, Maffeo CJ, Johnson RN, Bass NH. Alteration of CSF outflow in acute subarachnoid hemorrhage; effect of blood components on outflow resistance and vascular transport of CSF in arachnoid villus endothelium. In, Cervos-Navarro J, Fritschka E (eds). *Cerebral Microcirculation and Metabolism*. Raven Press, New York 1981:409-14.
7. Upton M, Weller RO. The morphology of human arachnoid granulations. *J Neurosurg* 1985; 63:867-75.
8. Lorenzo AV, Bresnan MJ, Barlow CF. Cerebrospinal fluid absorption deficit in normal pressure hydrocephalus. *Arch Neurol* 1974; 30:387-93.
9. DiRocco C, DiTripani G, Maira G, Bentivoglio M, Macchi G, Rossi GF. Anatomico-clinical correlation of normotensive hydrocephalus. *J Neurol Sci* 1977; 33:437-52.

This document was downloaded for personal use only. Unauthorized distribution is strictly prohibited.