

Management of post traumatic cranio vertebral junction instability

Manas Kumar Panigrahi M Ch, FACS, **Beeram Vamsee Mohan** M Ch,
A K Purohit, M S, M Ch.

Department Of Neurosurgery, Nizam's Institute of Medical Sciences, Hyderabad.

Abstract: The occipito-atlanto-axial complex is a transition zone between vertebral joint structures and the skull. It is unique in that it allows extensive motion and yet its vertebrae are inter-locked to form an amazingly stable structure. Trauma in this region constitutes to above 25-30% cervical spine injuries. In a retrospective review of 490 cervical spine fractures during a 9-year period, we found 91 fractures involving cranio vertebral junction. Of the 91 patients, 54 had odontoid fractures, 22 had Hangman's fractures, 9 had miscellaneous fractures of C2, 5 had isolated C1 fractures and 1 patient presented with occipito atlantal dislocation. Age, sex, presence of associated injuries, neurological status at admission, treatment, and results of the treatment characterized each case. Excluding two patients who died within the first month of injury and two patients who went against medical advice, follow up data is available for 85 of 91 patients. Two patients were lost to follow up. In all 85 out of 91 patients followed for a median duration of 3.8 years ranging from one week to 8 years. Cranio Vertebral junction trauma constituted about 18.5% of total cervical spinal injuries admitted during this period.

Neurological compromise in cranio vertebral junction trauma was noted to be 40.6% in our series. The patients with isolated atlas fractures, stable type I and type III odontoid fractures, hangman's fractures and miscellaneous fractures do well with non operative management.

For type II odontoid fractures because of the high nonunion rates associated with non operative treatment, we recommend surgical management with direct anterior odontoid screw fixation within 6 months of injury, and Posterior transarticular screw fixation for fractures after 6 months of injury.

The overall patient satisfaction for daily survival was better with surgery and collar as compared to halo.

Keywords: - Atlas fracture, Axis fracture, CV junction, Halo stabilization, Hangman's fracture, Odontoid fracture

INTRODUCTION

The occipito atlanto axial complex is a transition zone between vertebral joint structures and the skull. It is unique in that it allows extensive motion and yet its vertebrae are inter-locked to form an amazingly stable structure. Trauma in this region constitutes to above 25-30% cervical spine injuries. It is estimated that 25-40% of patients with cranio vertebral junction trauma die at the scene of the accident. However neurological morbidity tends to be low in survivors¹. The rationale for our study is that there is insufficient evidence to formulate treatment standards in managing post-traumatic cranio vertebral junction instability^{2,3}. In this review we are presenting retrospective analysis of cranio vertebral junction trauma managed at

our institute from Jan 1996 to April 2005. Till date there is no published case series on this subject from India.

MATERIAL & METHODS

Four hundred and ninety patients with cervical spinal injury were evaluated at Nizam's Institute of Medical Sciences between Jan 1996 to April 2005. Of these, ninety-one patients had sustained cranio vertebral junction trauma. The medical records and imaging of these ninety-one patients were reviewed in detail. Excluding two patients who died within the first month of injury and two patients who went against medical advice, follow up data is available for 85 of 91 patients. Two patients lost to follow up. Follow up consisted of re-examination of patients, evaluation of physician's out patient registers. In all 85 out of 91 patients followed for a median duration of 3.8 years ranging from one week to 8 years.

Address for correspondence : Dr. Manas Kumar Panigrahi
Addl. Prof., Department of Neurosurgery, Nizam's Institute of
Medical Sciences, Panjagutta, Hyderabad, A.P., India
Phone no. 91-40- 56602588, Fax: 0091-40-23310076
Email: manaspanigrahi@hotmail.com

RESULTS

Overview

Of the 91 patients with CV junction trauma treated at this institute during the last nine and half years, 54 were odontoid fractures, 22 were Hangman's fractures, 9 were miscellaneous fractures of C2, 5 were isolated C1 fractures and 1 patient presented with occipito atlantal dislocation. There were 82 male and 9 female patients. Neurological compromise in crani vertebral junction trauma was noted to be 40.6% in our series.

Occipito Atlantal Dislocation

Sixty year old female patient injured in a road traffic accident presented with severe neck pain without deficit. Imaging revealed anterior occipito atlantal dislocation. Patient was put on Philadelphia collar prior to surgery followed by occiput to C2 fusion using plates and screws and onlay rib graft. The patient was doing well without deficit at the last follow up four years later.

Isolated C1 Fractures

In our series 5 patients had isolated C1 fractures and another 15 patients with C1 fractures had associated C2 fractures. According to the classification proposed by Landells and Van Peteghem⁴, 12 patients had posterior arch fracture (Type I), 5 patients had Jefferson fracture (Type II) and 3 patients had lateral mass fractures (Type III). Out of 5 isolated C1 fractures, 2 Type II fractures were managed with Halo and the rest of the 3 patients with collar.

All patients were doing well at the last follow up.

Type I Odontoid Fractures

Three patients were there in this group. Road traffic accident was the cause of injury in all. One patient presented with neurological deficit. MRI of this patient revealed contusion of spinal cord at CV junction with transverse atlantal ligament tear. One patient was managed with Philadelphia collar and the other two patients underwent occipital cervical fusion. Patients having transverse ligament tear were managed with occipito cervical fusion.

Type II Odontoid Fractures

Thirty eight patients were managed in this group. There were 34 males and 4 females. 30 patients were below 50 years of age, 8 were above 50 years of age. Twenty four patients had Atlanto Axial Dislocation (AAD) out of which 21 were anterior and 3 were posterior. Neurological deficit was noted in 47% of patients, most of them were in ASIAC

and D groups. Table I gives the details of neurological status at admission. Table II gives the analysis of management and complications.

Table 1. Type II Odontoid Fractures

Neurological Status at Admission	ASIA Scale	No Of Patients(%)
	A	0(0)
	B	1(2.6)
	C	11(28.9)
	D	6(15.8)
	E (No Deficit)	20(52.6)
Total No Of Patients		38

Table 2. Type II Odontoid Fractures – Management and Complications

Type	No Of Patients(%)	Neurological Deterioration Num % of total patients	Wound/Implant Related Num % of total patients	Non-union Number%
Surgery	30 (78.9)	4 (10.5 %)	5 (13.2%)	4 (13%)
Anterior	12(31.6)	1	2	
Odontoid Screw	10			
C1 - C3 Plating	2			
Posterior	18(47.3)	3	3	
C1 - C2 Wiring & Plating	14			
C1 -C2 Trans-articular Screws (Figure 3)	3			
Halifax (Figure 3)	1			
Conservative	8(21.1)	0 (0 %)	0 (0%)	2 (25%)
Halo	4	0	0	
Collar	4	0	0	
Total No Of Patients	38	4	5	

A total of 30 patients were operated, anterior surgery was done in 12 cases, in 10 cases transodontoid screw was placed and in 2 patients C1- C3 plating. Transoral plating was done in one case. This patient deteriorated postoperatively and had cardiac arrest. After reviving, he was taken away against medical advice. Deterioration is probably due to infection.

Total of 18 patients underwent posterior surgery. C1-C2 wiring performed in 14 cases.

C1-C2 transarticular screw placement was done in 3 cases and in one case, Halifax clamp fixation was done.

Fresh neurological deficits developed in 3 out of 14 patients managed with C1-C2 sublaminar wiring. The deterioration can be attributed to sublaminar wiring, as one reason and other was instability noted in 2 out of 3 patients on post op X-rays before and after traction, suggesting that stability in that region cannot be achieved totally with wire technique. One patient underwent further anterior

plating and other halo fixation. There was neurological improvement till the time of discharge. Based on above finding we consider that posterior transarticular screw or lateral mass plating would be safer.

Mean duration of time gap between injury and trans-odontoid screw placement was 45 days. All patients underwent trans-odontoid screw placement within 6 months from the date of trauma (Figure 1).

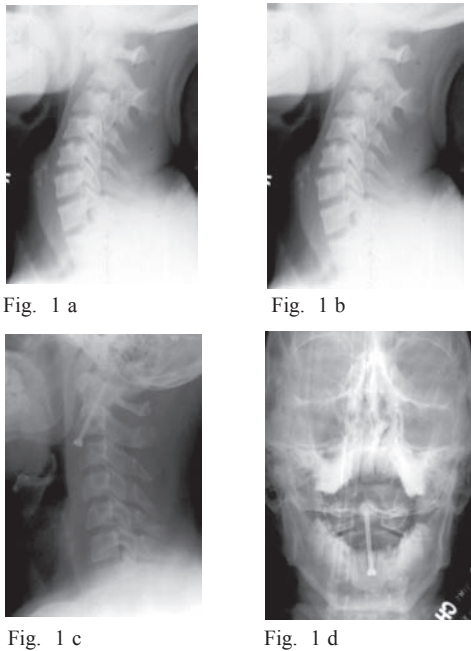


FIGURE 1: Type II odontoid fracture in (a) lateral and (b) transoral views. (c) and (d) reveal ideal placement of transodontoid screw in lateral and transoral views respectively.

Eight patients were managed conservatively. Four of these were managed with cervical collar. These included an elderly man 80 years old with poor respiratory reserve, and one patient with impacted type II fracture. Two cases had refused other modes of treatment.

Four patients were managed with halo as reduction of fracture segment was achieved with skull traction and as there was no cord compression. Cumulative complication rate was noted to be 23%.

X-Ray was the main modality of imaging performed in all patients. Surgical complication were noted in postoperative X-rays in 4 patients. Two patients each belonged to anterior and posterior surgery groups. All 4 of these underwent redo surgery. Follow up X-Rays were satisfactory for 33 patients. CT scan (Figure 2) was performed in 30 patients and post procedure in 7 patients. A total of 20 patients underwent MR imaging of which cord injury was present in 15 patients.

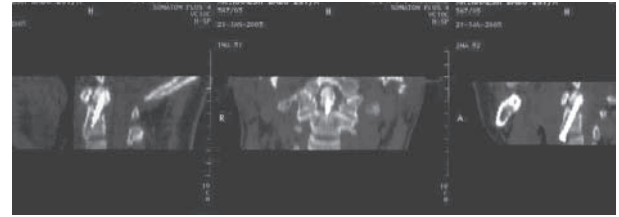


FIGURE 2: 2D reconstructed CT images of Type II odontoid fracture, managed with Anterior odontoid screw placement.

Twenty seven of the thirty patients operated were followed up. Thirteen patients had improved neurologically and equal number remained status quo. Six patients of the eight patients managed conservatively were followed up. One patient died in the operative group and two patients were discharged on request as they had poor respiratory reserve.

Non-union of fracture was noted in 18% of total patients. Non-union occurred in 13% of operated patients all of them had Implant failure post operatively. Non-union was noted in 25% of patients who were managed conservatively with halo and collar.

Patient satisfaction in terms of neck movement at follow up was in 40% of the patients. The patients managed with anterior odontoid screw and Halo was found to have satisfactory neck movements.

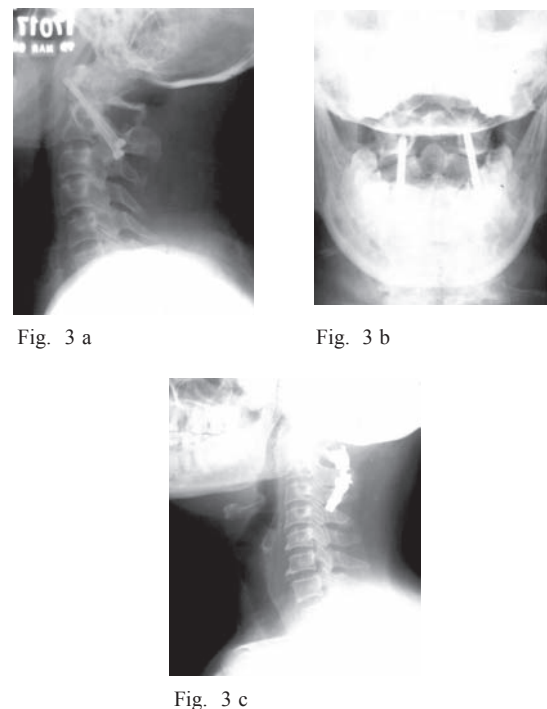


FIGURE 3: Preferred methods of posterior fusion. (a) and (b) reveal transarticular screws placed in a case of old type II odontoid fracture in lateral and transoral views respectively. Hali fax clamp fixation noted in (c).

Type III Odontoid Fractures

We have managed 13 patients with Type III fracture and 61.5% of them had no neurological deficits. Eight patients (61.5%) were managed conservatively. Halo was placed in four patients and Philadelphia collar in other four patients. Five patients were operated, among them four patients underwent C1-C2 fusion (C1-C2 sublaminar wiring in two, Transarticular screw fixation in one and C1-C2 plate and screw fixation in one patient) and 1 patient underwent anterior C1-C3 plating.

No surgical complications occurred. All five patients with deficit improved during follow-up. Non-fusion was noted in 1 out of 13 cases. Fusion achieved with surgery in all five patients (Figure 4).

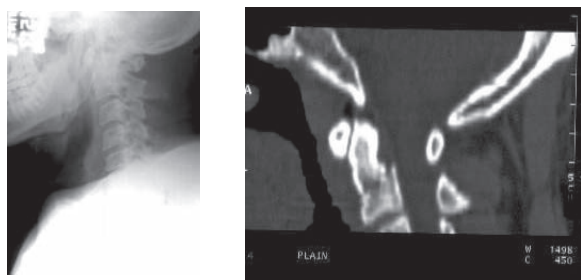


Fig 4 a

Fig 4 b

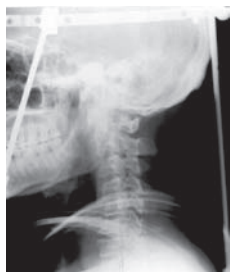

Fig 4 c

FIGURE 4: Type III odontoid fracture seen in (a) x-ray lateral projection (b) CT reconstructed sagittal view. Fracture stabilized with halo fixation (c).

Hangman's Fractures (Figure 5)

A total of 22 patients with mean age of 35 years were reported in this group. Nine of these patients had neurological deficit. Surgery was performed in 15 patients. Anterior plating in 12 patients and posterior C1–C2 fixation in two and occiput to C2 fixation in one patient. One patient who underwent sublaminar wiring developed fresh neurological deficit. One patient had a wound hematoma for that re exploration was done. Seven patients were managed conservatively, four with Halo and three with collar.

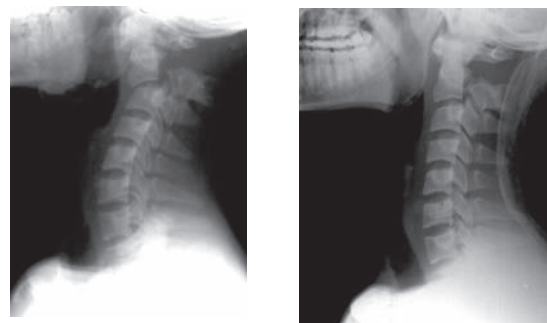


Fig 5 a

Fig 5 b

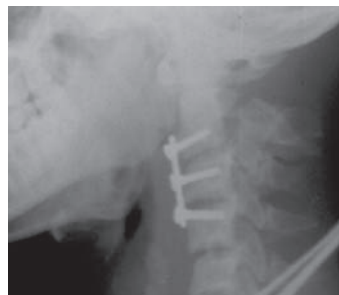

Fig 5 c

FIGURE 5: Hangman's fracture II A (a) pretraction view (b) post traction view and Anterior cervical plating from C2-C4 noted in (c).

Table 3. Hangman's Fracture (Mean Age - 35)

Levine and Edwards ⁴⁷ Classification of Hangman Fracture	Type	No Of Patients	%
	Type I	5	22.7
	Type II	11	50.0
	Type II A	3	13.6
	Type III	3	13.6
	Total No Of Patients	22	100

Total operative complications were 9% (Table IV).

One out of 13 patients had neurological deterioration at discharge but improved during the follow up period. Post-operative X-Rays of 12 patients revealed good fusion.

Table 4. Hangman's Fractures - Operative Complications

Type	Neurological Deterioration	Wound Implant Related
	Num % of total patients	Num% of total patients
Surgery	1 (4.5%)	1 (4.5%)
Anterior (12)	0	1
Posterior (3)	1	0
Conservative	0 (0%)	0 (0%)
Halo (4)	0	0
Collar (3)	0	0
Total Complications	1	1

Associated injuries

Most common associated injury with cranio vertebral junction trauma was long bone fractures (15.4%) followed by head injury (11%).

Miscellaneous Fractures

Miscellaneous Fractures of C2 are non-odontoid non-Hangman's fractures. This group consists of C2 body, facets, lateral mass, lamina and spine fractures, displaced or undisplaced, with or without instability.

A total of nine male patients had miscellaneous fractures out of which four of them had neurological deficit. One patient died during admission. One patient was managed with surgery, three patients with Halo and four patients with collar. Outcome in eight of these patients was good. Table V gives the analysis of combined Odontoid, Hangman's and miscellaneous fractures.

Table 5 - Analysis of Axis Fractures

Type	# of Patients	% Of Deficit	Anterior	Posterior	Halo	Collar	Complications	Outcome
Type I	3	33.3 (1)	0	2	1	0	NIL	Improved
Type II	38	47.4 (18)	12	18	4	4	4 - Neurological 5- Implant Related	1 - Death 2 - LAMA 15-Improved 17-status quo
Type III	13	41.7 (5)	1	4	4	4	NIL	Good
Hangman's	22	40.9 (9)	12	3	4	3	1 - Neurological 1 - Wound Related	1 - Deteriorated 21-Improved
Miscellaneous	9	44.4 (4)	1	0	3	4	NIL	1-Death immediately after admission
Total	85		26	27	16	15	12.9%	

Mortality

Two deaths occurred in 91 patients admitted. One patient died with septicemia and the other due to respiratory failure.

DISCUSSION

Overview

We have studied data of 91 patients with CV junction trauma among 490 cervical spine injuries in a retrospective review of admissions between Jan 1996 to April 2005. Craniovertebral junction trauma constituted about 18.5% of total cervical spinal injuries admitted during this period. Review of literature revealed that the trauma related to CV

junction is common and contribute to approximately 25% of all cervical spine injuries (Atlanto Occipital Dislocation (AOD) - 1%⁵⁻⁷, atlas fractures 5-10%⁷⁻¹², fractures to Axis 15-20%¹³⁻¹⁵. Half of C1 fractures are associated with fracture of axis^{4,9,16,17}. In this study we found that the commonest type of fracture was fracture axis (17.3%) followed by C1 fracture (4%, two thirds of which were associated with axis fractures) and AOD (0.2%) of total cervical spinal injuries at our institute. Compared to earlier studies, recent studies reveal increased incidence of CV junction trauma because of new diagnostic skills and radiographic techniques.

The male preponderance (10:1), median age (34 years) and mechanisms of injury (motor vehicles accidents 72%) were consistent with those reported by previous authors¹⁸⁻²³.

Neurological compromise from cranio vertebral trauma was noted to be 40.6% in our series where as in reported literature it was mentioned as 5-10%¹⁸⁻²³. The reason for this discrepancy is referral pattern which means only those with neurological deficits tend to get referred from periphery and misinterpretation of X-rays (patient with no neurological deficit could still have a fracture which has been missed by the general physician).

Plain radiographs were the main stay of diagnostic modality in our series but CT scan has become important decision-making imaging modality of spinal injury. We investigated 47 patients with CT scan. The protocol followed at our institute for cranio vertebral trauma is to have X-rays, CT and MRI imaging for patients with neurological deficit. Only X-rays and CT imaging are done in patients without neurological deficit. This protocol could not be followed in some patients to reduce the cost of management as those patients belonged to low socio-economic status. X-ray was the main post-operative imaging

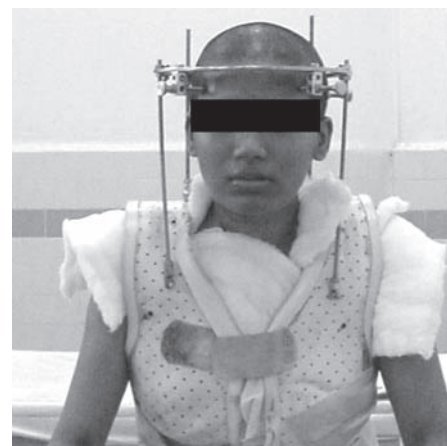

FIGURE 6: Indigenously developed Halo system with Ilizarov frame.

modality.

Initial management consisted of application of skeletal traction in all the cases with instability or cord compression with the exception of occipito-atlantal dislocation

Treatment methods included were halo, collar and surgery. Halo was used in stable fractures and displaced fractures where reduction was achieved with skeletal traction. The speciality of our halo (Figure 6) was that, it was manufactured with locally available material, which brought down the cost significantly i.e. to about Rs 7000/- as compared to the imported one which costs about Rs 200,000. The average duration of halo vest application was for 12 weeks. A total of 18 patients were managed with halo. Two instances of non-union occurred. The main disadvantage of halo was that it took quite some time for the patient to psychologically adjust to the external fixator, restriction of neck movements and the modification in their day-to-day activities.

Surgeries were performed in 54 cases (59.3%), i.e. the majority of the patients were treated with surgery, since most of the patients presented about a month after injury and high incidence of non union is reported if a fracture is treated conservatively after 2 weeks of injury²⁴. Most of them were poor and were the only earning member in the family, hence they could go back to work early following surgery as compared to conservative management.

Atlanto Occipital Dislocation (AOD)

The cranio vertebral junction is often injured in patients who die following trauma to head or neck²⁵⁻²⁷. AOD is associated with 6-8% of all traumatic fatalities²⁵⁻²⁷. Although frequently fatal, AOD can be expected to account for about 1% of presenting traumatic cervical spine injuries. Only one patient out of 91 had Type I AOD (Traynelis)²⁸. This patient underwent successful occipitocervical fusion. Plain radiographs are inadequate to diagnose AOD since the only finding on X-rays is increase in pre-vertebral soft tissue²⁹. CT provides definitive diagnostic imaging²⁹. We did not encounter any patient with occipital condyle fracture.

As this was the only case reported in our series it precludes detailed analysis of management and outcome. Reports of successful management of AOD with good neurological recovery emphasize the importance of prompt diagnosis and management.

Atlas Fractures

Conservative management is the mainstay of treatment. Ninety percent of C1 fractures achieve successful fusion with non-operative strategies^{4,9,30}.

Status of transverse ligament is a key element in determining appropriate therapy for isolated atlantal fractures. If the ligament is competent, rigid cervical collar for 6-8 weeks generally provides adequate treatment. If the ligament is ruptured or avulsed, initial immobilization with Halo for 8-12 weeks provides adequate treatment⁹. Surgical intervention is reserved for non-union of fracture or the presence of atlantoaxial instability after an adequate trial of non-operative management^{4,10,11}. We did not have treatment failures in isolated C1 fracture patients. Combined C1-C2 fracture management primarily depends on C2 fractures.

Axis Fractures

In our series axis fracture was the most common type. Odontoid fractures constituted 63.5%, Hangman's fractures constituted 24% and miscellaneous fractures constituted 10%. These incidences were in accordance with the published literature¹⁸⁻²².

Odontoid Fractures

Fifty four out of 85 axis fracture patients were having odontoid fracture. Type I, Type II and Type III (Anderson and D'Alonzo)¹⁹ constituted 5.5, 70 and 24% respectively of total odontoid fractures. This was matching the incidence patterns of the published literature.

Type I Fractures

Type I fracture accounts for less than 1% of odontoid fracture and is rarely addressed in the literature³¹. These injuries are typically considered stable but several authors suggest that they are unstable and should be considered as a manifestation of AOD. Patients having transverse ligament injury shall need transarticular screw fixation.

Our findings suggest that detailed imaging studies should be performed to assess the stability in Type I fractures.

Type II Fractures

Type II fractures, in which the fracture passes through the base of odontoid, are the commonest. While it has been estimated that more than 25% of the patients with acute C2 fractures die at the scene of accident¹, neurological morbidity tends to be low among survivors.

Historically, the management of Type II odontoid fractures has been controversial. Either external immobilization or internal fixation has been advocated to stabilize these fractures. Some authors recommend a period of external immobilization for all patients and reserve surgery for those who fail to achieve satisfactory bony

union. Other authors advocate operative management as the primary treatment modality. Based on an extensive literature search and critical review of the data, it is evident that no consensus exists for the treatment of type II odontoid fractures.

Johnson and co-workers³² demonstrated the superiority of the Halo vest over conventional braces for external immobilization of cervical spine. The documented overall fusion rate for type II odontoid fractures treated with Halo immobilization was about 65% as compared to our series of 75%.

In all these reviews (Table VI) it appears that greater offset implies greater instability and therefore a lower likelihood of healing when treatment consists of external immobilization alone. It is important to realize that these measurements of offset are essentially a random sampling of any given patient's condition³¹. While it has been argued that the radiographic determination of fusion may be difficult and subject to observer variability, it appears to be the most appropriate outcome measure and is described in the majority of clinical articles addressing odontoid fractures. It is recognized that outcome measures incorporating patient satisfaction, quality of life measures, and function would perhaps be superior, however, this information is sparse and less objective than the fusion criteria described in the literature.

Greene and co-workers³⁹ recommended early surgical procedures for patients whose axis fractures could not be

Table 6. Factors Associated with Non Union of type II Odontoid Fractures Treated Conservatively

Author And Year	No. Of Patients	Nonunion Rate (%)	Significant Factors
Anderson & D'Alonzo, 1974 ¹⁹	49	36	None Specified
Apuzzo et al, 1978 ²⁰	45	33	Age > 40 years, Displacement > 4mm
Ekong et al, 1981 ³³	17	41	Age >= 55 years, Displacement > 4-6mm
Hadley et al, 1985 ²⁴	40	26	Not Age, Displacement > 6mm
Clarke & White, 1985 ³⁴	106	32	Not Age, Displacement > 5mm
Dunn & Seljeskog, 1986 ²¹	88	24	Age >= 65 years, Posterior Displacement
Hanssen & Cabanela, 1987 ³⁵	42	50	Age >= 72 years, Posterior Displacement
Schweigel, 1987 ³⁶	47	10	Not Age, Not Displacement
Hadley et al, 1989 ¹⁴	65	28	Not Age, Displacement > 6mm
Ryan & Taylor, 1993 ³⁷	35	77	Posterior Displacement
Seybold & Bayley, 1998 ³⁸	37	29	Not Age, Displacement Unknown
Greene et al, 1997 ³⁹	88	28	Displacement >= 6mm

maintained by external orthosis, those with ruptured transverse ligament, those with 6mm or more of dense displacement and those with comminuted dense fractures. Traynelis¹ reviewed the published literature on the treatment of type II odontoid fractures and reported an overall successful fusion rate of 64% for posterior bone and wire fusion techniques. The surgical rates of mortality and morbidity were approximately 2% each.

Numerous case series have advocated other surgical approaches including posterior fusion with Halifax clamp fixation, posterior C1-C2 transarticular screw fixation and anterior odontoid screw placement⁴⁰⁻⁴³. In contrast to external immobilization and posterior C1-C2 fusion, direct screw fixation of odontoid provides immediate stabilization and promotes bone healing while preserving normal C1-C2 motion.

Apfelbaum et al⁴⁴ reviewed the surgical outcome of 147 patients who underwent anterior odontoid screw fixation and noted that overall bony fusion was successful in 77%. Separate analysis of recent and chronic groups demonstrated 88% fusion rate for patients with recent fractures, compared with a 25% fusion rate for those with chronic fractures. Chi-squared analysis of the effect of sex, age, fracture type, fracture orientation, degree of odontoid displacement revealed that only fracture orientation significantly affected anatomic bony fusion..

Fusion rate (78%) was comparable to published literature. Patient satisfaction regarding neck movements was good in patients managed with anterior screw placement and halo.

Based on the findings of our study we suggest anterior trans odontoid screw placement in type II odontoid fractures of less than 6 months old, posterior C1 C2 fusion with transarticular screws in chronic fractures and for all patients with disrupted transverse ligaments.

Type III

Usual management of type III fractures is non-operative with halo and collar. Fusion rates are very good with this management. Surgery is indicated only when rupture of transverse ligament was noted or immobilization fails to maintain alignment. In our patients who underwent surgery, 4 patients had rupture of transverse ligament and other patient was initially treated with halo but immobilization failed and hence surgery was performed. All patients achieved bony fusion. Greene and colleagues³⁹ reported their results from 75 patients with type III odontoid fractures. Six patients underwent early surgical fusion because a halo vest failed to maintain alignment. Non-union rate is very low in this series (only one patient had non-union).

Anderson & D'Alonzo¹⁹ reported similar results.

Hangman's fracture

The basic principles guiding the management of hangman fracture have not changed since they were first described by Schneider and colleagues⁴⁵. They concluded that most fractures could be treated conservatively if alignment was corrected and the neck was immobilized.

Among the papers by Effendi and associates⁴⁶, Levine and Edwards⁴⁷ and Francis and coworkers⁴⁸, 32%, 6% and 5.6% of their patients, respectively required surgical stabilization, Hadley and colleagues¹⁴ reported that none of their 25 patients, required either early or late surgical intervention. There are few indications for surgery. In general, poor reduction and non-union are the most common reasons to operate.^{49,50} If surgery is required stabilization can be achieved by a posterior fusion of C1-2 or an anterior fusion of C2-3.

In our series patients managed with surgery was more as compared to that of literature, because most of them were daily labourers and bread earners for their families, and cost of surgical stabilization is 50% more than that of Halo application (locally manufactured halo which cost about Rs.7000/-).

Miscellaneous axis fractures

Greene and coworkers³⁹ described their management of 63 patients with acute miscellaneous fractures. The only patient treated with early surgery had a lateral mass fracture associated with subluxation of C2 over C3. over all, their non-union rate for miscellaneous fractures managed non operatively was 1.6%.

Complications

Complication rate (12.9%) is more in this group compared to published literature¹. The probable reason for this may be that more number of surgeons were involved in management of these cases.

Neurological and implant related complications were more in patients managed with C1 C2 sublaminar wiring technique.

CONCLUSIONS

- The management of patients with posttraumatic cranio vertebral junction instability depends on the characteristics of the fracture.
- The patients with isolated atlas fractures, stable type I and type III odontoid fractures; hangman's fractures and miscellaneous fractures of axis do well with non-operative management.

- For type II odontoid fractures because of the high non-union rates associated with non-operative treatment, we recommend surgical management with direct anterior odontoid screw fixation within 6 months of injury, and posterior transarticular screw fixation for fractures after 6 months of injury.
- Anterior and lateral mass fixation procedures had a lower complication rate as compared to sublaminar wiring methods.
- The overall patient satisfaction for daily survival was better with surgery and collar as compared to halo.

REFERENCES

1. Traynelis VC. Evidence based management of type II odontoid fractures. *Clin Neurosurg* 1997; 44: 41-9.
2. Keller RB. Outcomes research in orthopedics. *J Am Acad Orthp Surg* 1993; 1:122-9.
3. Alexander JT, Haid RW, Jr. Upper cervical spine trauma. Outcome assessment. *Clin Neurosurg* 1993; 44: 305-13.
4. Landells CD, Van Peteghem PK. Fractures of the atlas: Classification, treatment and morbidity. *Spine* 1988 ; 13: 450-2.
5. Dickman CA, Papadopoulos SM, Sonntag VK, et al. Traumatic occipitoatlantal dislocations [review]. *J Spinal Disord* 1993; 6: 300-13.
6. Powers B, Miller MD, Kramer RS, et al. Traumatic anterior atlanto occipital dislocation. *Neurosurgery* 1979; 4; 12-17.
7. Bohlman HH. Acute fractures and dislocations of the cervical spine: An analysis of three hundred hospitalized patients and review of the literature. *J Bone Joint Surg(Am)* 1979 ; 61: 1119-42.
8. Fowler JL, Sandhu A, Faser RD. A review of fractures of the atlas vertebra (review). *J Spinal Disord* 1990; 3: 19-24.
9. Hadley MN, Dickman CA, Browner CM, et al. Acute traumatic atlas fractures: Management and long term outcome. *Neurosurgery* 1998; 23: 31-5.
10. Lipson SJ. Fractures of the atlas associated with fractures of the odontoid process and transverse ligament ruptures. *J Bone Joint Surg (Am)* 1977; 59: 940-3.
11. Sherk HH, Nicholason JT. Fractures of the atlas. *J Bone Joint Surg (Am)* 1970; 52: 1017-24.
12. Spence KF Jr, Decker S, sell KW. Bursting atlantal fractures associated with rupture of the transverse ligament. *J Bone Joint Surg (Am)* 1970; 52: 543-9
13. Bracken MB, Freeman DH Jr, H Hellenbrand K. Incidence of acute traumatic hospitalised spinal cord injury in the United States, 1970-1977. *Am J Epidemiol* 1981; 113:615-22.

14. Hadley MN, Dickman CA, Browner CM et al. Acute axis fractures: a review of 229 cases. *J Neurosurg* 1989; 71: 642-7.
15. Huelke DF, O' Day J, Mendelsohn RA. Cervical injuries suffered in automobile crashes. *J Neurosurg* 1981; 54: 316-322.
16. Lee TT, Green BA, Petrin DR. Treatment of stable burst fractures of the atlas (Jefferson fracture) with rigid cervical collar. *Spine* 1998; 23: 1963-7.
17. Kesterson L, Benzel E, Orrison W, et al. Evaluation and treatment of atlas burst fractures (Jefferson fractures). *J Neurosurg* 1991; 75: 213-20.
18. Amyes EW, Anderson FM. Fracture of odontoid process: Report of sixty-three cases. *Arch Surg* 1956;72: 377-93.
19. Anderson LD, D' Alonzo RT. Fractures of the odontoid process of the axis. *J Bone Joint Surg (Am)* 1974; 56: 1663-74.
20. Apuzzo MLJ, Heiden JS, Weiss MH, Ackerson TT, Harvey JP, Kurze T. Acute fractures of the odontoid process: An analysis of 45 cases. *J Neurosurg* 1978; 48: 85-91.
21. Dunn ME, Seljeskog EL. Experience in the management of odontoid process injuries: an analysis of 128 cases. *Neurosurgery* 1986; 18: 306-10.
22. Schatzker J, Rorabeck CH, Waddell JP. Fractures of the dens (odontoid process):An analysis of thirty-seven cases. *J Bone Joint Surg (Br)* 1971;53B: 392-405.
23. Southwick WO. Management of fractures of the dens (odontoid process). *J Bone Joint Surg (Am)* 1980; 62A: 482-6.
24. Hadley MN, Browner C, Sonntag VK. Axis fractures: a comprehensive review of management and treatment in 107 cases. *Neurosurgery* 1985; 17: 281-90.
25. Alexander EJ, Davis CHJ, Field CH. Hyperextension injuries of the cervical spine. *Arch Neurol Psychiatry* 1958; 79: 146-50.
26. Bucholz RW, Burkhead WA, Graham W, et al. Occult cervical spine injuries in fatal traffic accidents. *J Trauma Infect Crit Care* 1979; 19: 768-71.
27. Alker GJ Jr, OH YS, Leslie EV: High Cervical Spine and craniocervical junction injuries in fatal traffic accident: Radiological study. *Orthop Clin North Am* 1978; 9: 1003-10.
28. Traynelis VC, Marano GD, Dunker RO, et al. Traumatic atlanto occipital dislocation: Case report. *J Neurosurg* 1986; 65:863-870. erratum in *J Neurosurg* 1987; 66:789
29. Taggard DA. Treatment of occipital C1 Injury In : Winn HR (ED). Youmans Neurological surgery vol IV Philadelphia, Saunders (2004): 4925-37.
30. Levine AM, Edwards CC. Fractures of the atlas. *J Bone Joint Surg (Am)* 1991; 73:680- 91.
31. York JE. Treatment of Axis Fractures In: Winn HR (ED). Youmans Neurological Surgery vol IV Philadelphia Saunder (2004): 4939-49.
32. Johnson RM, hart DL, Simmons EF, et al. Cervical orthoses: A study comparing their effectiveness in restricting cervical motion in normal subjects. *J Bone Joint Surg Am* 1977; 59:332-9.
33. Ekong CE, Schwartz ML, Tator CH et al. Odontoid fracture: management with early mobilization using the halo device. *Neurosurgery* 1981; 9: 631-7.
34. Clark CR, White AA. Fractures of the dens. A multicenter study. *J Bone Joint Surg (Am)* 1985; 67: 1340-8.
35. Hanssen Ad, Cabanela ME. Fractures of the dens in adult patients. *J Trauma* 1987; 27: 928-34.
36. Schweigel JF. Management of the fractured odontoid with halothoracic bracing. *Spine* 1987; 12:838-839.
37. Ryan MD, Taylor Tk. Odontoid Fractures in the elderly. *J Spinal Disord* 1993; 6: 397-401.
38. Seybold EA, Bayley JC. Functional outcome of surgically and conservatively managed dens fractures. *Spine* 1998; 23: 1837-46.
39. Greene KA, Dickman CA, Marciano FF, et al. Acute axis fractures: Analysis of management and outcome in 340 consecutive cases. *Spine* 1997; 22: 1843-52.
40. Aldrich EF, Weber PB, Crow WN. Halifax interlaminar clamp for posterior cervical fusion: A long term follow-up review. *J Neurosurg* 1993; 78: 702-8.
41. Dickman CA, Sonntag VKH, Papadopoulos Sm, et al. The interspinous method of posterior atlantoaxial arthrodesis. *J Neurosurg* 1991; 74: 190-8
42. Geisler FH, Cheng C, Poka A, et al: Anterior screw fixation of posteriorly displaced type II odontoid fractures. *Neurosurgery* 1989; 25: 30- 38.
43. Marcotte P, Dickman CA, Sonntag VKH, et al. Posterior atlantoaxial facet screw fixation. *J Neurosurg* 1993; 79:234-7.
44. Apfelbaum RL, Lonser RR, Veres R, et al. Direct anterior screw fixation for recent and remote odontoid fractures. *J Neurosurg* 2000; 93(supp 2): 227-36.
45. Schneider RC, Livingston KE, Cave AJ, et al. "Hangman's fracture" of the cervical spine. *J Neurosurg* 1965; 22:141-54.
46. Effendi B, Roy D, Cornish B, et al. Fractures of the ring of the axis: A classification based on the analysis of 131 cases. *J Bone Joint Surg (Br)* 1981; 63:319-27.
47. Levine AM, Edwards CC.The management of traumatic spondylolisthesis of the axis. *J Bone Joint Surg (Am)* 1985; 67: 217-26.
48. Francis WR, Fielding JW, Hawkins RJ,et al. Traumatic spondylolisthesis of the axis. *J Bone Joint Surg (Br)* 1981; 63:313-8.
49. An HS: Cervical spine trauma: *Spine* 1998; 23: 2713-29.
50. Barros TE, Bohlman HH, Capen DA, et al. Traumatic spondylolisthesis of the axis ; Analysis of management. *Spinal Cord* 1999; 37: 166-71.