



# Outcome of Pregnancies with Isolated Absent Fetal Nasal Bone in the Second Trimester

Purvi Desai<sup>1</sup> · Binodini Chauhan<sup>2</sup> · Manisha Jhavar<sup>3</sup> 

Received: 11 January 2019 / Accepted: 14 February 2019 / Published online: 28 February 2019  
© Society of Fetal Medicine 2019

**Abstract** Absent nasal bone is associated with 58 genetic syndromes, Trisomy 18 and trisomy 21. It increases the sensitivity of second trimester scan for aneuploidy from 83 to 90%. Since 2003, absent or unossified nasal bone is therefore an integral part of the second trimester scan. The present study aimed at confirming the sensitivity of isolated absent NB in the second trimester USG, by reviewing the karyotypes and/or postnatal outcomes of such pregnancies up till at least 6 months of postnatal life. Facial profile was seen in 2D and 3D reconstructed view in all the cases to avoid missing the unilateral absence of nasal bone. Complete detailed scan and FISH on amniotic fluid cells was advised for all the cases with absent nasal bone. The present study concluded that isolated absence of NB in the second trimester may not be an effective marker for diagnosis of Down's syndrome. Amniocentesis should be advised only if absent nasal bone is associated with any other structural abnormality or additional soft marker.

**Keywords** Nasal bone (NB) absent nasal bone · Hypoplastic nasal bone · NBL nasal bone length · 3D three dimension · 2D two dimension

## Introduction

Aneuploidy causes aberration in fetal development, which may or may not be compatible with life. These fetuses either expire in utero or within first few years of life. Those who survive longer are mentally retarded with very poor to average IQ scores. These children are a social burden for the parents and society. Various non invasive markers have been identified which point towards the likely possibility of aneuploidy and warrant a confirmation by evaluating the amniotic cells. The invasive procedures required to procure amniotic cells are not just a threat to the growing fetus but also an economical burden. It is therefore essential to confirm the validity of individual non invasive markers so that aneuploidy is neither missed nor over diagnosed.

Absent nasal bone or unossified nasal bone was found to be associated with 58 genetic syndromes and Trisomy 18 and 21. It was found that the addition of absent nasal bone in the list of second trimester sonomarkers, increased the sensitivity of scan for detection of aneuploidy from 83 to 90% [1]. Since 2003, absent nasal bone is an integral part of the second trimester scan.

## Aims and Objectives

The present study aimed at determining the significance of absent nasal bone in the second trimester ultrasound, when rest of the anomaly scan was normal. The karyotypes and/or postnatal outcome of such fetuses followed up to 6 months of post natal life.

✉ Manisha Jhavar  
drmanishal@gmail.com

Purvi Desai  
drpurvi\_desai@yahoo.in

Binodini Chauhan  
drbinodini@yahoo.com

<sup>1</sup> Department of Radiodiagnosis, New Civil Hospital, Surat, India

<sup>2</sup> Fetal Medicine Center, Ring Road, Surat, India

<sup>3</sup> Palladium Complex, VIP Road, Surat, India

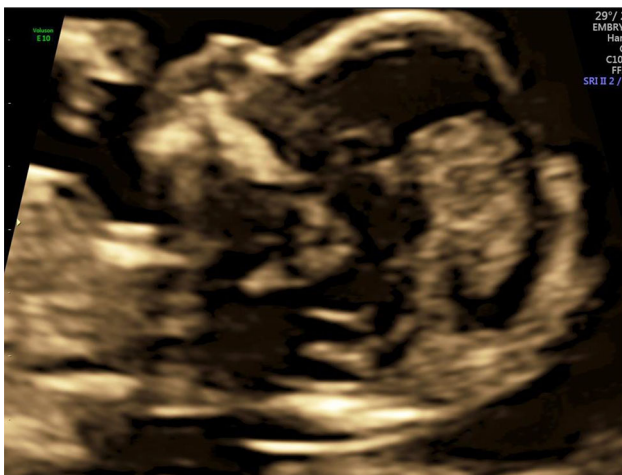## Materials and Methods

This was a prospective study of the Asian singleton women between 18–23 weeks enrolled for USG at our center from 1st Jan 2017 to 30th June 2018. Consent was taken from all the women after duly explaining the procedure.

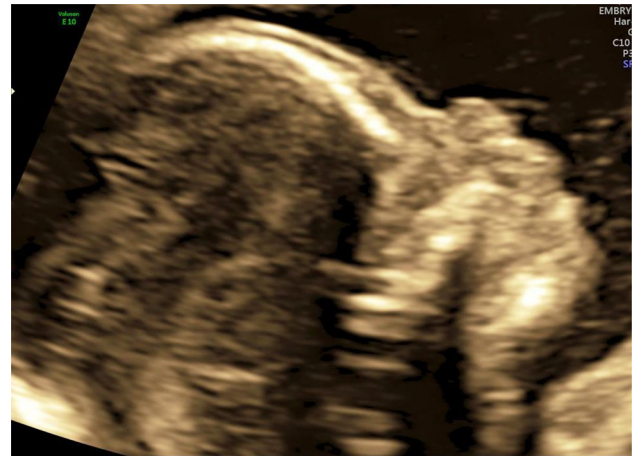The technique of imaging nasal bone was formulated following the guidelines of International Society of Ultrasound in Obstetrics and Gynecology to ensure consistency and quality control [2]. Following soft markers were looked for in all the scans: absent nasal bone, increased nuchal fold thickness ( $\geq 6$  mm), short femur or humerus, ventriculomegaly ( $\geq 10$ mm), hyper-echoic bowel, echogenic intracardiac focus, pyelectasis ( $\geq 5$  mm), aberrant right subclavian artery.

Nasal bone was visualized as a linear echogenic structure keeping angle of insonation at around  $45^\circ$  or  $135^\circ$  [3]. Nasal bone was measured but only absence or presence of nasal bone was appraised. In the present study, we did not take length of nasal bone into consideration to avoid intra observer and inter observer variability associated with the measurement of the length. Moreover, for using length of the nasal bone as a marker of aneuploidy it is essential to have specific sonographic nomographs and cut offs for the population to be studied, to combat for the ethnic and racial differences in NBL. The length of the nasal bone also increases with gestational age leading to further discrepancy (Figs. 1, 2).

All the scans were done/supervised by qualified fetal medicine specialist. Absent nasal bone (unossified NB) was suspected when in the mid-sagittal view of face, three distinct lines, first nasal bone, second skin and third tip of the nose were not seen. The confirmation was done by visualizing two echogenic dots at the apex of the retranasal



**Fig. 1** Mid sagittal view of face with three distinct lines confirming presence of nasal bone



**Fig. 2** Magnified Mid sagittal view of fetal head with absent nasal bone. Visualization of nasal bone in two-dimensional images of the fetal head in the sagittal plane, enlarged to include nose, lips, maxilla and mandible

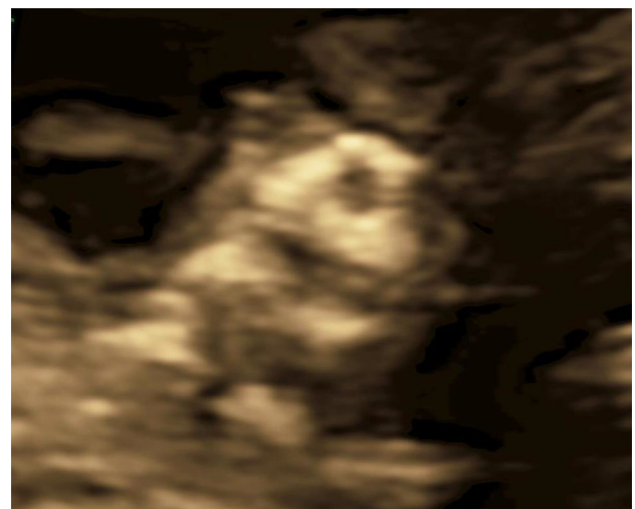triangle in coronal view in 2D and reconstructed 3D view (Figs. 3, 4, 5, 6).

Facial profile was seen in 2D and 3D reconstructed view in all the cases to avoid missing the unilateral absence of nasal bone which may not be picked in 2D alone [4].

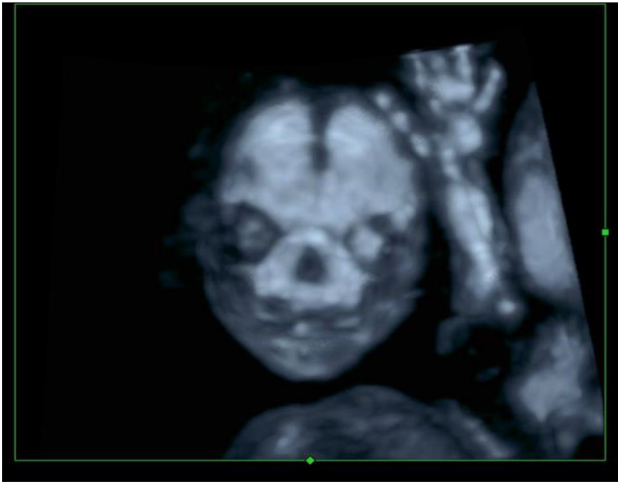
Ultrasound dating was used when the discrepancy in menstrual date was  $> 10$  days.

All the patients with either an isolated absent nasal bone or with presence of additional ultrasound features or biochemical markers were counseled for the appropriate invasive testing.

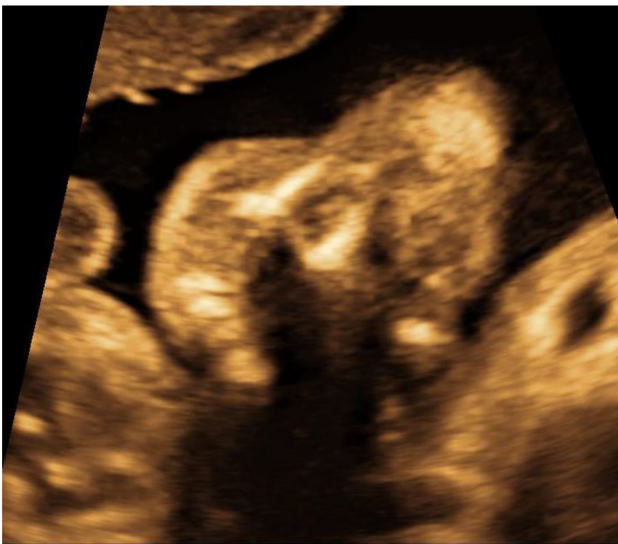Analysis of amniotic fluid cells was done using FISH studies for chromosome 13, 18, 21 and sex chromosome. Culture of amniotic cells was also done in all the cases for knowing the complete karyotype.



**Fig. 3** Visualization of nasal bone in two dimensional coronal view, the presence of two echogenic dots confirms the presence of bilateral nasal bones



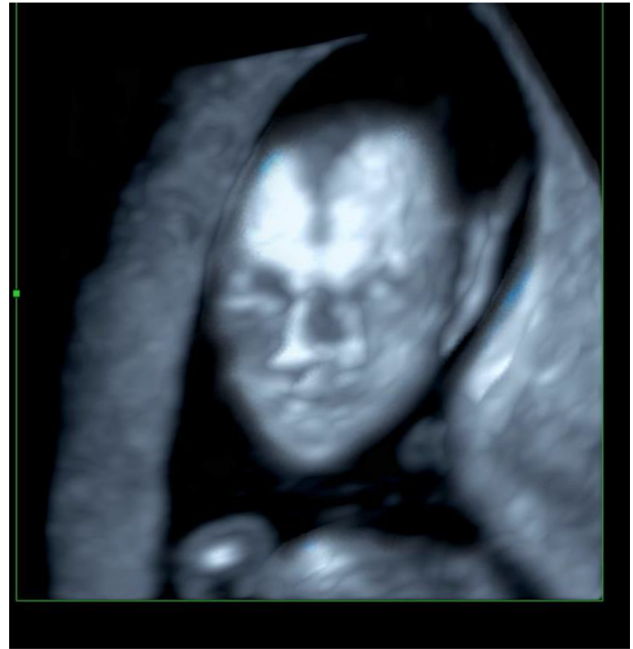**Fig. 4** Three dimensional view of the face in coronal plane. A complete retronasal triangle confirms the presence of bilateral nasal bones



**Fig. 5** Visualization of nasal bone in two dimensional coronal view, the absence of the echogenic dots at the apex of retro nasal triangle suggests the absence of nasal bones

## Results

Out of 2339 cases scanned between 1st Jan 2017 to 30th June 2018, 380 (16.2%) were abnormal, 4 cases were diagnosed with Down's syndrome, 31 cases had facial anomalies (1.3% of total scans and 8.1% of abnormal scans), 12 cases showed isolated absent (hypoplasia) nasal bones (3.1% of total scans and 38.7% of abnormal scans), unilateral cleft lip and cleft palate was found in 6 cases, bilateral cleft lip and palate was found in 3 cases, ear abnormalities were found in 4 cases, micrognathia in 3 cases and 1 case each with dysmorphic facies, Binder's facies, and microphthalmia (Fig. 7).



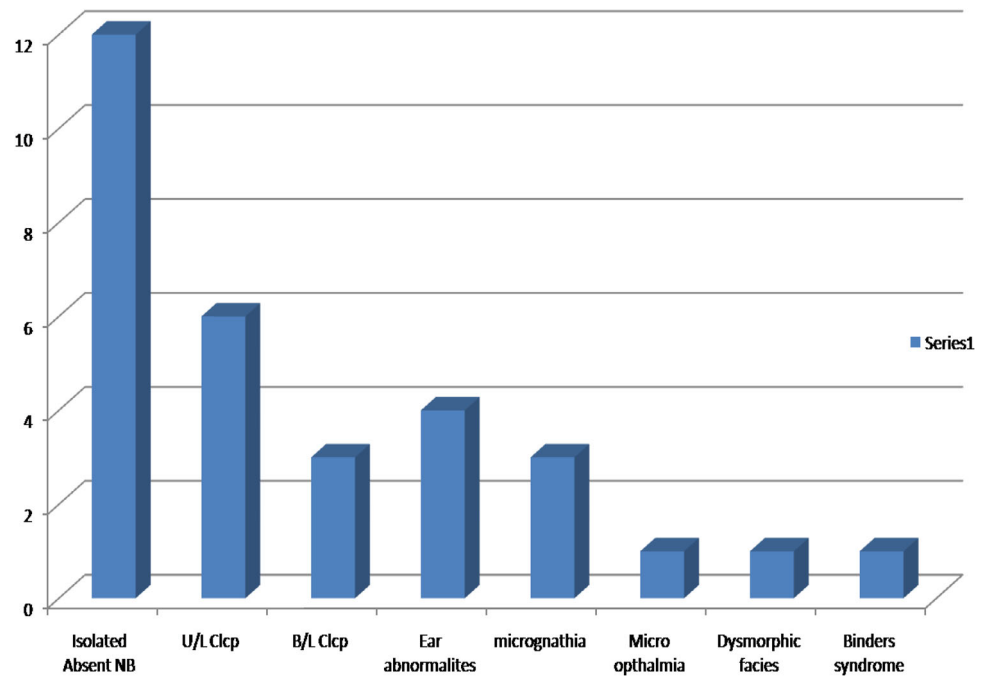
**Fig. 6** Three dimensional view of the face in coronal plane, the absence of the echogenic dots at the apex of retro nasal triangle suggests the absence of nasal bones

The cases with isolated absent nasal bone were between 22–30 years of age and were carrying 18–23 weeks pregnancy. No other high risk factor was identified in any of these 12 cases. Four cases had already undergone biochemical screening with low risk results. Biochemical testing was not advised in the cases diagnosed with isolated absence of nasal bone.

A second trimester ultrasound risk was obtained in all cases and they all were counseled for fetal karyotyping. Four cases underwent amniocentesis and the results were normal. One couple opted for termination of pregnancy directly without undergoing amniocentesis for confirmation. Eleven cases out of the 12 cases (91.6%) diagnosed with isolated absent nasal bone delivered alive, healthy babies. The babies were followed for a minimum of six months post partum. One sudden neonatal cot death occurred probably because of aspiration on the 25th day of delivery.

During the study period from 1st Jan 2017 to 30th June 2018, there were six cases where absent nasal bone was associated with other findings, like short long bones in four cases, positive bio-chemistry in one case and single umbilical artery in one case. Amniocentesis was advised to all six of them. Five (83.4%) cases had normal karyotype and one (16.6%) was positive for Trisomy 21. The case with trisomy 21 had absent NB associated with short long bones (short femur and humerus at 2nd percentile, constitutional shortening was ruled out). The second trimester ultrasound risk of this case was 1:3 and age risk was 1:448.

**Fig. 7** 12 cases showed absent (hypoplasia) nasal bones unilateral cleft lip and cleft palate was found in 6 cases, bilateral cleft lip and palate was found in 3 cases, ear abnormalities were found in 4 cases, micrognathia in 3 cases 1 case each with dysmorphic facies, Binder's facies, and microphthalmia



## Conclusion

The use of isolated absent NB in the second trimester USG may not be an effective screening tool for Down's syndrome.

Amniocentesis is indicated [5] for fetuses with associated structural abnormality or additional soft marker which should be carefully searched for by an expert sonologist.

The cases of isolated absent nasal bone should be reassured strongly for an expected positive outcome of the baby and termination of pregnancy before undergoing karyotyping should be discouraged.

## References

1. Vintzileos A, Walters C, Yeo L. Absent nasal bone in the prenatal detection of the fetuses with Trisomy 21 in a high risk population. *Obstet Gynecol.* 2003;101:905.

2. Rotten D, Levallant JM. Two- and three-dimensional sonographic assessment of the fetal face. *Ultrasound Obstet Gynecol.* 2004;23:224–31.
3. Sonek JD, Nicolaidis KH. Prenatal ultrasonographic diagnosis of nasal bone abnormalities in three fetuses with Down's syndrome. *Am J Obstet Gynecol.* 2002;186:139.
4. Benoit B, Chaoui R. Three dimensional ultrasound with maximal mode rendering: a novel technique for the diagnosis of bilateral or unilateral absence or hypoplasia of nasal bones in second trimester screening for Down syndrome. *Ultrasound Obstet Gynecol.* 2005;25:19.
5. Ting YH, Lao TT, Lau TK, Chung MK, Leung TY. Isolated absent or hypoplastic nasal bone in the second trimester fetus: is amniocentesis necessary? *J Matern Fetal Neonatal Med.* 2011;24(4):555–8.

**Publisher's Note** Springer Nature remains neutral with regard to jurisdictional claims in published maps and institutional affiliations.