



Isolated Intra-abdominal Umbilical Vein Varix: A Case Report

Ladbans Kaur¹ · Ritambhara Bhalla² · Divya Singh¹ · Hargunbir Singh³

Received: 1 February 2016 / Accepted: 4 May 2016 / Published online: 25 May 2016
© Society of Fetal Medicine 2016

Abstract A 28-year-old primigravida was referred at 24 weeks of gestation for growth scan. Ultrasound revealed an ovoid anechoic intra-abdominal structure. Color Doppler showed its continuity with umbilical vein and venous flow within it. A diagnosis of umbilical vein varix was made. Thereafter, the fetus was monitored at two weekly intervals. Due to increase in size of varix and development of echoes, an elective cesarean section was performed at 34 weeks. The baby cried at birth with a normal postnatal outcome.

Keywords Fetus · Intra-abdominal · Umbilical vein · Varix · Color Doppler

Introduction

Fetal intra-abdominal umbilical vein varix (FIUV) is a prenatal sonographic finding and is defined as the diameter of umbilical vein at least 50 % wider than the diameter of the intrahepatic segment or when the diameter of the umbilical vein is 9 mm or greater [1]. The diagnosis can be made by visualization of a cystic mass in relation to the umbilical vein followed by color Doppler. The clinical significance of this finding is unclear although in some reports, it is associated with poor fetal

prognosis [2]. Some of the complications which are found to be related to FIUV in the literature are thrombosis, rupture, and cardiac insufficiency as a result of increased cardiac preload. However this anomaly, if isolated, is unlikely to cause major fetal problems. FIUV is generally diagnosed in the second and third trimester. In this communication, we describe a case which showed an uneventful outcome.

Report of Case

A 28-year-old primigravida was referred for a growth scan at 24–25 weeks of gestation. Her prior anomaly scan was unremarkable. The ultrasound examination revealed an anechoic ovoid lesion in continuity with the intra-abdominal part of the umbilical vein measuring 20 × 19 mm in size (Fig. 1). Color Doppler showed complete color filling of the lesion, which was in continuity with the umbilical vein. Spectral Doppler showed a continuous venous flow within it. A detailed anatomic scan was performed to exclude associated abnormalities. Fetal echocardiography was normal. Hence, the diagnosis of isolated intra-abdominal intrahepatic umbilical vein varix was made. The fetus was monitored at fortnightly interval. It showed normal growth curve with no increase in the size of the varix. Ultrasound at 33–34 weeks showed an increase in the size of the umbilical vein varix measuring 33 × 22 mm (Fig. 2). In addition, there was development of echoes in it. A cesarean section was performed at 34 weeks and a baby weighing 2105 g was delivered with normal Apgar scores. Postnatal ultrasound evaluation of the neonate was performed, which showed echoes in the region of the varix with no color flow. Complete obliteration of the varix was seen three weeks following the birth of the baby.

✉ Ladbans Kaur
ladbans@gmail.com

¹ Prime Diagnostic Centre and Heart Institute, SCO 155, Sector 24-D, Chandigarh 160023, India

² Fortis Hospital, Mohali, Punjab, India

³ Government Medical College and Hospital, Sector 32, Chandigarh, India

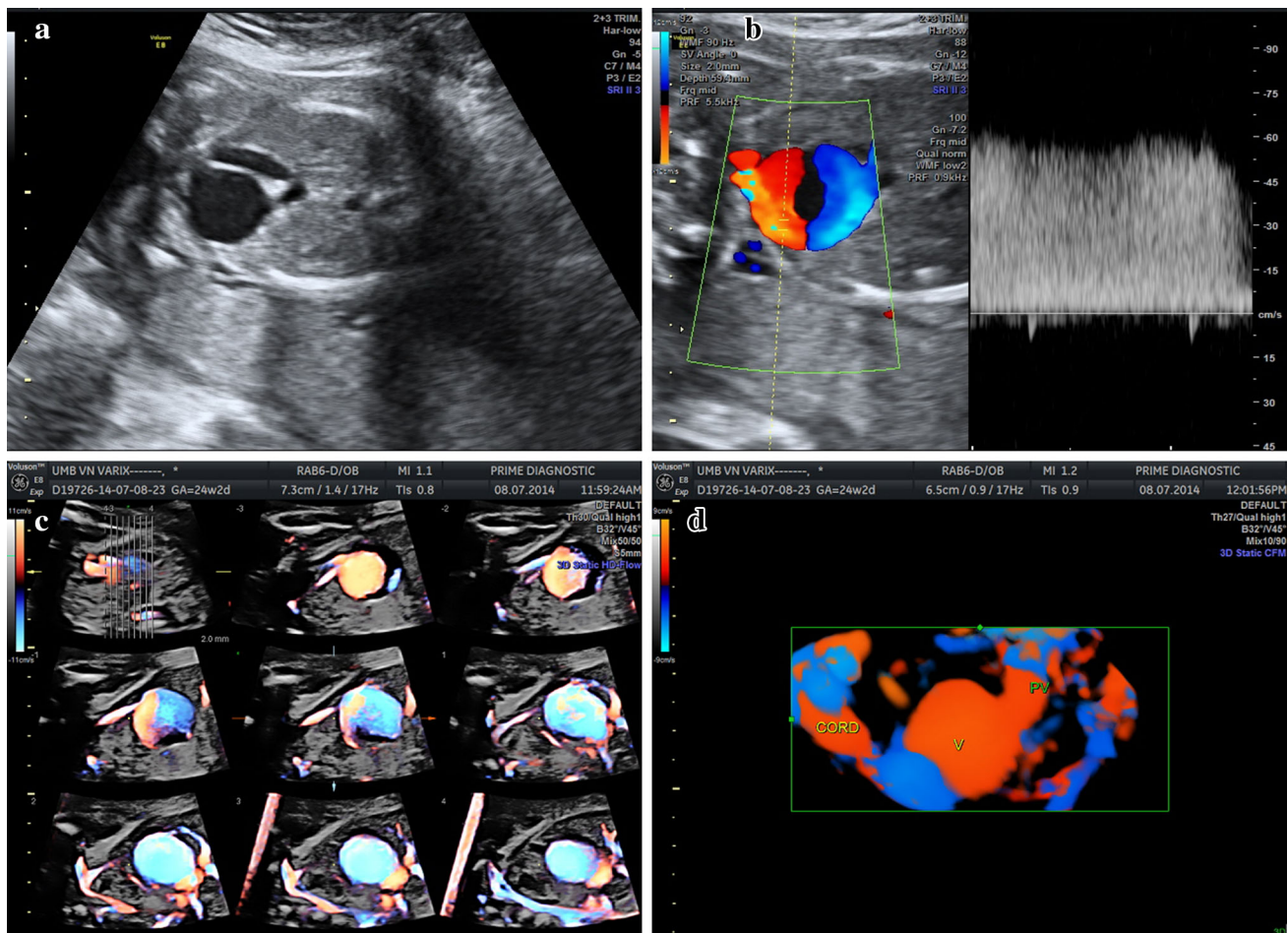


Fig. 1 **a** B-mode axial ultrasound of the fetal abdomen at 24 weeks showing a large anechoic lesion in the abdomen in relation to the umbilical vein. **b** Color Doppler showing spontaneous continuous flow

in the varix. **c, d** Tomographic ultrasound and color power angiography image showing extent of the varix. Note the continuity of the varix proximally with the cord and distally with the portal vein

Discussion

Intra-abdominal umbilical vein varix is a focal dilatation of an intra-abdominal segment of the umbilical vein. The etiology is indeterminate. Intrahepatic intra-abdominal umbilical vein varix is rare as compared to the extrahepatic form. This anomaly is not observed in the first or second trimester scans and may only be observed in progressive stages of pregnancy.

On grayscale sonography, cystic appearance of the umbilical vein raises the suspicion of varix. Color Doppler assesses the vascular nature of the lesion and determines presence of thrombosis.

Umbilical vein varix may be associated with intrauterine death, and structural/chromosomal anomalies. On diagnosis

of umbilical vein varix, a detailed anatomic scan of the fetus should be performed to exclude associated anomalies [3]. It is also prudent to refer the patient for fetal echocardiography to exclude minor cardiac anomalies [4]. Amniocentesis should be offered when other anomalies are found [5].

It has been associated with mortality in utero due to thrombosis of the varix leading to fetal death and complications including hydrops [6]. Serial sonographic evaluation of the fetus, with particular attention to the size and the blood flow within the varix, should be carried out. In cases of intrauterine growth restriction or turbulence in the varix, closer surveillance is recommended. Fetal hydrops or presence of clot in varix warrants prompt delivery. Delivery must be induced when lung maturity has been accomplished, or any fetal distress is apparent [7].

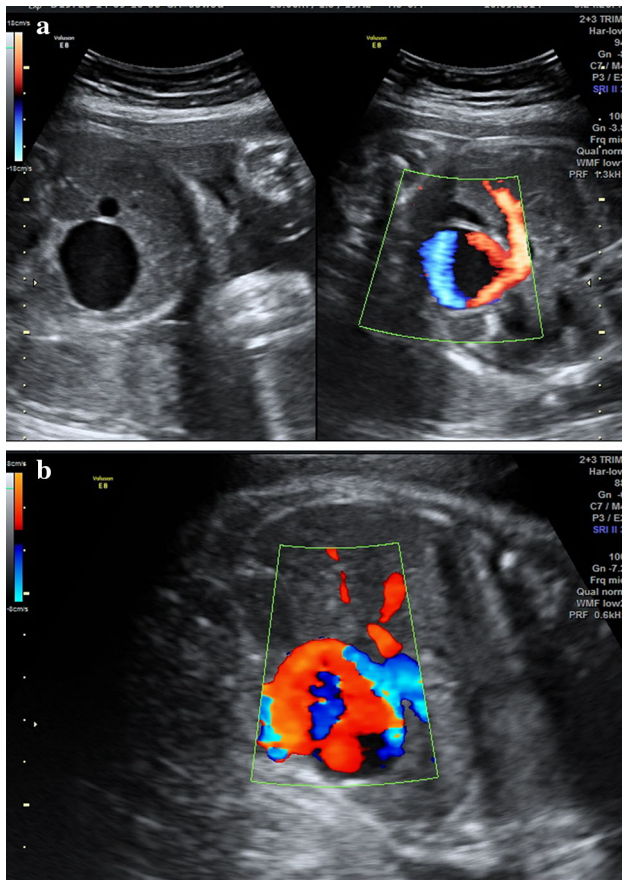


Fig. 2 a, b Repeat ultrasound evaluation at 33–34 weeks of gestation showing increase in the dimension of the umbilical vein varix

Umbilical vein varix may regress without complications in the postpartum period as in our case.

Compliance with ethical standards

Conflict of interest None.

References

1. Nyberg D. Varix of the umbilical vein. In: Nyberg DA, Mc-Gahan JP, Pretorius DH, Pilu G, editors. Diagnostic imaging of fetal anomalies. Philadelphia: Lippincott Williams & Wilkins; 2003. p. 114–5.
2. Mahony BS, McGahan JP, Nyberg DA, et al. Varix of the fetal intra-abdominal umbilical vein: comparison with normal. *J Ultrasound Med.* 1992;11:73–6.
3. Byers BD, Goharkhay N, Mateus J, Ward KK, Munn MB, Wen TS. Pregnancy outcome after ultrasound diagnosis of fetal intra-abdominal umbilical vein varix. *Ultrasound Obstet Gynecol.* 2009;33:282–6.
4. Rahemtullah A, Lieberman E, Benson C, Norton ME. Out-come of pregnancy after prenatal diagnosis of umbilical vein varix. *J Ultrasound Med.* 2001;20:135–9.
5. Fung TY, Leung TN, Leung TY, Lau TK. Fetal intra-abdominal umbilical vein varix: What is the clinical significance? *Ultrasound Obstet Gynecol.* 2005;25:149–54.
6. Sepulveda W, Mackenna A, Sanchez J, Corral E, Carstens E. Fetal prognosis in varix of the intrafetal umbilical vein. *J Ultrasound Med.* 1998;17:171–5.
7. Weissmann-Brenner A, Simchen MJ, Moran O, Kassif E, Achiron R, Zalel Y. Isolated fetal umbilical vein varix: prenatal sonographic diagnosis and suggested management. *Prenat Diagn.* 2009;29:229–33.