

# Invasive Epilepsy Monitoring: The Switch from Subdural Electrodes to Stereoelectroencephalography

Rohini Coorg<sup>1,2</sup> Elaine S. Seto<sup>1,2</sup>

<sup>1</sup>Section of Pediatric Neurology and Developmental Neuroscience, Department of Pediatrics, Baylor College of Medicine, Houston, Texas, United States

<sup>2</sup>Department of Neurology and Developmental Neuroscience, Texas Children's Hospital, Houston, Texas, United States

Address for correspondence Rohini Coorg, MD, Department of Neurology and Developmental Neuroscience, Texas Children's Hospital, 6701 Fannin Street, Suite 1250, Houston, TX 77030, United States (e-mail: Rohini.Coorg@bcm.edu).

J Pediatr Epilepsy 2023;12:21–28.

## Abstract

### Keywords

- ▶ stereoelectroencephalography
- ▶ SEEG
- ▶ subdural electrodes
- ▶ epilepsy surgery
- ▶ invasive monitoring
- ▶ seizure

Stereoelectroencephalography (SEEG) has experienced an explosion in use due to a shifting understanding of epileptic networks and wider application of minimally invasive epilepsy surgery techniques. Both subdural electrode (SDE) monitoring and SEEG serve important roles in defining the epileptogenic zone, limiting functional deficits, and formulating the most effective surgical plan. Strengths of SEEG include the ability to sample difficult to reach, deep structures of the brain without a craniotomy and without disrupting the dura. SEEG is complementary to minimally invasive epilepsy treatment options and may reduce the treatment gap in patients who are hesitant about craniotomy and surgical resection. Understanding the strengths and limitations of SDE monitoring and SEEG allows epileptologists to choose the best modality of invasive monitoring for each patient living with drug-resistant seizures.

## Introduction

A well-experienced epilepsy center is central to the successful surgical treatment of children with drug-resistant epilepsy, which can account for up to one-third of all cases.<sup>1–3</sup> Epilepsy surgery is often underutilized or may occur many years following demonstration of drug resistance.<sup>4</sup> Multiple factors contribute to this. First, identifying the cortical area responsible for generating seizures can be challenging. When the noninvasive presurgical evaluation is unable to identify a consistent probable generator, further diagnostic information through invasive monitoring is needed often to guide focal surgery. This entails placing electrodes into specific regions of the brain to characterize seizure onset electrophysiologically. Traditionally, this has been performed by open craniotomy and extensive subdural electrode (SDE) placement. Ictal data implicating focal onset guides resective surgery with the larger resections associated with greater likelihood of seizure freedom but higher risk of functional

deficit.<sup>5</sup> The perceived morbidity and risk of functional impairment from SDE monitoring and epilepsy resection have deterred some patients from considering epilepsy surgery. Additionally, focal epilepsy surgery has long focused on an all-or-nothing goal of seizure freedom, leading many to only pursue an epilepsy surgery workup in patients with high likelihood of seizure freedom. Patients with multifocal seizures are sometimes considered nonideal surgical candidates. These factors have been shown to contribute to a treatment gap with fewer than expected individuals experiencing benefits that surgery may offer.<sup>6,7</sup>

Over recent years, there is growing recognition of the importance of palliative epilepsy surgery in the pediatric population in improving seizure burden and quality of life.<sup>8</sup> This in combination with technological advances has led to greater interest in stereoelectroencephalography (SEEG) and minimally invasive surgical options that have less perceived morbidity but still favorable efficacy.<sup>6,7,9</sup> In addition, there has been a shift in thinking of seizures as originating from an

received

November 13, 2022

accepted

November 13, 2022

article published online

January 6, 2023

© 2023, Thieme. All rights reserved.  
Georg Thieme Verlag KG,  
Rüdigerstraße 14,  
70469 Stuttgart, Germany

DOI <https://doi.org/10.1055/s-0042-1760105>.  
ISSN 2146-457X.

isolated epileptogenic zone (EZ) to a network involving multiple brain regions driven by a focal generator, or in some cases, multiple focal generators. With the increased use of SEEG, seizures may be explored from onset to end in an anatomo-electro-clinical manner. A primary hypothesis as well as alternative hypotheses may be simultaneously evaluated.

Above all, localizing the EZ is the goal. The definition of EZ has evolved over time: from a single onset for which surgical removal results in seizure freedom to a network of tightly connected epileptogenic nodes with one or more primary drivers.<sup>10</sup> How we study seizures has similarly evolved. This article will explore benefits and challenges of SEEG compared with SDE monitoring. Both techniques require a detailed presurgical evaluation to guide implantation. Both approaches are safe and effective but differ in their ability to record specific brain regions, localize functional tissue, and define surgical borders in the absence of a lesion. Ultimately each technique may further inform a surgical plan to reduce or eliminate seizures, minimize functional deficits, and improve quality of life. While there is no class 1 or 2 evidence for selecting SDE monitoring versus SEEG, an International League Against Epilepsy task force recommends a consensus-based determination of invasive monitoring predicated on the strengths and limitations of each technique.<sup>11</sup>

### Subdural Electrode Monitoring

In combination with a detailed presurgical evaluation, SDE monitoring is an excellent tool to define the irritative zone, functional deficit zone, seizure onset zone, and symptomatogenic zone, aiding in conceptualizing a probable EZ, the region necessary and sufficient for initiating seizures such that removal abolishes seizures.<sup>12,13</sup> SDE monitoring involves primarily the implantation of grid/strip SDEs following open craniotomy. The size and location of the large surgical exposure are based on a single hypothesized EZ and anticipated resection plan. Limited anatomically disparate sampling can be added through burr holes. SDEs consist of regular arrays of disc electrodes spaced 5 to 10 mm apart. This organization generally allows for gyrus-by-gyrus neurophysiologic characterization of ictal onset and functional activity in two dimensions. They can also be used later as anatomic markers to guide the extent of resection. Electrodes overlying vasculature or sulci may not reliably record activity due to inadequate cortical contact.

SDE monitoring is subject to anatomic limitations. SDEs do not record from gray matter lining the sulcus, a limitation that may be partially addressed by the addition of depth electrodes inserted between SDE contacts. Bridging veins in the interhemispheric fissure and dural adhesions at the brain base can impede SDE sampling in these regions. Similarly, patients who have developed adhesions due to a prior craniotomy can be challenging to implant. Bilateral craniotomies and grids are generally not performed due to increased risk of complications.<sup>14</sup> Given these constraints, SDE monitoring may not be ideal if seizures arise from deeper brain

structures or disparate anatomic regions have been implicated in the presurgical workup. Even with apparently concordant data, inadequate sampling can lead to poor surgical outcomes. Several studies have described adults with presumed unilateral temporal lobe seizures by semiology and surface EEG who subsequently underwent invasive monitoring and were found to have contralateral temporal or extratemporal seizure onset.<sup>15,16</sup> In particular, some of these regions, including the insula, orbitofrontal cortex, and cingulate gyrus, are challenging to sample by SDE monitoring.

Nonhabitual seizures can be seen in SDE monitoring,<sup>17</sup> likely related to cortical irritability from the foreign body or complications. In a meta-analysis of 2,542 adult and pediatric patients, increased electrode number and monitoring duration are risk factors for complications.<sup>18</sup> The most common adverse event is infection with 2.3% neurologic infections and 3% superficial infections. Treatment with prophylactic antibiotics is common in many centers. Intracranial hemorrhage was seen in 4% of patients, commonly subdural hematomas due to disrupted bridging veins. Approximately one-third of hemorrhages were symptomatic or required surgical intervention. Disruption of the cranial vault as well as implantation of SDEs can induce cerebral edema, which can then contribute to elevated intracranial pressure. Many centers treat cerebral edema with corticosteroids, although this may suppress seizures. Symptomatically increased intracranial pressure was seen in 2.4%. Neurologic deficits including hemiparesis, aphasia, and headache were noted in at least 4.6% of cases with some centers considering transient neurologic symptoms inevitable. Seven patients required electrode removal for intracranial infection, urgent neurologic deficit, or increased intracranial pressure. Permanent neurologic deficits were very rare. Five deaths were reported related to vascular compromise, elevated intracranial pressure, or aspiration.

### Invasive Monitoring by SEEG

When considering seizures as a network disorder with dynamic changes and the EZ as the sites of seizure onset and primary seizure organization,<sup>19</sup> SEEG provides benefits over SDE monitoring. Depth electrodes have been utilized as early as 1959 by Bancaud and Talairach to study the onset and propagation of seizures. They established the importance of an anatomo-electro-clinical relationship, where an ictal SEEG pattern leads to a specific clinical manifestation. The first clinical application occurred in the Montreal Neurologic Institution in 1972 with the use of SEEG as a localizing tool for refractory focal epilepsy with discordant pre-surgical data.

Its use has since increased, with SEEG often viewed as an extension of the noninvasive presurgical workup, especially when both hemispheres require invasive monitoring. Effective sampling of the cortex by SEEG relies on having a well thought out hypothesis for onset and evolution with clinical semiology, neurophysiology, and neuroimaging and clinical semiology playing pivotal roles. Placement is influenced by the locations of any presumably epileptogenic lesions,

proposed epileptic network, and structural limitations such as cerebral vasculature. It is increasingly common for electrodes to be placed with twist drill holes via robotic assistance with other centers utilizing a conventional stereotactic frame or frameless stereotactic apparatus. Skull thickness should be considered as the bolts used with SEEG placement may not be as secure if skull thickness measures less than 2 to 3 mm. This generally coincides with children below 2 years old, although our institution has successfully implanted children as young as 12 months. When compared with SDE monitoring in adults, SEEG allows for a greater volume of cortical sampling due to the ability for more electrodes to be implanted.<sup>20</sup> The number of simultaneous recorded electrodes may be limited by amplifier space with our institution safely using as many as 39 electrodes without complications. Broad, bilateral coverage may be utilized in cases with highly discordant presurgical data or those with multiple seizure types and a palliative goal in mind.

SEEG may be used to regionalize the onset prior to further localizing with additional SEEG electrodes or SDEs. A major strength is in the ability for SEEG to localize a deeper onset without distorting the tissue or requiring wide exposure (corridor-related morbidity). In this way, anatomic abnormalities such as depth of sulcus dysplasia or periventricular nodular heterotopia may be safely accessed without a large craniotomy. Tissue adjacent to a prior surgical resection site may be better accessed and more safely sampled with SEEG since existing adhesions from prior surgery may complicate the dural reopening necessary for SDE placement. SEEG may also minimize risks for surgical re-evaluation if additional seizure types develop in the future. Following monitoring, limited cellular or core biopsy samples can be obtained from the SEEG electrode trajectory for pathology or research.

SEEG is also particularly useful in cases of “temporal-plus epilepsy” in which mesial temporal sclerosis is suspected to be the cause for seizures but the noninvasive presurgical evaluation may reflect discordant findings.<sup>21,22</sup> This would allow for mesial temporal, lateral temporal, and extratemporal coverage including the anterior cingulate, insular, and orbitofrontal regions. SEEG can also help to differentiate between frontal and temporal lobe onset or left and right temporal epilepsy.<sup>16,23</sup>

Depending on number of electrodes placed, SEEG has been shown to have a comparable or lower risk for hemorrhage, 0.075% to 0.45% per electrode,<sup>24</sup> compared with 4% for subdural grids.<sup>18</sup> Hemorrhage is the most common complication with SEEG electrodes, and infection is significantly lower (1%) than as reported with subdural grid placement (3%<sup>18,24</sup>). While use of more electrodes is associated with modest increase in risk of complications, inadequate coverage can be a major limitation of SEEG as this may lead to an inaccurate identification of the EZ and an unsuccessful surgical plan. Potential safeguards include maximizing the number of SEEG electrodes used or recording concurrent surface EEG data.

## Case Example

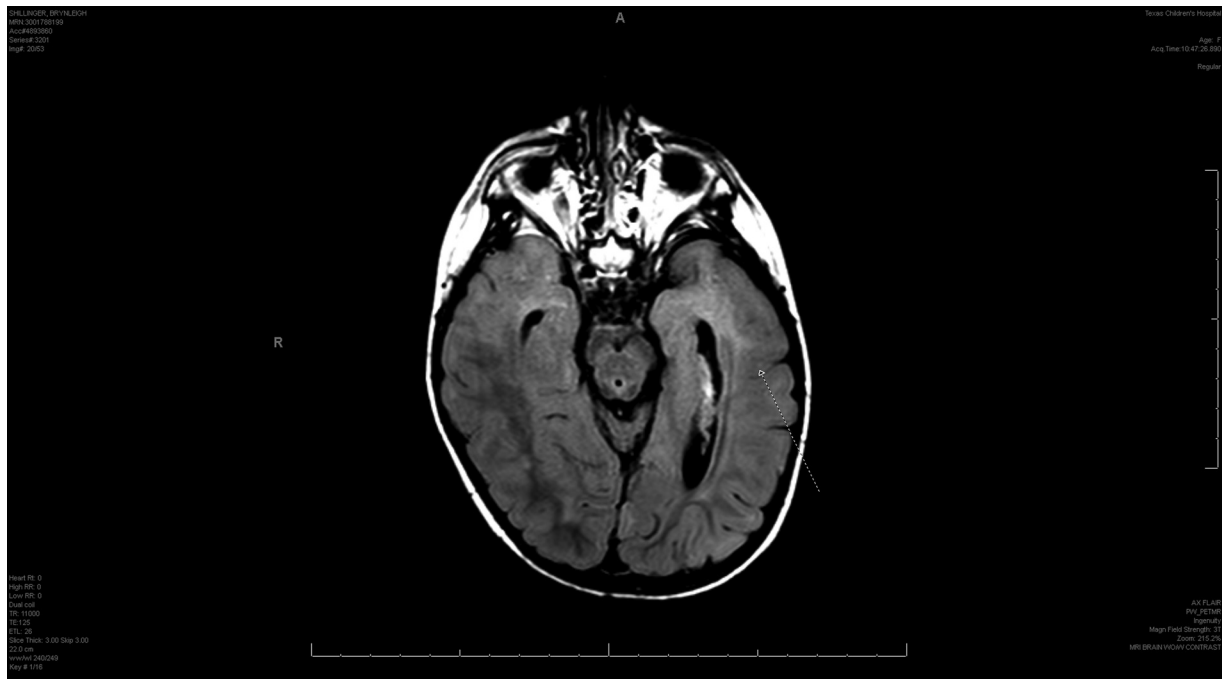
A 2-year-old left-handed girl with *TSC1*-associated refractory epilepsy had focal impaired awareness seizures of a single semiology. Her parents reported a possible aura manifesting as widened eyes and seeking out her parents. Then, she had symmetric bilateral stiffening and clonic movements. Her epilepsy presurgical evaluation implicated multiple areas within the left temporal and frontal regions. Her magnetic resonance imaging (MRI) showed a dysplastic left temporal lobe and malrotated small hippocampus in addition to multiple tubers bilaterally including the left temporal and frontal regions (►Fig. 1). Fluorodeoxyglucose-positron emission tomography showed hypometabolism greatest in the left temporal region but also in the left frontal region (►Fig. 2). Additional data (ictal EEG, magnetoencephalography, AMT [ $\alpha$ -<sup>11</sup>C]-methyl-L-tryptophan) positron emission tomography) supported the need for SEEG coverage of the left frontal and temporal regions (►Fig. 3). Ictal onset was identified in the contacts 1 to 3 of an electrode sampling the left amygdala within a large left temporal tuber complex (►Fig. 4). During the same hospitalization, laser-interstitial thermal therapy (LITT) of the tuber complex was performed under MRI guidance utilizing four trajectories (►Fig. 5). The patient was Engle IA classification at 1 year and Engle 1B at 2 years following surgery.

## Ictal Patterns and Epileptic Networks

Understanding the patterns of ictal onset seen on invasive monitoring may aid in differentiating localized seizure onset from propagated seizure activity. Characterization of SDE monitoring and SEEG has shown similar ictal onset patterns.<sup>25,26</sup> These include:

1. Low-voltage (<30 $\mu$ V) fast activity (>13–14Hz) (LVFA)
2. High-amplitude rhythmic spikes (typically  $\leq$ 3Hz) followed by LVFA
3. High-frequency (>12Hz) polyspikes followed by LVFA
4. Slow wave or baseline shift followed by LVFA
5. High-amplitude  $\alpha$ -theta frequency rhythmic spike activity
6. Moderate-amplitude sinusoidal  $\alpha$ -theta activity with increasing amplitude
7. Moderate-amplitude sinusoidal  $\beta$  activity with increasing amplitude
8. Semi-rhythmic delta activity, can have superimposed low voltage gamma frequency bursts

Seizure onset patterns may be associated with epilepsy etiology with focal cortical dysplasias more commonly associated with polyspikes followed by LVFA. Overall, patterns with LVFA are more common and are associated with better surgical outcomes. Limited data suggests that high-frequency oscillations (80–500 Hz) can be seen near seizure onset in children and, when removed, are associated with better outcomes.<sup>27</sup> Spectral EEG analysis looking for a shift to faster frequencies relative to the time of seizure onset can be used



**Fig. 1** 3 Tesla axial magnetic resonance imaging brain showing bilateral tubers with small, malrotated left hippocampus.

to calculate a brain area’s epileptogenicity index (EI), with higher EI corresponding to areas involved early in seizure.<sup>28</sup> There is ongoing research into using quantified frequency analysis to aid in surgical planning.

In SDE monitoring, localized electrode involvement with slow seizure propagation is associated with better surgical outcomes,<sup>25,29</sup> consistent with the theory of one epileptogenic focus causing a seizure. Similarly in SEEG, involvement of one focal region at seizure onset is associated with better surgical outcome.<sup>26,30</sup> More commonly, however, multiple cortical/subcortical regions are simultaneously involved, termed a “network pattern.” It is hypothesized that within epileptogenic networks, distinct anatomic regions within a physiologic network can develop synchronous fast oscillations leading to seizure. This is challenging for surgical

planning as limited resections within the network may result in incomplete seizure control but broader treatment risks of functional impairment. Spatiotemporal EEG analysis and brain connectivity are being used to better understand epileptogenic networks. The utility of individualized epileptic brain modeling such as the virtual brain is also being investigated.<sup>31</sup>

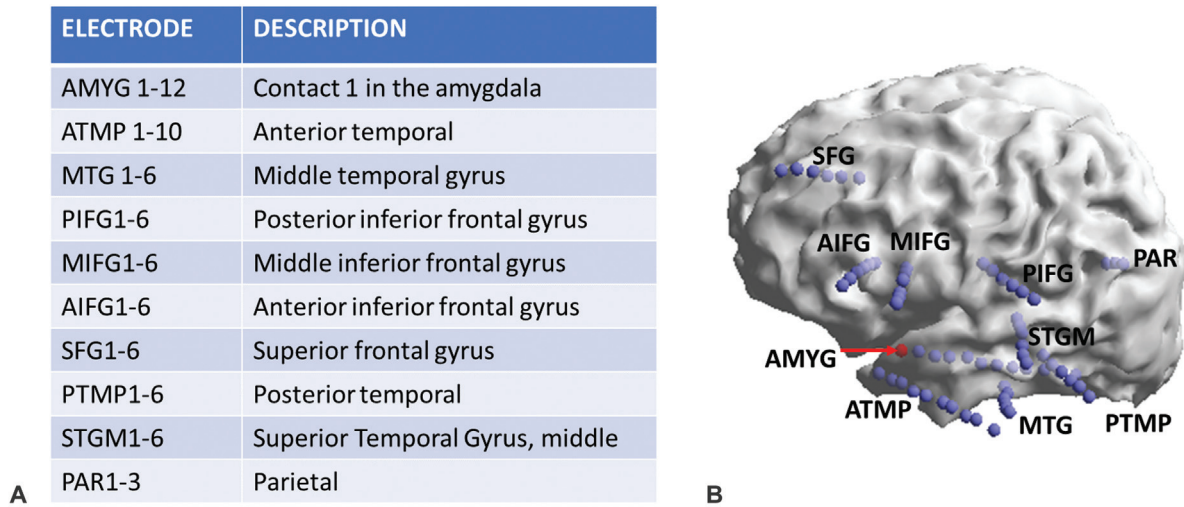
Electrically-induced seizures during invasive monitoring may aid in clarifying the EZ. Stimulation of implanted electrodes that induce the patient’s habitual seizure clinically and electrographically supports a hypothesized EZ.<sup>32</sup> Induction of nonhabitual seizures does not aid in surgical planning. European studies report a 75 to 100% concordance between spontaneous and analogous stimulation-induced seizures with greater concordance seen in mesial temporal lobe epilepsy than lateral temporal or frontal lobe epilepsy.

### Functional Mapping with SEEG

Once the EZ is identified, it must be determined whether the region of interest is eloquent and responsible for functions such as language or motor ability. An understanding of normal brain anatomy may provide some guidance; however, individual variability may be present in the setting of an early ischemic injury or lesion that may disrupt cortical organization. To clarify this, electrical stimulation may be performed intraoperatively or extraoperatively at the bedside with surgically placed electrodes to record any positive (movement of an arm or finger, visual phenomena) or negative signs (pause in speech). By doing so, it may be determined that the proposed EZ contains important language, motor, visual, sensation, or executive brain functions. For some functions, successful functional mapping relies on both the regions sampled and the cooperation and



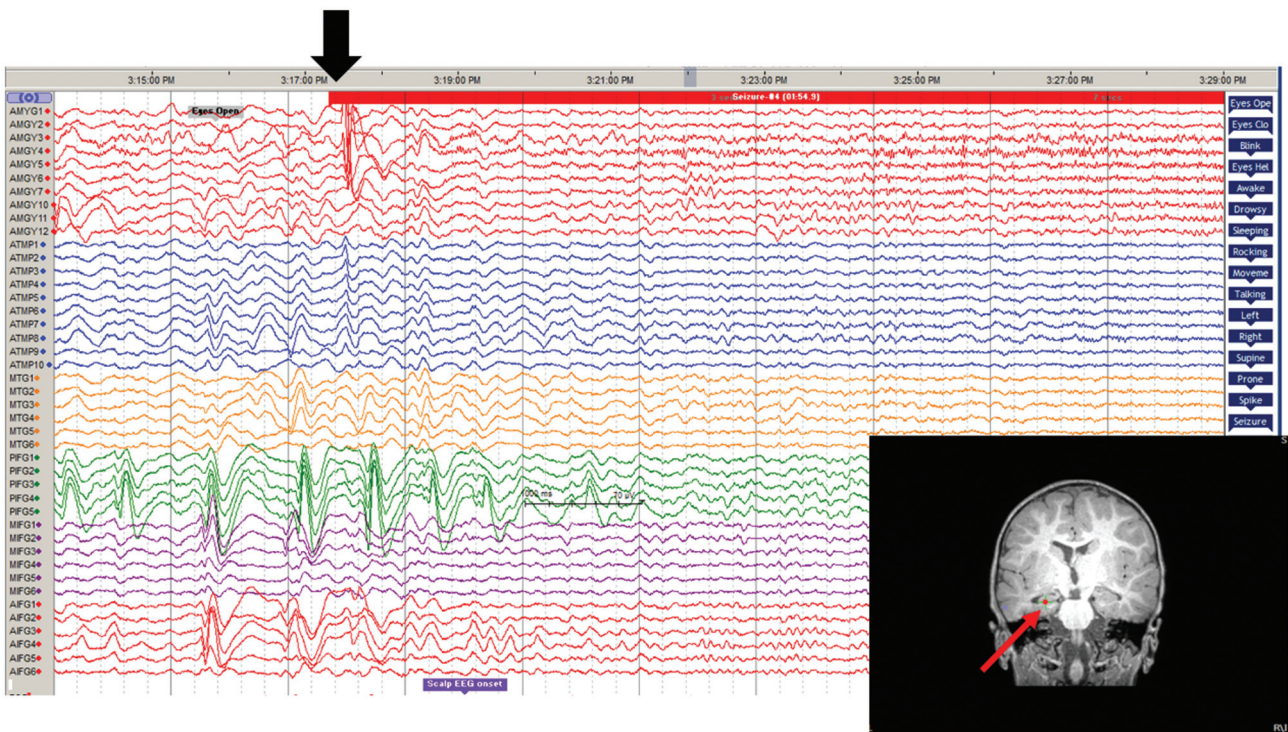
**Fig. 2** Fluorodeoxyglucose-positron emission tomography showing left temporal greater than left frontal hypometabolism.



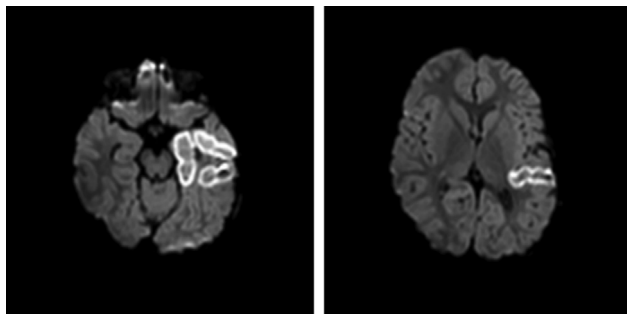
**Fig. 3** List of stereoelectroencephalography electrodes (A) and three-dimensional reconstruction of left temporal and frontal coverage (B).

communication ability of the patient. Motor testing may be done while the patient is asleep or under sedation, but the patient must be awake and alert for language and vision testing. A failure to identify clinical changes during functional mapping does not guarantee nonfunctional tissue as other nontestable functions may exist or an adequate stimulation threshold may not have been reached. Additionally, functions with bilateral representation may not show clinical changes during stimulation due to compensation by the contralateral hemisphere. Stimulus-induced after discharges and seizures are monitored by electrocorticography during the mapping procedure.

There are significant differences between mapping using SEEG electrodes and mapping using SDEs on the cortical surface.<sup>33</sup> Bipolar stimulation of SEEG electrodes targets a relatively small area of cortex as depth electrode contacts are generally 5 mm apart. Due to their cylindrical morphology, however, these electrodes have greater surface area in contact with the brain, so lower maximum stimulation parameters should be used in comparison to SDEs. Due to electrode characteristics, the stimulation field by SEEG is quite focal relative to SDE mapping and negative mapping results should be interpreted with caution. Greater electrode sampling of the region can improve the sensitivity of functional mapping.



**Fig. 4** Ictal onset on stereoelectroencephalography showing a high voltage spike followed by low-frequency fast activity in AMYG3-4.



**Fig. 5** Magnetic resonance imaging (MRI) brain, diffusion-weighted imaging images following MRI-guided stereotactic laser ablation of a large left temporal tuber complex utilizing four trajectories.

Case studies have also demonstrated the utility of quantifying high-frequency activity in the gamma (70–150Hz) range to localize functional regions, such as those that may be implicated in movement of a limb, identifying pictures/naming, auditory perception, and question-answer trials.<sup>34,35</sup> While this technique allows for multiple areas to be assessed simultaneously without an added risk for inducing seizures, the areas showing gamma frequency activity may be larger than corresponding functional areas identified by stimulation of SEEG electrodes. Further study may clarify the utility of this method.

### Surgical Outcomes of Subdural and SEEG Monitoring

There are limited comparative outcome studies of SDE monitoring and SEEG for the pediatric population. One pediatric epilepsy center described 38 patients who underwent invasive monitoring.<sup>36</sup> SEEG patients tended to have more recording electrodes with 36% of their patients having bilateral sampling. Despite this, SEEG patients spent comparatively less time in the operating room and spent less time in the intensive care unit. SEEG was also well tolerated with lower pain scores and less narcotic pain medication use. Both techniques had a similar likelihood of identifying an EZ and following surgery (mostly resection), both groups had favorable Engel I-II outcomes (86.6% for SEEG and 78.6% for SDE). Interestingly, the staged SEEG and surgery (2 admissions) were comparable in cost to a single admission for SDE monitoring and surgery.

Important information can, however, be gleaned from mixed pediatric and adult cohorts. One of the largest cohorts that included international centers analyzed nearly 1,400 patients more than or equal to 16 years old who underwent invasive monitoring.<sup>37</sup> SDE monitoring was associated with a slightly higher likelihood of resection (odds ratio: 1.39) with a more than or equal to 1 year seizure freedom rate of 41%. SEEG followed by resection had similar seizure outcomes (55% seizure freedom). SDE monitoring had higher rates of infection (7 vs. 0.9%), but both techniques had similar rates of symptomatic intracranial hemorrhage and postoperative neurologic deficits.

Another cohort from the ultrasound that included 31 pediatric patients as young as 5 years reported that SDE

monitoring and SEEG showed similar rates of seizure freedom (70 vs. 68%).<sup>38</sup> These authors commented that selecting the most appropriate monitoring modality for the patient contributes to surgical success. In their center, SDE monitoring was considered when the hypothesized EZ lies in the superficial cortex and is close to eloquent cortex, while SEEG was favored if bihemispheric mapping was needed or if the hypothesized EZ was deep, in a region difficult to cover with electrodes, or close to a functional network.<sup>38</sup> Deep structures such as the amygdala–hippocampal complex, insula, and heterotopic gray matter may be more suited to SEEG.<sup>11</sup>

While these studies suggest comparable efficacy between SDE monitoring and SEEG, reported surgical outcomes following SEEG monitoring show significant variability. A meta-analysis of 158 pediatric patients that underwent SEEG reported 54% were seizure free at the last follow-up.<sup>39</sup> A nonlesional MRI was associated with higher likelihood of seizure recurrence. In another cohort of pediatric and adult patients who underwent bilateral SEEG implantation, only 32% were seizure free after 1 year.<sup>40</sup> Eighty percent of those with seizure recurrence did, however, have a more than 50% reduction in seizure burden. Predictors of seizure freedom included single seizure type, short epilepsy duration, and use of less than or equal to 2 antiseizure medications at time of surgery. Further outcomes studies are needed to further delineate favorable prognostic factors as well as definite response to different surgical treatment modalities (e.g., resection, thermocoagulation, and neurostimulation).

### Discussion

When thoughtfully planned and carefully performed, epilepsy surgery offers a higher chance for seizure freedom and improved quality of life than medications alone.<sup>41</sup> As the most common chronically experienced childhood neurologic condition,<sup>42</sup> epilepsy can lead to social stress,<sup>43</sup> cognitive/academic difficulties,<sup>44</sup> injury,<sup>45</sup> and increased risk for death. Many caregivers of children with epilepsy often wish in retrospect that surgery was performed sooner<sup>46,47</sup> as even seizure reduction is associated with improved quality of life.<sup>8</sup> Earlier surgery during a developmental plastic period may also allow for preservation of function such as language re-organization following functional hemispherotomy.<sup>48</sup> Further, developmental potential may be maximized with earlier intervention even in conditions like tuberous sclerosis complex that are predisposed to form new epileptogenic networks over time. Reduction in total number of seizures or complete treatment of the most debilitating seizure type may allow for a reduction in anti-seizure medications and improved side effect burden.

The threshold for epilepsy surgery will lower with increased use of minimally invasive diagnostic and surgical techniques due to the capacity for broad electrophysiologic sampling, better patient tolerability, lower complication rates, and favorable outcomes. In this way, SEEG has played a pivotal role in viewing surgery as a realistic palliative option in patients with complex epilepsy. Individuals previously identified as poor surgical candidates due to numerous

seizure types, discordant presurgical data, genetic etiology, or multiple, disparate potential EZs may now warrant reconsideration for epilepsy surgery. There is also a greater consideration for repeat epilepsy surgery either due to seizure recurrence or the emergence of new seizure types.

If a strong hypothesis can be generated, SEEG implantation and successful identification of the probable EZ offer information on the likelihood of improvement from minimally invasive surgical approaches such as LITT, radio frequency thermocoagulation, or high-intensity-focused ultrasound. Alternatively, craniotomy with tailored resection may be pursued if predicted to be more effective, typically during a separate admission. Despite its many strengths, limitations exist on the ability of SEEG to define the extent of functional regions due to sampling, and most epileptologists continue to rely on SDE monitoring if the EZ is hypothesized to be in close proximity to eloquent cortex.

#### Conflict of Interest

None declared.

#### References

- Kwan P, Brodie MJ. Early identification of refractory epilepsy. *N Engl J Med* 2000;342(05):314–319
- Berg AT, Vickrey BC, Testa FM, et al. How long does it take for epilepsy to become intractable? A prospective investigation. *Ann Neurol* 2006;60(01):73–79
- Fountain NB, Van Ness PC, Swain-Eng R, Tonn S, Bever CT Jr American Academy of Neurology Epilepsy Measure Development Panel and the American Medical Association-Convenced Physician Consortium for Performance Improvement Independent Measure Development Process. Quality improvement in neurology: AAN epilepsy quality measures: Report of the Quality Measurement and Reporting Subcommittee of the American Academy of Neurology. *Neurology* 2011;76(01):94–99
- Blumcke I, Spreafico R, Haaker G, et al; EEBB Consortium. Histopathological Findings in Brain Tissue Obtained during Epilepsy Surgery. *N Engl J Med* 2017;377(17):1648–1656
- Télez-Zenteno JF, Dhar R, Wiebe S. Long-term seizure outcomes following epilepsy surgery: a systematic review and meta-analysis. *Brain* 2005;128(Pt 5):1188–1198
- Englot DJ, Ouyang D, Garcia PA, Barbaro NM, Chang EF. Epilepsy surgery trends in the United States, 1990–2008. *Neurology* 2012;78(16):1200–1206
- Ravindra VM, Sweney MT, Bollo RJ. Recent developments in the surgical management of paediatric epilepsy. *Arch Dis Child* 2017;102(08):760–766
- Matern TS, DeCarlo R, Ciliberto MA, Singh RK. Palliative epilepsy surgery procedures in children. *Semin Pediatr Neurol* 2021;39:100912
- Seto ES, Coorg R. Epilepsy surgery: monitoring and novel surgical techniques. *Neurol Clin* 2021;39(03):723–742
- Jehi L. The epileptogenic zone: concept and definition. *Epilepsy Curr* 2018;18(01):12–16
- Jayakar P, Gotman J, Harvey AS, et al. Diagnostic utility of invasive EEG for epilepsy surgery: indications, modalities, and techniques. *Epilepsia* 2016;57(11):1735–1747
- Lüders HO, Engel J, Munari C. General principles. In: Jerome Engle Jr, ed. *Surgical Treatment of the Epilepsies*. 2nd edition. New York, NY, USA: Raven Press; 1993:137–153
- Lüders HO, Najm I, Nair D, Widdess-Walsh P, Bingman W. The epileptogenic zone: general principles. *Epileptic Disord* 2006;8 (Suppl 2):S1–S9
- Hamer HM, Morris HH, Mascha EJ, et al. Complications of invasive video-EEG monitoring with subdural grid electrodes. *Neurology* 2002;58(01):97–103
- Harroud A, Bouthillier A, Weil AG, Nguyen DK. Temporal lobe epilepsy surgery failures: a review. *Epilepsy Res Treat* 2012;2012:201651. Doi: 10.1155/2012/201651
- Perven G, Podkorytova I, Ding K, et al. Non-lesional mesial temporal lobe epilepsy requires bilateral invasive evaluation. *Epilepsy Behav Rep* 2021;15:100441. Doi: 10.1016/j.ebr.2021.100441
- Fountas KN, King DW, Jenkins PD, Smith JR. Nonhabitual seizures in patients with implanted subdural electrodes. *Stereotact Funct Neurosurg* 2004;82(04):165–168
- Arya R, Mangano FT, Horn PS, Holland KD, Rose DF, Glauser TA. Adverse events related to extraoperative invasive EEG monitoring with subdural grid electrodes: a systematic review and meta-analysis. *Epilepsia* 2013;54(05):828–839
- Talairach J, Bancaud J. Lesion, “irritative” zone and epileptogenic focus. *Confin Neurol* 1966;27(01):91–94
- Tantawi M, Miao J, Matias C, et al. Gray matter sampling differences between subdural electrodes and stereoelectroencephalography electrodes. *Front Neurol* 2021;12:669406. Doi: 10.3389/fneur.2021.669406
- Kalamangalam GP, Tandon N. Stereo-EEG implantation strategy. *J Clin Neurophysiol* 2016;33(06):483–489
- Kahane P, Barba C, Rheims S, Job-Chapron AS, Minotti L, Ryvlin P. The concept of temporal ‘plus’ epilepsy. *Rev Neurol (Paris)* 2015;171(03):267–272
- Olivier A, Boling WW, Tanriverdi T. Techniques in epilepsy surgery: the MNI approach. Cambridge medicine. New York, NY, USA: Cambridge University Press; 2012
- Ostergard T, Miller JP. Depth electrodes: Approaches and complications. In: Lhatoo SD, Kahane P, Lüders HO, eds. *Invasive Studies of the Human Epileptic Brain*. New York, NY, USA: Oxford University Press; 2019:50–64
- Lee SA, Spencer DD, Spencer SS. Intracranial EEG seizure-onset patterns in neocortical epilepsy. *Epilepsia* 2000;41(03):297–307
- Lagarde S, Buzori S, Trebuchon A, et al. The repertoire of seizure onset patterns in human focal epilepsies: determinants and prognostic values. *Epilepsia* 2019;60(01):85–95
- Ochi A, Otsubo H, Donner EJ, et al. Dynamic changes of ictal high-frequency oscillations in neocortical epilepsy: using multiple band frequency analysis. *Epilepsia* 2007;48(02):286–296
- Bartolomei F, Chauvel P, Wendling F. Epileptogenicity of brain structures in human temporal lobe epilepsy: a quantified study from intracerebral EEG. *Brain* 2008;131(Pt 7):1818–1830
- Kim DW, Kim HK, Lee SK, Chu K, Chung CK. Extent of neocortical resection and surgical outcome of epilepsy: intracranial EEG analysis. *Epilepsia* 2010;51(06):1010–1017
- Bartolomei F, Lagarde S, Wendling F, et al. Defining epileptogenic networks: contribution of SEEG and signal analysis. *Epilepsia* 2017;58(07):1131–1147
- Hashemi M, Vattikonda AN, Sip V, et al. The Bayesian Virtual Epileptic Patient: a probabilistic framework designed to infer the spatial map of epileptogenicity in a personalized large-scale brain model of epilepsy spread. *Neuroimage* 2020;217:116839
- Kovac S, Kahane P, Diehl B. Seizures induced by direct electrical cortical stimulation—mechanisms and clinical considerations. *Clin Neurophysiol* 2016;127(01):31–39
- Ritaccio AL, Brunner P, Schalk G. Electrical stimulation mapping of the brain: basic principles and emerging alternatives. *J Clin Neurophysiol* 2018;35(02):86–97
- Sinai A, Bowers CW, Crainiceanu CM, et al. Electrographic high gamma activity versus electrical cortical stimulation mapping of naming. *Brain* 2005;128(Pt 7):1556–1570
- Brown EC, Rothermel R, Nishida M, et al. In vivo animation of auditory-language-induced gamma-oscillations in children with intractable focal epilepsy. *Neuroimage* 2008;41(03):1120–1131

- 36 Kim LH, Parker JJ, Ho AL, et al. Postoperative outcomes following pediatric intracranial electrode monitoring: a case for stereo-electroencephalography (SEEG). *Epilepsy Behav* 2020;104(Pt A):106905
- 37 Jehi L, Morita-Sherman M, Love TE, et al. Comparative effectiveness of stereotactic electroencephalography versus subdural grids in epilepsy surgery. *Ann Neurol* 2021;90(06):927–939
- 38 Mullin JP, Shriver M, Alomar S, et al. Is SEEG safe? A systematic review and meta-analysis of stereo-electroencephalography-related complications. *Epilepsia* 2016;57(03):386–401
- 39 Kim W, Shen MY, Provenzano FA, et al. The role of stereo-electroencephalography to localize the epileptogenic zone in children with nonlesional brain magnetic resonance imaging. *Epilepsy Res* 2021;179:106828. Doi: 10.1016/j.epilepsyres.2021.106828
- 40 Steriade C, Martins W, Bulacio J, et al. Localization yield and seizure outcome in patients undergoing bilateral SEEG exploration. *Epilepsia* 2019;60(01):107–120
- 41 Dwivedi R, Ramanujam B, Chandra PS, et al. Surgery for drug-resistant epilepsy in children. *N Engl J Med* 2017;377(17):1639–1647
- 42 Aaberg KM, Gunnes N, Bakken IJ, et al. Incidence and prevalence of childhood epilepsy: a nationwide cohort study. *Pediatrics* 2017;139(05):x
- 43 WHO | Epilepsy: a public health imperative *WHO*. 2019–06–20 15:12:23 2019;doi:/entity/mental\_health/neurology/epilepsy/report\_2019/en/index.html
- 44 Mitchell WG, Chavez JM, Lee H, Guzman BL. Academic underachievement in children with epilepsy. *J Child Neurol* 1991;6(01):65–72
- 45 Mahler B, Carlsson S, Andersson T, Tomson T. Risk for injuries and accidents in epilepsy: a prospective population-based cohort study. *Neurology* 2018;90(09):e779–e789
- 46 Nguyen T, Porter BE. Caregivers' impression of epilepsy surgery in patients with tuberous sclerosis complex. *Epilepsy Behav* 2020;111:107331
- 47 Shen A, Quaid KT, Porter BE. Delay in pediatric epilepsy surgery: a caregiver's perspective. *Epilepsy Behav* 2018;78:175–178
- 48 Gott PS. Cognitive abilities following right and left hemispherectomy. *Cortex* 1973;9(03):266–274