

# A Case Report of Two Bahraini Siblings Presenting with Different Rare Neurogenetic Disorders: Congenital Insensitivity to Pain with Anhidrosis and Rigid Spine Muscular Dystrophy

Suha Ahmed<sup>1</sup> Husain Malalla<sup>2</sup> Mariam Busehail<sup>2</sup>

<sup>1</sup>Arabian Gulf University, Manama, Bahrain

<sup>2</sup>Pediatric Department, Salmaniya Medical Complex, Manama, Bahrain

Address for correspondence Husain Malalla, MBBS, ABP, MRCPCH, Pediatric Department, Salmaniya Medical Complex, Manama, Kingdom of Bahrain, Bahrain (e-mail: hmalalla@hotmail.com).

J Pediatr Neurol 2022;20:433–436.

## Abstract

Congenital insensitivity to pain and anhidrosis (CIPA) is a rare autosomal recessive disease and can pose a diagnostic challenge, as the initial presentation of the disease is varied and can be attributed to different causes. Muscular dystrophies are genetically and clinically heterogeneous. We describe a 2-year-old Bahraini boy who was evaluated in the neonatal period for pyrexia of unknown origin, and then noticed to have recurrent respiratory and gastrointestinal infections during infancy and abnormal behavior (self-mutilation). Whole-exome sequencing identified homozygous pathogenic variant in the *NTRK1* gene. His 4 years old sister was followed by the pediatric neurology team for unexplained fluctuating muscle weakness since the age of 2 years. A genetic etiology was suspected in her case, in view of positive family history with similar presentation and the whole-exome sequencing revealed homozygous likely pathogenic variant in the *SELENON* gene, consistent with a genetic diagnosis of autosomal recessive disorders associated with *SELENON* gene.

## Keywords

- ▶ congenital insensitivity to pain with anhidrosis
- ▶ CIPA
- ▶ *NTRK1* gene
- ▶ rigid spine
- ▶ muscular dystrophy
- ▶ RSMD1

## Introduction

Hereditary sensory and autonomic neuropathy type IV (HSAN IV), also known as congenital insensitivity to pain with anhidrosis (CIPA), is an autosomal recessive inherited disorder characterized by insensitivity to painful stimuli, high fevers (due to anhidrosis), and intellectual disability.<sup>1</sup>

Mutations in the neurotrophic tyrosine kinase 1 (*NTRK1*) gene have been implicated in the pathogenesis of CIPA, leading to a partial or complete absence of small myelinated and unmyelinated nerve fibers.<sup>2</sup> Insensitivity to pain usually presents in infancy as self-mutilative behavior, and recurrent injuries. Management is largely supportive.

Congenital muscular dystrophy (CMD) with rigid-spine type 1 (RSMD1) is an autosomal recessive subtype of CMDs associated with mutations of the *SELENON* gene. Affected

individuals usually present in infancy or early childhood with hypotonia and weakness, along with scoliosis and spinal rigidity.<sup>3</sup> Respiratory complications are a major cause of mortality in affected individuals.<sup>4</sup> However, there are no reported associations between CIPA and RSMD1. We describe two biological siblings with two different rare inherited genetic disorders, the older one diagnosed with RSMD1 and the younger with CIPA. This is the first report to describe these conditions in the Kingdom of Bahrain.

## The Cases

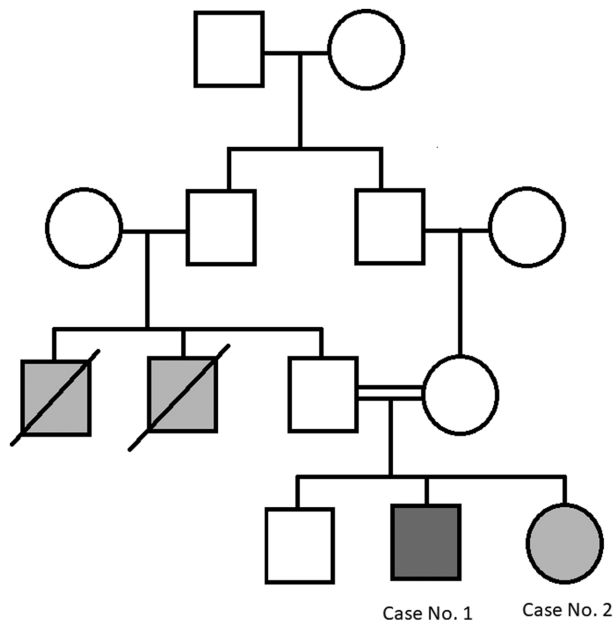
### Case No. 1

Our first patient is a 2-year-old Bahraini male child who born to a full-term spontaneous vaginal delivery with no perinatal complications. The child's weight at birth was 2.5 kg. His

received  
September 21, 2021  
accepted  
February 24, 2022  
published online  
May 6, 2022

© 2022, Thieme. All rights reserved.  
Georg Thieme Verlag KG,  
Rüdigerstraße 14,  
70469 Stuttgart, Germany

DOI <https://doi.org/10.1055/s-0042-1745809>  
ISSN 1304-2580.



**Fig. 1** Pedigree.

parents are first-degree cousins. The family history is notable for two paternal uncles with an undiagnosed disorder with progressive muscular weakness and death at a young age (→**Fig. 1**) and a paternal aunt with muscle weakness.

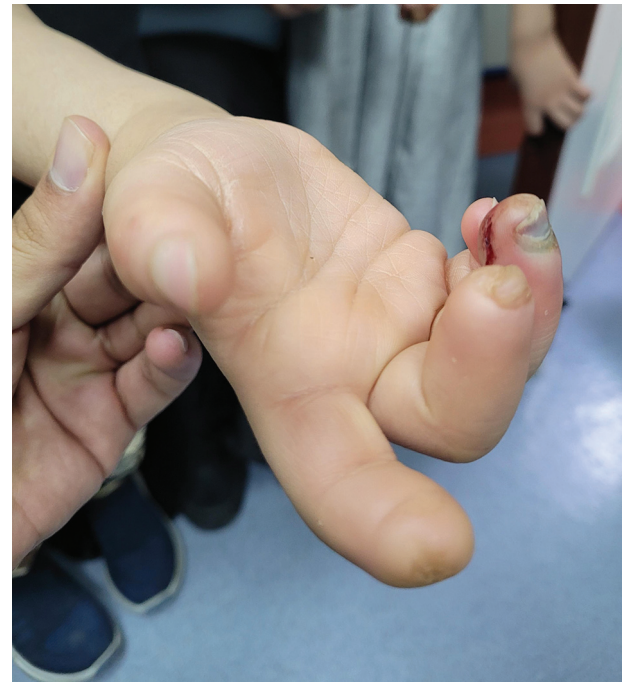At the age of 9 days, he presented with a history of fever. He was hospitalized and evaluated for infectious causes with no foci identified. He was kept on antibiotics for 5 days and later discharged home. However, he experienced a second episode of unexplained high-grade fever within the neonatal period that was resolved in 5 days. Sepsis work-ups, this time, including cultures, were all unremarkable.

In the first year of life, patient had recurrent hospitalizations for diarrhea and was diagnosed with cow's milk protein allergy. He often experienced dry skin and pruritic rash markedly on the face and lower limbs. He was also hospitalized at 16 months of age with right knee swelling and right foot cellulitis. During a routine outpatient visit, he was noticed to have axial and appendicular hypotonia and was referred to neurology clinic for further investigation.

Neurological assessment at the age of 2 years revealed global developmental delay. He could sit without support but could not stand independently. He could speak only few words but could not form two-word sentences. He was also noticed to have marked irritability, and self-mutilative behavior. He had unexplained and unprovoked face striking with his arms, as well as head, banging at the wall.

Clinical examination showed an active and alert child without dysmorphic features. Growth parameters showed a head circumference at the 3rd percentile at birth, and below the 3rd percentile at 12 (41 cm) and 18 months (43 cm). His height and weight are within normal limits, with height tracking consistently along the 75th percentile. His weight tracked along the 25th percentile from birth to 15 months, and was at the 50th percentile at 18 months of age.

He had multiple scratch marks on his body, a large bleeding mouth ulcer, and several small ulcers on his fingers.



**Fig. 2** Auto amputated fingers.

He had no organomegaly. Neurological examination showed full extraocular movements, reactive pupils, and intact cranial nerves. There were no focal neurological deficits. Tone was reduced while power were normal.

Initially, Lesch–Nyhan syndrome was suspected due to self-mutilative behavior, but he had a normal uric acid level. Hearing assessment, thyroid function test, fragile x-test, lactic acid, and ammonia levels were unremarkable. Celiac disease screening was negative. Tandem mass spectrometry was not suggestive of any metabolic disorders. Nerve conduction studies were not performed due to the expected difficulty in a child with developmental delay.

A whole-exome sequencing was performed after obtaining consent from the parents. Testing identified homozygous pathogenic (the American College of Medical Genetics and Genomics [ACMG] class 5) variant c.1524\_1531dup; p.(Val511Glyfs\*39) in the *NTRK1* gene, diagnostic of autosomal recessive sensory and autonomic neuropathy type IV (HSAN IV; OMIM no.: 191315).

At the recent follow-up, the patient was still suffering from self-mutilation, causing disfigured fingers (→**Fig. 2**) and a large mouth ulcer. Motor development appeared to be improving (he was able to walk and run) currently walks and runs.

#### Case No. 2

The elder sister of our case 1 is a 4-year-old Bahraini female, born at 37 weeks of gestation after an uncomplicated pregnancy and a spontaneous vaginal delivery.

The patient was brought to the pediatric clinic at 2.5 years of age when her parents noticed that she had difficulty standing up from a seated position. The child had previously been able to stand with ease, but was gradually experiencing lower limb weakness most notable when waking up in the

morning. The mother noticed that the child would hold on to objects for support when attempting to stand up. The child was previously healthy. Growth was normal, and the child met appropriate speech and social development milestones. At presentation, she was able to speak in sentences, alternate feet down stairs, walk up, and down stairs but could not ride a tricycle or hop on one foot.

Clinical examination showed an alert, active child. No apparent dysmorphic features noted. She had normal growth parameters. She displayed a mask-like face with no clear expressions. Chest auscultation revealed no added sounds. Her abdomen was soft with no organomegaly. Neurological examination showed both axial hypotonia and appendicular hypotonia. She was noted to have weakness (four-fifths power in all four extremities) and positive Gowers' sign. No atrophy or pseudohypertrophy noted. Deep tendon reflexes were normal.

Laboratory investigations showed normal creatinine kinase levels and low vitamin D levels (19 nmol/L). Nerve conduction studies and muscle biopsy were not performed.

Whole-exome sequencing was performed after obtaining consent from the parents.

Whole-exome sequencing revealed homozygous likely pathogenic (ACMG class 4) variant c.1443del p.(Leu482Serfs\*) in the *SELENON* gene. It was consistent with a diagnosis of autosomal recessive muscular dystrophy rigid-spine type 1 (OMIM no.: 602771).

At the most recent follow-up, she was noted to have weakness, continued to walk independently, and attended school where her social and speech development remain unaffected.

## Discussion

### Case No. 1

The *NTRK1* variant c.1524\_1531dup p.(Val511Glyfs\*39) creates a shift in the reading frame starting at codon 511. The new reading frame ends in a stop codon 39 position downstream. This variant has been confirmed by Sanger's sequencing.

While the worldwide prevalence of CIPA remains unknown, reports demonstrate that 50% of cases are associated with consanguinity.<sup>5</sup> Although expression is variable, CIPA shows 100% penetrance.<sup>5</sup> Physical examination usually demonstrates loss of pain and temperature sensation with preserved proprioception, light touch, and preserved deep tendon reflexes.<sup>6</sup> Anhidrosis is secondary to the absence of small nerve fibers in sweat glands as evidenced in skin biopsies.<sup>2</sup> Anhidrosis leads to recurrent unexplained fevers, febrile seizures, and excessive dryness of the skin. The diagnosis of CIPA is usually clinical and is confirmed using genetic testing. Specific DNA tests are of limited value due to the large size of the *NTRK1* gene, as well as other genetic mutations associated with CIPA. Management is largely supportive, and consists of minimizing injury, possible surgical correction of orthopaedic deformities, as well as hyperthermia management.

This case study is the first of congenital insensitivity to pain and anhidrosis in the Bahraini population. Additionally, rigid-type spinal muscular dystrophy RSMD1 has not been

previously reported in Bahrain. This is also the first report worldwide of these two seemingly unrelated genetic conditions being inherited in the same family. Although this could be an incidental finding, it is worth considering the possibility of an association between RSMD1 and CIPA.

While CIPA is most commonly associated with the clinical presentation of anhidrosis, insensitivity to pain and heat intolerance, other symptoms have been frequently associated with the disease. Features, such as developmental delay, intellectual disability, and self-mutilative behavior,<sup>7</sup> are known features of CIPA and were prominent features of this patient's clinical presentation. In addition, microcephaly in our patient is likely related to CIPA. There is a previously reported case in Pakistan with CIPA and microcephaly.<sup>8</sup> Further, genetic testing did not reveal other variants that would explain microcephaly.

Our patient exhibited some features suggesting immune deficiency. There are patients reported in the literature with CIPA and immune compromise characterized by recurrent infections and decreased proliferative response of mononuclear cells in the peripheral blood after exposure to stimuli (PHA, Con-A, and CD 3 X-L).<sup>9</sup>

### Case No. 2

CMDs are a heterogenous group of inherited disorders characterized by hypotonia, muscle weakness, and subsequent respiratory failure.<sup>5</sup> Several congenital muscular dystrophies have been described, each with characteristic phenotypes and associated genotypes. CMD dystrophy with RSMD1 is an autosomal recessive subtype of CMDs, associated with mutations of the *SELENON* gene. While the presence of spinal rigidity is not unique to RSMD1, it presents earlier than in other muscular dystrophies. RSMD1 can also be inherited in an autosomal dominant pattern.

The *SELENON* variant (NM\_020451.3):c.1443del p.(Leu482Serfs\*) creates a shift in the reading frame starting at codon 482 with unknown location of the terminating stop codon. This variant has been confirmed by Sanger's sequencing.

The *SELENON* gene (also called *SEPN1*) is crucial for the production of selenoprotein N that is involved in many functions within the body. More than a dozen *SELENON* gene mutations have been found to cause rigid spine muscular dystrophy 1 (RSMD1)

Respiratory complications are a major cause of mortality in affected individuals.<sup>10</sup> Noury et al reported a case with rigid-spine syndrome, as well as hereditary sensory, and motor neuropathy (Charot-Marie-Tooth syndrome).<sup>11</sup> The clinical presentation of weakness and a positive Gower's sign in a child with a positive family history was strongly suggestive of a congenital myopathy. However, signs suggesting RSMD1 in particular, such as hypotonia at birth, scoliosis, and early spinal involvement, were not exhibited in this patient.

Both case studies were limited by several factors. First, a detailed family history, especially pertaining to the children's paternal uncles could not be obtained. Second, the child's severe irritability and autistic features limited both the physical examination, as well as the diagnostic work up. Ideally, a nerve conduction study should have been

conducted, although a normal result is expected in patients with CIPA. Muscle biopsy was also deferred. Genetic testing for both parents to confirm their carrier status is also planned to be performed.

## Conclusion

Early diagnosis of CIPA may be aided by having a high index of suspicion in children presenting with more than one episode of pyrexia of unknown origin as neonates and infants. In addition, recurrent infections due to a possible underlying immunodeficiency could be the primary manifestation in patients with CIPA; thus, we recommend considering CIPA as a possible etiology of immunodeficiency in a patient with a personal or family history of neurological disease.

### Conflict of Interest

None declared.

## References

- Orphanet: The portal for rare diseases and orphan drugs. Accessed February 10, 2021 at: [https://www.orpha.net/consor/cgi-bin/Disease\\_Search.php?lng=EN&data\\_id=935&Disease\\_Disease\\_Search\\_disease\\_Type=ORPHA&Disease\\_Disease\\_Search\\_diseaseGroup=642&Disease\(s\)/group%20of%20diseases=Insensitivity-to-pain-anhidrosis&title=Insensitivity-to-pain-anhidrosis&search=Disease\\_Search\\_Simple](https://www.orpha.net/consor/cgi-bin/Disease_Search.php?lng=EN&data_id=935&Disease_Disease_Search_disease_Type=ORPHA&Disease_Disease_Search_diseaseGroup=642&Disease(s)/group%20of%20diseases=Insensitivity-to-pain-anhidrosis&title=Insensitivity-to-pain-anhidrosis&search=Disease_Search_Simple)
- Axelrod FB. Hereditary sensory and autonomic neuropathies. Familial dysautonomia and other HSANs. *Clin Auton Res* 2002; 12(Suppl 1):I2–I14
- Flanigan KM, Kerr L, Bromberg MB, et al. Congenital muscular dystrophy with rigid spine syndrome: a clinical, pathological, radiological, and genetic study. *Ann Neurol* 2000;47(02):152–161
- Morita H, Kondo K, Hoshino K, Maruyama K, Yanagisawa N. Rigid spine syndrome with respiratory failure. *J Neurol Neurosurg Psychiatry* 1990;53(09):782–784
- Bonkowsky JL, Johnson J, Carey JC, Smith AG, Swoboda KJ. An infant with primary tooth loss and palmar hyperkeratosis: a novel mutation in the NTRK1 gene causing congenital insensitivity to pain with anhidrosis. *Pediatrics* 2003;112(3 Pt 1):e237–e241
- Durham PL. Calcitonin gene-related peptide (CGRP) and migraine. *Headache* 2006;46(Suppl 1):S3–S8
- Indo Y, Mardy S, Miura Y, et al. Congenital insensitivity to pain with anhidrosis (CIPA): novel mutations of the TRKA (NTRK1) gene, a putative uniparental disomy, and a linkage of the mutant TRKA and PKLR genes in a family with CIPA and pyruvate kinase deficiency. *Hum Mutat* 2001;18(04):308–318
- Mardy S, Miura Y, Endo F, et al. Congenital insensitivity to pain with anhidrosis: novel mutations in the TRKA (NTRK1) gene encoding a high-affinity receptor for nerve growth factor. *Am J Hum Genet* 1999;64(06):1570–1579
- Sawal HA, Ullah MI, Ahmad A, et al. Homozygous mutations in NTRK1 gene underlie congenital insensitivity to pain with anhidrosis in Pakistani families. *Neurol Asia* 2016;21(02):
- Scoto M, Cirak S, Mein R, et al. SEPN1-related myopathies: clinical course in a large cohort of patients. *Neurology* 2011;76(24):2073–2078
- Noury J-B, Maisonobe T, Richard P, Delague V, Malfatti E, Stojkovic T. Rigid spine syndrome associated with sensory-motor axonal neuropathy resembling Charcot-Marie-Tooth disease is characteristic of Bcl-2-associated athanogene-3 gene mutations even without cardiac involvement. *Muscle Nerve* 2018;57(02): 330–334