

# Anesthesia Risk and the Mucopolysaccharidoses: A Challenging and Changing Landscape

Robert W. M. Walker<sup>1</sup> James Garbarino<sup>2</sup>

<sup>1</sup>Department of Pediatric Anesthesia, Royal Manchester Children's Hospital, Manchester, United Kingdom

<sup>2</sup>Department of Anesthesia, Royal Manchester Children's Hospital, Manchester, United Kingdom

Address for correspondence Robert W. M. Walker, MBChB, FRCA, Consultant in Pediatric Anesthesia, Royal Manchester Children's Hospital, Oxford Road, Manchester M13, United Kingdom (e-mail: Robert.walker@cmft.nhs.uk).

J Child Sci 2018;8:e116–e123.

## Abstract

The mucopolysaccharidoses (MPS) are well known to present a high risk of anesthesia. Predominantly, this risk is not only related to upper airway issues but also to multilevel airway obstruction, respiratory morbidity, and cardiac issues. Before disease-specific treatment became available, the management of the untreated patients with MPS was regarded as the worst airway problem in pediatric anesthetic practice. The last 20 to 30 years have seen great advances in the treatment of the different types of MPS with hematopoietic stem cell transplantation (HSCT) being offered to children with MPS I Hurler syndrome since the 1980s, and more recently enzyme replacement therapy (ERT) becoming available for many MPS subtypes.

These treatments have undoubtedly affected the relative risk involved with an anesthetic. HSCT improves markedly the upper airway and cardiac myocardial function and there is evidence that airway management is much more straightforward. ERT, on the other hand, improves obstructive sleep apnea and exercise tolerance, but the overall effect on the risk of anesthesia is less obvious and airway complications during anesthesia remain at a high level. The impact of improved anesthetic management in the same time frame is borne out by a reduced failed intubation rate in the literature. The management of the MPS patients necessitates a multidisciplinary approach presently widely practiced in pediatric centers, but successful modes of therapy increasing their life span have pushed many of the extreme anesthetic challenges into adult practice where most anesthesiologists will be unfamiliar with the problem. This is a problem that needs to be addressed, and solutions to this issue could be collaborative working between pediatric and adult practitioners or an international network of experts available for advice.

## Keywords

- ▶ anesthesia
- ▶ mucopolysaccharidosis
- ▶ airway management

## Introduction

The mucopolysaccharidoses (MPS) are a group of rare inherited metabolic conditions that are well known to be associated with greater anesthetic risk. In Smith's pediatric anesthetic textbook, "Anesthesia for infants and children" published in 1980,

Hurler's syndrome is described as "the worst airway problem in pediatric anesthesia."<sup>1</sup> This statement referred to the child with the severe form of MPS I before causal therapy in the form of bone marrow transplantation (BMT) became available.

The first reports of anesthesia disasters come from DeLange et al in an article entitled, "Some remarks on

received  
October 13, 2017  
accepted after revision  
April 18, 2018

Issue Theme Advances in  
Mucopolysaccharidoses; Guest  
Editors: Susanne G. Kircher, MD,  
PhD, MBA, Adriana M. Montañó,  
PhD, and Christina Lampe, MD.

Copyright © 2018 Georg Thieme Verlag  
KG Stuttgart · New York

License terms



DOI <https://doi.org/10.1055/s-0038-1667349>.  
ISSN 2474-5871.

gargoylism," published in 1943 to 1944.<sup>2</sup> In this article, the authors describe a patient with gargoylism in the teenage years who died following bronchoscopy. Two cases of adult MPS II patients are presented in the *British Journal of Oral Surgery* in 1973.<sup>3</sup> The first was a 20-year-old man with Hunter's syndrome. He was of normal intelligence and worked as a lorry driver but complained of limited mouth opening and pain in the temporomandibular joint. He was scheduled for bilateral coronoidectomy and removal of teeth. On the first occasion, his airway was secured by blind nasal endotracheal intubation. The operation, however, was not possible because of limited access and was abandoned. On the second occasion, airway management was more problematic but eventually successful and the operation performed using a different external approach. However, after initially recovering well, he developed respiratory distress and required an urgent tracheostomy. Unfortunately, he suffered a cardiac arrest during the difficult tracheostomy and could not be resuscitated.

During the following 20 years, there are many reports of both cases and case series highlighting the high risk of anesthesia in this group of patients.<sup>4-10</sup> This group of case series from around different parts of the world generally tells the same story at a time when causal therapy was not available. There was a high reported incidence of airway-related complications, difficult endotracheal intubation, failed intubation, failure to ventilate (can't intubate, can't ventilate situation), and emergency unexpected tracheostomy. Kempthorne and Brown from Melbourne Children's reported 13 out of 20 general anesthetics to be associated with difficult airway management and among that group were two failed intubations and a hypoxic arrest in a 2-year-old with MPS I.<sup>5</sup> The case series through the 1980s and 1990s generally report a similarly high difficult intubation rate of ~50% in MPS I, II and often higher in MPS VI.<sup>10</sup> In a series from our own center, we reported an overall incidence of difficult intubation of 25% in a mixed group of MPS patients but in the MPS I patients, there was a difficult intubation rate of 54% and a failed intubation rate of 23%.<sup>9</sup> All of these papers cite serious airway complications such as complete airway obstruction during induction of anesthesia, severe hypoxia with cardiac arrest, difficult intubation, failure to intubate, and indeed of postobstructive pulmonary edema and emergency tracheostomy.

The MPS I registry comprising of over 900 patients reports a 30-day risk of mortality/procedure of 0.7% and of death/patient of 4.2%.<sup>11</sup> To compare these numbers, the 30-day mortality of other high-risk groups is quoted as follows: the morbidly obese 30-day mortality after surgery is 1.7%, in patients having cardiac surgery the rate is 3.6%, and in those patients undergoing colorectal surgery the rate is quoted at 6.7%.<sup>12</sup> This shows the MPS patient to be in a very high-risk group. The deaths in the registry figures encompass those patients undergoing BMT or hematopoietic stem cell transplantation (HSCT), and therefore, reflect mortality both before causal treatment has been introduced and after. The deaths are due to two main causes. In those BMT patients, the cause of death was sepsis or secondary to the transplant

process, and in the other group, the cause was essentially airway related. These included older patients undergoing major surgery such as spinal or cardiac surgery.

## Pathophysiology and Anesthetic Risk Factors

As clearly stated in other articles in this issue, the MPS are a group of disorders caused by an inherited lack of a lysosomal enzyme. This resultant accumulation of glycosaminoglycans (GAGs) within the lysosomes causes cellular swelling and cellular dysfunction. The accumulation of GAGs within tissues and organs results in the clinical manifestations which are dependent on the particular enzyme deficiency. The particular set of clinical manifestations will vary to a degree between different categories of MPS and also to some extent within the same disorder. However, in broad terms, the clinical manifestations causing additional anesthetic risk are shared throughout the groups. These include anomalies of the upper and lower airway, cardiac, respiratory, and skeletal abnormalities. In the untreated condition, these features progress with age and therefore, anesthetic risk in the untreated condition will also progress.<sup>13</sup>

On account of the clinical manifestations, patients with an MPS disorder often require surgery for a variety of reasons. The MPS I registry reports that 75% of patients required one procedure and that most patients required three to four procedures.<sup>11</sup> There was a similar theme in the Hunter Outcome Survey with over 80% of patients requiring surgical intervention or investigative procedures such as magnetic resonance imaging and this number could easily climb to 100% should causal treatment be available in all groups.<sup>14</sup>

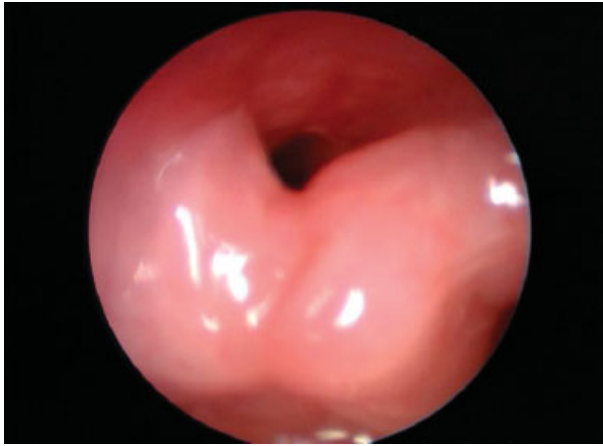
## Specific Risk factors

Typical features that are common among most types of MPS are coarse facial features, reduced height, skeletal anomalies, cardiovascular disease, hepatosplenomegaly, vision, and hearing problems. Of particular relevance to the anesthetist are airway, respiratory, cardiovascular, and spinal cord problems.

### Airway Related

Airway issues in MPS conditions can be multilevel and are present to a significant degree in most conditions but to a lesser degree in MPS III.<sup>15</sup> The upper airway is affected by GAG deposition in the nose, mouth, and pharynx.<sup>16</sup> This causes macroglossia, thickened nasal mucosa, gingival hypertrophy, and adenotonsillar hypertrophy. Chronic infection and thick secretions compound the obstruction.<sup>17</sup> In more advanced cases, GAG deposition in and around the glottis causes an excess of tissue in the arytenoids and aryepiglottic folds causing prolapsing tissue during inspiration with resultant stridorous breathing and hoarseness (→ **Figs. 1-2**).<sup>18</sup> Mouth opening may also be limited.

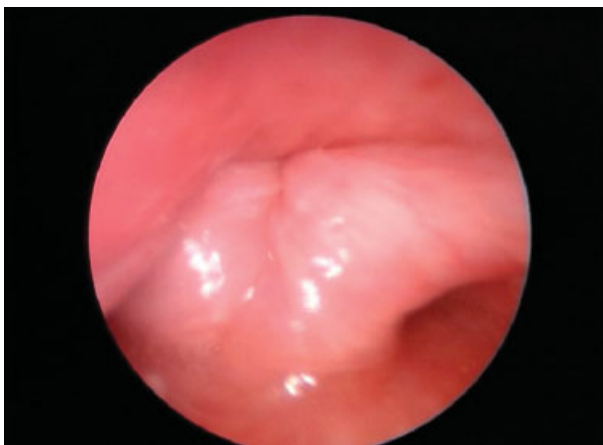Many of the MPS conditions also develop airway abnormalities in the trachea and lower airways. Tracheobronchomalacia has been described in most of the conditions but is



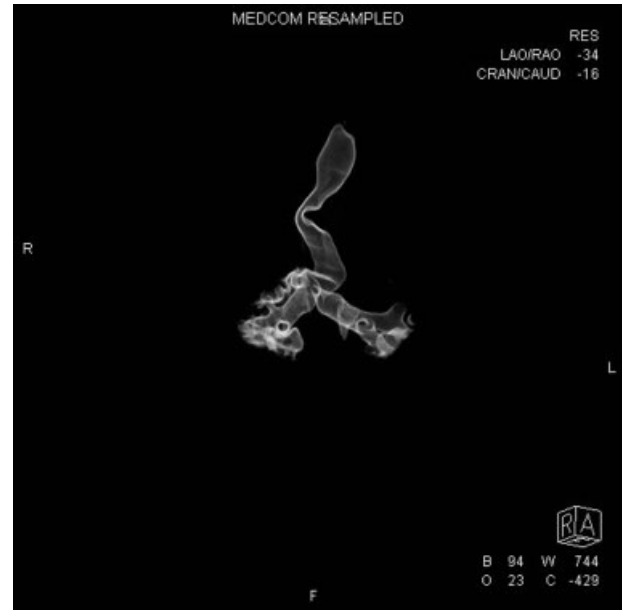**Fig. 1** The glottis of a mucopolysaccharidosis II patient showing a large amount of redundant arytenoid tissue.

most severe in MPS I, II, IV, and VI. A recent study by Morimoto et al looked at the glottic airway and lower airway in patients with MPS I, II, and IV.<sup>18</sup> They evaluated the airway by endoscopic examination and the lower airway by computed tomography (CT). They looked at 35 patients with 25 MPS II patients. They found that the tracheal morphology was abnormal in 50 to 60% due to a transversely collapsing trachea. Tracheal morphology was particularly severe in MPS II and IV. They noted respiratory distress in 15 of the 35 patients, of whom 7 showed tracheal deformity and 7 had laryngeal redundant tissue. Many of the patients with redundant laryngeal tissue were MPS II and IV patients. These patients not only complained of respiratory issues but also of choking and dysphagia (► **Figs. 3–4**).

These changes will result in obstructive sleep apnea (OSA) to a varying degree with resultant effects on the well-being of the patient such as daytime somnolence or in the severe case pulmonary hypertension. Treatment is, therefore, essential to both improve quality of life and avoid serious complications. Treatment usually starts with adenotonsillectomy, but this may only be partially effective due to the other airway

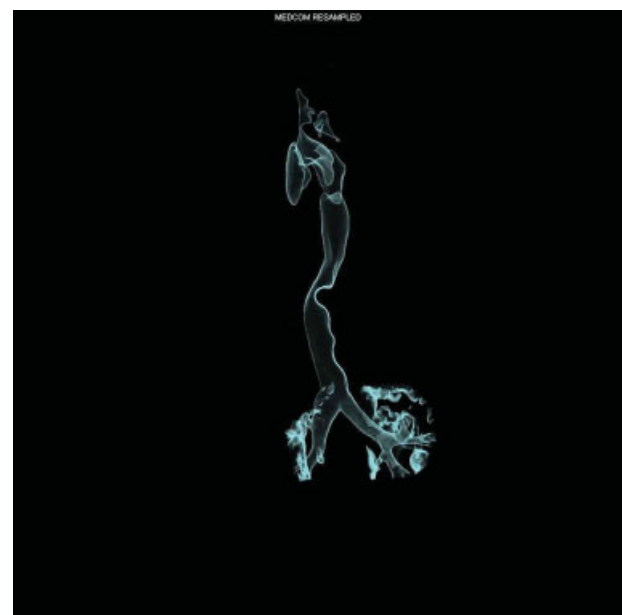


**Fig. 2** The mucopolysaccharidosis II glottis on inspiration showing indrawing of the redundant arytenoid tissue.



**Fig. 3** Reconstructed computed tomography of the trachea in a mucopolysaccharidosis IV patient showing tortuosity of the trachea.

issues or in the longer term with regrowth of the tissues. Treatment in more severe cases can be tried with noninvasive ventilation via either a facemask or nasal mask. Compliance in MPS patients is often poor with these techniques and in some cases a tracheostomy may be necessary.<sup>19,20</sup> Tracheostomy is notoriously difficult in these patients due to anatomical problems such as the short stiff neck and immobile cervical spine and a trachea buried deep in the neck often almost in the superior mediastinum. Tracheostomy is never an easy option but may improve quality of life dramatically in



**Fig. 4** Reconstructed computed tomography of the trachea in a mucopolysaccharidosis VI patient showing a mid-tracheal narrowing.

patients with severe OSA. The development of distal tracheal granulomata at the tip of the tracheostomy tube remains a difficult problem to treat.

In terms of anesthetic risk, the presence and severity of OSA are a good indicator of severity of airway problems and therefore, a good indicator of airway complications during anesthesia. A sleep study or polysomnography in addition to the clinical history is essential prior to an anesthetic.<sup>13</sup>

### Respiratory Abnormalities

MPS patients develop a restrictive type of pulmonary impairment due to hepatosplenomegaly and resultant diaphragmatic splinting and restricted excursion of the chest wall. This restrictive defect can compound OSA, worsening hypoventilation and making pulmonary hypertension and respiratory failure more likely.<sup>21</sup> Pulmonary function testing can be performed by spirometry, but the results can be difficult to interpret because of their short stature. Testing may not be possible in the young or uncooperative patient. Respiratory fitness may necessitate a review by a respiratory physician with X-rays and CT scans as necessary. Chronic infection and bronchospasm if present should be treated before anesthesia is considered.

### Cardiac Risk

Cardiac valvular disease is by far the most common finding in the MPS patients as a whole. This results from progressive thickening due to GAG deposition and causes either mitral or aortic stenosis and/or regurgitation. Mitral and aortic regurgitation are the commonest lesion.<sup>22</sup> Other cardiac manifestations are also found in MPS patients. Coronary artery infiltration with GAGs has been described in severe MPS I and may clinically go undetected due to communication problems and neurological disease. Coronary angiography or stress testing is obviously impractical. There is no information of Dobutamine stress testing in this group.<sup>23</sup> Severe coronary artery disease can be assumed to be present if ischemia is evident on a 12 lead electrocardiogram (ECG).

Hypertrophy of the myocardium may result in heart failure and has been reported in different types of MPS<sup>24</sup> and diastolic function may be affected likewise. The development of conduction system problems has also been described in MPS patients. Complete atrioventricular block has been described in MPS II, III, and VI.<sup>25</sup> As already stated, pulmonary hypertension can develop in those with severe OSA and can compound cardiac risk substantially.

### Spinal Cord/Cervical Spine

There are two areas where the spinal cord is at particular risk of compression, namely the thoracolumbar and the cranio-cervical regions.<sup>26,27</sup> It is the cervical spine that moves during induction of anesthesia and is therefore at particular risk of damage. Hypoplasia of the odontoid peg is the main issue and this occurs in the MPS IV and to an extent in MPS VI. These patients represent a group of patients with an "unstable" cervical spine and particular care must be taken at induction, during endotracheal intubation and during positioning and emergence.<sup>9</sup> Maintenance of the head and

neck in the neutral position with manual in line stabilization during the induction and intubation often suffices. For those patients undergoing spinal surgery to stabilize the cervical or thoracolumbar spine, neuromuscular monitoring in the form of motor-evoked potential monitoring is mandatory.

## Current Disease Specific Treatments and Their Impact on Anesthetic Risk

Current available treatments for MPS disorders include allogeneic HSCT and ERT. Both modes of therapy reduce the GAG deposition in the soft tissues of the airway among other effects and therefore impact on the safety of anesthesia.<sup>28</sup>

### Hematopoietic Stem Cell Transplantation

Hematopoietic stem cell transplantation is the gold standard treatment of the severe form of MPS I.<sup>29</sup> It is performed before the age of 2 years to maximize the neurological benefit. This treatment has been limited to MPS I Hurler's (MPS IH) due to the risks associated with it, but recently as safety has improved it has been extended to treat patients with Hurler-Scheie (HS).<sup>30</sup> HSCT is the only treatment that can halt the neurological decline in MPS. Following HSCT and successful engraftment of donor cells, the recipient is able to produce their own missing enzyme resulting in a significant improvement in many organ systems. This improvement, however, is not uniform throughout the body. There is a general regression of the coarse features, improvement in cardiac function, due to improved myocardial function, improved airway obstruction, and reduction in hepatosplenomegaly.<sup>31,32</sup> There remains, unfortunately, limited resolution of skeletal, cardiac valvular, and corneal effects.

The improvement in the facial features, airway, and cardiac function following HSCT reduces anesthetic risk substantially.<sup>28</sup> A report of MPS I post-HSCT patients from our own institution showed a marked reduction in airway-related complications during anesthesia. The incidence of airway complications was 14% in this group compared with 57% for those patients with MPS I HS treated with ERT. Twenty years previously we had reported an incidence of airway complications during anesthesia of over 50% in the MPS I H patients with a failed intubation rate of 23%.<sup>9</sup> Frawley, from Melbourne Children's, has also reported similar findings in a smaller group of post-HSCT MPS I H patients.<sup>33</sup> He reported a difficult intubation rate overall in a mixed MPS group of 27% and in the MPS I H post-HSCT group 12%.

Hematopoietic stem cell transplantation, therefore, significantly improves the ease of airway management during anesthesia, and therefore the safety of anesthesia.

### Enzyme Replacement Therapy

Enzyme replacement therapy has been available for MPS I and II for ~15 years and is now available for MPS I, II, IV, and VI.<sup>34,35</sup> ERT is administered as a weekly infusion and often requires indwelling intravascular devices to enable repeat infusions. ERT is the preferred mode of treatment for MPS

patients without neurocognitive dysfunction. This is historically due to the high risks associated with HSCT but this is changing.<sup>36</sup>

Enzyme replacement therapy does not improve pre-existing neurocognitive dysfunction, because of its inability to cross the blood–brain barrier but does have some favorable effects which will also influence anesthetic risk. ERT produces an improvement in airway obstruction (measured by a reduction in OSA) and improves myocardial function and respiratory parameters as well as improving many quality of life measures.<sup>29,37–41</sup> Unfortunately, ERT does not alter skeletal abnormalities, cardiac valvular problems, and eye issues. This means that many of these affected patients will present later in life for major orthopedic, spinal, cardiac, or eye procedures.<sup>37</sup>

What evidence is there for improvement in anesthetic risk? ERT for patients with MPS I, II, and VI has shown a positive impact on the 6 minutes or 12 minutes walk test (a test measuring exercise tolerance), and on pulmonary function.<sup>42,43</sup> In addition, improvement in walking distance was maintained for 240 weeks in MPS VI patients and the first forced expiratory volume and vital capacity increased (11 and 17%, respectively) after 96 weeks of ERT and continued thereafter.<sup>44</sup> This suggests that improved exercise tolerance and improved lung function are related. Although increases in pulmonary function must be interpreted with care in the growing child, there have been observed increases in lung function in MPS VI patients over the age of 12 years despite minimal growth. The evidence for improvement in OSA following ERT is less clear cut. A recent systematic review showed that OSA was most prevalent in MPS I, with 75% suffering moderate-to-severe OSA.<sup>45</sup> ERT itself showed a reduction in OSA but it did not quite reach statistical significance. Adenotonsillectomy, on the other hand, did significantly improve the level of OSA. Lastly, recently data from the Hunter outcome study looking at survival in MPS II patients who were treated and those not treated with ERT showed a greater length of survival in those treated with ERT.<sup>46</sup> This article showed a 10-year difference in those treated with ERT, again suggesting a beneficial effect on the cardiorespiratory system.

The evidence for improvement in many of the risk factors relevant to the anesthetist following ERT is there, but it must be noted that the improvement is less marked against an HSCT. This statement is backed up by data from Kirkpatrick et al and Frawley et al, the same year, to show that airway complications and the rate of difficult intubation are still over 50% in those patients treated with ERT.<sup>28,33</sup> It will be interesting in the future to see if those treated from infancy have a further reduced anesthetic risk than the groups of patients reported thus far.

## Changing Anesthetic Practice and Reduction in Risk

### Equipment and Anesthetic Practice

There is also evidence that the changing practice of anesthesia over the last 20 to 25 years has had an additional impact on the successful management of MPS patients undergoing

anesthesia.<sup>28,33</sup> Previous reports of case series of untreated MPS patients showed a uniformly high incidence of airway problems and indeed a high incidence of failed intubation.<sup>4–10</sup> In a series from our institution in Manchester reported a failed intubation rate of 23% in MPS I H patients.<sup>9</sup> In a more recent report, we report the failed intubation rate at 3%. Although the incidence of airway complications in the MPS I HS group remained high, the failed intubation rate has dropped dramatically.<sup>28</sup> The failed intubation rate in the post-HSCT MPSI patients was 0%, and this is almost certainly attributable to the treatment. The reduction in the failed intubation rate in the MPS I HS patients on ERT is more likely due to better anesthetic management, with the use of flexible fiberoptic equipment and supraglottic airways. Other centers have reported a similar experience.<sup>33</sup>

In recent years, there has been an explosion in new videolaryngoscopy technology which has made the management of the difficult airway and difficult intubation more accessible to a wider range of anesthetists. Some of these videolaryngoscopes could prove beneficial in the management of the MPS patient. They allow a magnified image to be relayed to a screen via a variety of technologies and enable the operator to “see round corners,” helping to visualize a previously impossible view of the larynx with conventional laryngoscopy. Both the Airtrach (Airtrach; Prodol Meditec, Vizcaya, Spain) and the Glidescope (Glidescope; Verathon, Bothell, Washington, United States) have been used in MPS patients.<sup>47–49</sup> The Glidescope has been recommended for use in MPS IV to manage endotracheal intubation in the potential unstable cervical spine.<sup>49</sup> This center recommended the Glidescope as first line in the difficult intubation scenario but also recommend use of the fiber optic bronchoscope to inspect the lower airway.

The videolaryngoscope is undoubtedly useful for difficult intubation management but may have a couple of drawbacks.<sup>37</sup> The instrument may provide a good view of the larynx but completion of endotracheal tube placement may still be problematic due to the excess of GAG tissue, the often-extreme angles involved and the narrowness of the glottic aperture in the older severely affected patient. In addition, one cannot inspect the lower airway for stenotic lesions and tracheomalacia and fiberoptic inspection is still recommended. The combination of the laryngeal mask airway and the fiberoptic scope in combination with a spontaneous ventilation technique remains the author's preferred technique for the difficult intubation scenario in the MPS patient as this allows maintenance of the airway and continuation of anesthesia during fiberoptic bronchoscopy and allows a choice of endotracheal tube size appropriate for the pathology within the upper and lower airways. The choice of endotracheal tube remains critical to success in extubation of the advanced MPS patient. Any additional swelling in the upper or lower airway may be enough to cause complete airway obstruction postextubation. This can result in a dramatic loss of airway with the development of either pulmonary edema or a hypoxic cardiac arrest. Tracheostomy has been necessary on occasion due to this reason.<sup>50</sup>

Overall, a selection of equipment for difficult airway management should include all of the above in addition to

the presence of an experienced ENT surgeon to perform a tracheostomy if required in the severe airway scenario.

Tracheostomy deserves a special mention in the MPS patient. As stated previously, many MPS patients will have multilevel airway disease and this can result in severe OSA. If untreated, this will lead to progressive airway obstruction, and respiratory failure. The final treatment option after all simpler options have been exhausted is tracheostomy.<sup>15</sup> A tracheostomy can be necessary for the acute management of airway obstruction during anesthesia, or a planned treatment for OSA or as a planned procedure to cover a major procedure in a patient with advanced disease. It should be noted that both the surgical insertion and the management of an MPS patient for tracheostomy can be complex. The trachea can be buried deep in the neck and almost in the superior mediastinum and the fit of the tracheostomy tube can be difficult. The trachea is deep in the neck and has a narrow diameter and the distance to the carina is short. Adult tubes may not fit, being generally too large in diameter and length, and tubes that are adjustable may be necessary. In the longer term, formation of tracheal granulomata at the tip of the tracheostomy tube is described and difficult to manage.

### Organization of Care

Another major factor in the improvement of safety in perioperative care is the organization of medical care over the last 20 and 30 years. Children with MPS in many countries have been managed in pediatric centers with large metabolic units with all facilities available for their care. This has allowed the formation of teams and a multidisciplinary approach to their care. This has also allowed anesthetists to become much more familiar with this very rare group of conditions and develop techniques specifically for their management.<sup>51</sup>

This multidisciplinary care is integral to reducing risk in anesthesia. Patients should be seen by physician and preoperative workup can commence. This will include a visit to cardiology for an up to date echocardiogram and ECG and expert opinion, a visit to the ENT clinic for an examination of the airway, nasendoscopy if possible, and then any other investigations as necessary. These may include a CT of the lower airway, or X-rays and CT looking at the stability of the cervical spine. Following these visits, a multidisciplinary meeting can take place with the necessary people and patient and family as appropriate. The risks of the procedure can then be explained and weighed against the benefits before a decision to proceed is taken. All precautions for postoperative care can be made at the same time.

Of course, this is not present in all parts of the world, but certainly in terms of anesthesia for the rare condition familiarity is a tremendous advantage and helps to improve safety. This is also so for other specialties too.

### Current and Future Challenges

There is no doubt that HSCT and to a lesser extent ERT have proved successful in prolonging survival in MPS patients, but it must be said that these patients are left with a considerable burden of disease.<sup>29,46</sup> The success of treatment has reduced

the number of severely affected children presenting for anesthesia and surgery and it could be said that the child with Hurler syndrome or an MPS disorder is no longer the worst airway problem in pediatrics but that the most severe airway challenges have been successfully transferred into later life. Patients either post-HSCT or ERT patients may present in the late teenage years or indeed in the 20s or 30s for surgery for significant cardiac valvular lesions, spinal surgery to the craniocervical or thoracolumbar junction, corneal surgery, or airway surgery for severe OSA. Three examples of such cases illustrate the type of extreme challenge faced by anesthetists and surgeons.<sup>37</sup> In this recent publication, three adult MPS cases are described. The first was a 27-year-old with HS requiring a C1–4 laminectomy and occipitocervical fusion from the occiput to C5. He was managed by awake intubation (with difficulty) and post-operative ventilation for 3 days. The course was complicated by marked tongue swelling which settled with medical management and the patient was successfully extubated under controlled conditions and avoided a tracheostomy. Case two was a 25-year-old lady with Hurler-Scheie who presented with severe mitral stenosis and a left atrial clot for mitral valve replacement. On account of severe anxiety, she was intubated fiberoptically asleep through a laryngeal mask airway and during this examination her glottic aperture was noted to be very tight. She, therefore, had a tracheostomy as a planned procedure following the mitral valve replacement. She took several days to recover on the cardiac intensive care unit but did well and was successfully decannulated 6 weeks later. Case three was an 18-year-old with MPS II. He presented for airway assessment. He had multilevel airway issues and the CT showed lower airway narrowing. On induction of anesthesia, he suffered profound oxygen desaturation and he was woken up before deteriorating further. He represented after a near respiratory arrest at home. On this occasion, a tracheostomy was planned and he was intubated using an awake nasal intubation with sedation. The tracheostomy was extremely difficult due to a short neck and extremely thickened tissues. In addition, the sizing of the tracheostomy tube proved difficult and he had a prolonged stay in hospital until the tracheostomy was established.

These cases illustrate the extreme challenges facing the anesthetic and ENT team into the future. Formerly, these cases would be the responsibility of pediatric specialists, but in the three cases described there was collaborative working between adult and pediatric specialists.

This lends the best of both worlds to the management of these difficult cases. However, as more patients survive to adulthood it is conceivable that many more will be managed in adult centers with little experience of these challenging patients and indeed the need for a multidisciplinary approach to their care will need to be reinvented in the adult setting. The ideal would be to develop a model of care based very much on the pediatric model if possible, but also encouraging collaborative working with pediatric specialists.

The challenge now and into the future in terms of perioperative care is to attempt to ensure that those MPS patients surviving well into adulthood are afforded the same level of

care and attention that they received in childhood and that anesthetists working in those centers where the adult MPS patient presents are supported and can access experienced clinicians for advice. This aim is not idealistic but necessary to avoid future disasters from inexperience. The developments of international networks of experts may be a way forward, in addition to encouraging a collaborative approach.

## References

- Smith RM. Anesthesia for Infants and Children. 4th ed. St. Louis, MO: CV Mosby; 1980:533–536
- DeLange C, Gerlings PG, DeKleyn A, Lettinga TW. Some remarks on gargoylism. *Acta Paediatr* 1943;31:398–410
- Hopkins R, Watson JA, Jones JH, Walker M. Two cases of Hunter's syndrome—the anaesthetic and operative difficulties in oral surgery. *Br J Oral Surg* 1973;10(03):286–299
- Herrick IA, Rhine EJ. The mucopolysaccharidoses and anaesthesia: a report of clinical experience. *Can J Anaesth* 1988;35(01):67–73
- Kemphorne PM, Brown TCK. Anaesthesia and the mucopolysaccharidoses: a survey of techniques and problems. *Anaesth Intensive Care* 1983;11(03):203–207
- Sjøgren P, Pedersen T, Steinmetz H. Mucopolysaccharidoses and anaesthetic risks. *Acta Anaesthesiol Scand* 1987;31(03):214–218
- Baines D, Keneally J. Anaesthetic implications of the mucopolysaccharidoses: a fifteen-year experience in a children's hospital. *Anaesth Intensive Care* 1983;11(03):198–202
- Belani KG, Krivit W, Carpenter BL, et al. Children with mucopolysaccharidosis: perioperative care, morbidity, mortality, and new findings. *J Pediatr Surg* 1993;28(03):403–408, discussion 408–410
- Walker RW, Darowski M, Morris P, Wraith JE. Anaesthesia and mucopolysaccharidoses. A review of airway problems in children. *Anaesthesia* 1994;49(12):1078–1084
- Moore C, Rogers JG, McKenzie IM, Brown TC. Anaesthesia for children with mucopolysaccharidoses. *Anaesth Intensive Care* 1996;24(04):459–463
- Arn P, Whitley C, Wraith JE, et al. High rate of postoperative mortality in patients with mucopolysaccharidosis I: findings from the MPS I Registry. *J Pediatr Surg* 2012;47(03):477–484
- Fecho K, Lunney AT, Boysen PG, Rock P, Norfleet EA. Postoperative mortality after inpatient surgery: incidence and risk factors. *Ther Clin Risk Manag* 2008;4(04):681–688
- Walker R, Belani KG, Braunlin EA, et al. Anaesthesia and airway management in mucopolysaccharidosis. *J Inherit Metab Dis* 2013;36(02):211–219
- Mendelsohn NJ, Harmatz P, Bodamer O, et al; Hunter Outcome Survey Investigators. Importance of surgical history in diagnosing mucopolysaccharidosis type II (Hunter syndrome): data from the Hunter Outcome Survey. *Genet Med* 2010;12(12):816–822
- Berger KI, Fagondes SC, Giugliani R, et al. Respiratory and sleep disorders in mucopolysaccharidosis. *J Inherit Metab Dis* 2013;36(02):201–210
- Leboulanger N, Louis B, Vialle R, Heron B, Fauroux B. Analysis of the upper airway by the acoustic reflection method in children with mucopolysaccharidosis. *Pediatr Pulmonol* 2011;46(06):587–594
- Simmons MA, Bruce IA, Penney S, Wraith E, Rothera MP. Otorhinolaryngological manifestations of the mucopolysaccharidoses. *Int J Pediatr Otorhinolaryngol* 2005;69(05):589–595
- Morimoto N, Kitamura M, Kosuga M, Okuyama T. CT and endoscopic evaluation of larynx and trachea in mucopolysaccharidoses. *Mol Genet Metab* 2014;112(02):154–159
- Kamin W. Diagnosis and management of respiratory involvement in Hunter syndrome. *Acta Paediatr* 2008;97(457):57–60
- Malik V, Nichani J, Rothera MP, et al. Tracheostomy in mucopolysaccharidosis type II (Hunter's syndrome). *Int J Pediatr Otorhinolaryngol* 2013;77(07):1204–1208
- Walker PP, Rose E, Williams JG. Upper airways abnormalities and tracheal problems in Morquio's disease. *Thorax* 2003;58(05):458–459
- Wippermann CF, Beck M, Schranz D, Huth R, Michel-Behnke I, Jüngst BK. Mitral and aortic regurgitation in 84 patients with mucopolysaccharidoses. *Eur J Pediatr* 1995;154(02):98–101
- Kimball TR. Pediatric stress echocardiography. *Pediatr Cardiol* 2002;23(03):347–357
- Hirth A, Berg A, Greve G. Successful treatment of severe heart failure in an infant with Hurler syndrome. *J Inherit Metab Dis* 2007;30(05):820
- Dilber E, Celiker A, Karagöz T, Kalkanoğlu HS. Permanent transfemoral pacemaker implantation in a child with Maroteaux-Lamy syndrome. *Pacing Clin Electrophysiol* 2002;25(12):1784–1785
- Tandon V, Williamson JB, Cowie RA, Wraith JE. Spinal problems in mucopolysaccharidosis I (Hurler syndrome). *J Bone Joint Surg Br* 1996;78(06):938–944
- Thorne JA, Javadpour M, Hughes DG, Wraith E, Cowie RA. Craniovertebral abnormalities in type VI mucopolysaccharidosis (Maroteaux-Lamy syndrome). *Neurosurgery* 2001;48(04):849–852, discussion 852–853
- Kirkpatrick K, Ellwood J, Walker RW. Mucopolysaccharidosis type I (Hurler syndrome) and anesthesia: the impact of bone marrow transplantation, enzyme replacement therapy, and fiberoptic intubation on airway management. *Paediatr Anaesth* 2012;22(08):745–751
- Muenzer J, Wraith JE, Clarke LA; International Consensus Panel on Management and Treatment of Mucopolysaccharidosis I. Mucopolysaccharidosis I: management and treatment guidelines. *Pediatrics* 2009;123(01):19–29
- de Ru MH, Boelens JJ, Das AM, et al. Enzyme replacement therapy and/or hematopoietic stem cell transplantation at diagnosis in patients with mucopolysaccharidosis type I: results of a European consensus procedure. *Orphanet J Rare Dis* 2011;6:55
- Boelens JJ, Aldenhoven M, Purtil D, et al; Eurocord; Inborn Errors Working Party of European Blood and Marrow Transplant group; Duke University Blood and Marrow Transplantation Program; Centre for International Blood and Marrow Research. Outcomes of transplantation using various hematopoietic cell sources in children with Hurler syndrome after myeloablative conditioning. *Blood* 2013;121(19):3981–3987
- Aldenhoven M, Wynn RF, Orchard PJ, et al. Long-term outcome of Hurler syndrome patients after hematopoietic cell transplantation: an international multicenter study. *Blood* 2015;125(13):2164–2172
- Frawley G, Fuenzalida D, Donath S, Yapli-to-Lee J, Peters H. A retrospective audit of anesthetic techniques and complications in children with mucopolysaccharidoses. *Paediatr Anaesth* 2012;22(08):737–744
- Muenzer J, Beck M, Giugliani R, et al. Idursulfase treatment of Hurler syndrome in children younger than 6 years: results from the Hunter Outcome Survey. *Genet Med* 2011;13(02):102–109
- McGill JJ, Inwood AC, Coman DJ, et al. Enzyme replacement therapy for mucopolysaccharidosis VI from 8 weeks of age—a sibling control study. *Clin Genet* 2010;77(05):492–498
- Parini R, Deodato F, Di Rocco M, et al. Open issues in mucopolysaccharidosis type I-Hurler. *Orphanet J Rare Dis* 2017;12(01):112
- Hack HA, Walker R, Gardiner P. Anaesthetic implications of the changing management of patients with mucopolysaccharidosis. *Anaesth Intensive Care* 2016;44(06):660–668
- Wraith JE, Beck M, Lane R, et al. Enzyme replacement therapy in patients who have mucopolysaccharidosis I and are younger than 5 years: results of a multinational study of recombinant human alpha-L-iduronidase (laronidase). *Pediatrics* 2007;120(01):e37–e46

- 39 Brands MM, Frohn-Mulder IM, Hagemans ML, et al. Mucopolysaccharidosis: cardiologic features and effects of enzyme-replacement therapy in 24 children with MPS I, II and VI. *J Inherit Metab Dis* 2013;36(02):227–234
- 40 Fesslová V, Corti P, Sersale G, et al. The natural course and the impact of therapies of cardiac involvement in the mucopolysaccharidoses. *Cardiol Young* 2009;19(02):170–178
- 41 Hendriksz CJ, Al-Jawad M, Berger KI, et al. Clinical overview and treatment options for non-skeletal manifestations of mucopolysaccharidosis type IVA. *J Inherit Metab Dis* 2013;36(02):309–322
- 42 Clarke LA, Wraith JE, Beck M, et al. Long-term efficacy and safety of laronidase in the treatment of mucopolysaccharidosis I. *Pediatrics* 2009;123(01):229–240
- 43 Harmatz P, Whitley CB, Waber L, et al. Enzyme replacement therapy in mucopolysaccharidosis VI (Maroteaux-Lamy syndrome). *J Pediatr* 2004;144(05):574–580
- 44 Harmatz P, Yu ZF, Giugliani R, et al. Enzyme replacement therapy for mucopolysaccharidosis VI: evaluation of long-term pulmonary function in patients treated with recombinant human N-acetylgalactosamine 4-sulfatase. *J Inherit Metab Dis* 2010;33(01):51–60
- 45 Pal AR, Langereis EJ, Saif MA, et al. Sleep disordered breathing in mucopolysaccharidosis I: a multivariate analysis of patient, therapeutic and metabolic correlators modifying long term clinical outcome. *Orphanet J Rare Dis* 2015;10:42
- 46 Burton BK, Jago V, Mikl J, Jones SA. Survival in idursulfase-treated and untreated patients with mucopolysaccharidosis type II: data from the Hunter Outcome Survey (HOS). *J Inherit Metab Dis* 2017;40(06):867–874
- 47 Osthaus WA, Harendza T, Witt LH, et al. Paediatric airway management in mucopolysaccharidosis 1: a retrospective case review. *Eur J Anaesthesiol* 2012;29(04):204–207
- 48 Megens JH, de Wit M, van Hasselt PM, Boelens JJ, van der Werff DB, de Graaff JC. Perioperative complications in patients diagnosed with mucopolysaccharidosis and the impact of enzyme replacement therapy followed by hematopoietic stem cell transplantation at early age. *Paediatr Anaesth* 2014;24(05):521–527
- 49 Theroux MC, Nerker T, Ditro C, Mackenzie WG. Anesthetic care and perioperative complications of children with Morquio syndrome. *Paediatr Anaesth* 2012;22(09):901–907
- 50 Walker RW, Colovic V, Robinson DN, Dearlove OR. Postobstructive pulmonary oedema during anaesthesia in children with mucopolysaccharidoses. *Paediatr Anaesth* 2003;13(05):441–447
- 51 Walker RW, Allen DL, Rothera MR. A fiberoptic intubation technique for children with mucopolysaccharidoses using the laryngeal mask airway. *Paediatr Anaesth* 1997;7(05):421–426