




Charcot Arthropathy of the Shoulder Associated with Syringomyelia: A Report of 2 Cases

Artropatia do ombro de Charcot associada à siringomielia: Relato de 2 casos

Mateus de Sousa Rodrigues¹ Camila Maciel Martins Coelho² Alexsandro da Silva Pereira³
Fernanda Tavares Neto⁴ Wanderson Ricardo Serapião da Silva⁵ Heverty Rocha Alves Neto⁵
Cícero do Juazeiro Job Maciel⁶ Cícero Santos de Lima⁵ Randson Ranilson Modesto Feitosa³

¹Neurosurgery Department, Universidade Federal do Vale do São Francisco (UNIVASF), Petrolina, PE, Brazil

²Nursing Department, Nursing Student Course, Universidade de Pernambuco (UPE), Petrolina, PE, Brazil

³Medical School Department, Universidade Federal do Vale do São Francisco (UNIVASF), Petrolina PE, Brazil

⁴Pharmacy Department, Universidade Maurício de Nassau (UNINASSAU), Juazeiro do Norte, BA, Brazil

⁵Neurosurgical Department, Universidade Federal do Vale do São Francisco (UNIVASF), Petrolina, PE, Brazil

⁶Neurosurgical Department, São Camilo Hospital, Crato, CE, Brazil

Address for correspondence Mateus de Sousa Rodrigues, MD, Av. José de Sá Maniçoba, s/n, Petrolina, PE 56330-400, Brazil (e-mail: mateus.kamloops@gmail.com).

Arq Bras Neurocir

Abstract

Charcot arthropathy of the shoulder caused by syringomyelia is a unusual degenerative disorder, frequently misdiagnosed and with few cases described in the literature. The diagnosis is made by clinical evaluation and radiological examinations with radiography and magnetic resonance imaging. However, the correct diagnosis and treatment is possible by carefully medical evaluation and can improve patient symptoms. Therefore, this study aimed to report two cases of Charcot arthropathy caused by syringomyelia. After achieving correct neurosurgical evaluation and magnetic resonance imaging, the diagnosis was made. The first case is a 53-year-old man with a click on his right shoulder for at least 12 months, associated with local edema, pain and limitation of joint range of motion. The second is a 45-year-old man with pain in the right upper limb and difficulty moving the joint for at least 24 months, associated with progressive worsening of the collection and edema in the ipsilateral upper limb. Posterior fossa decompression was performed, with symptoms relief after surgery. Posterior fossa decompression is a treatment that seems to be effective in reducing symptoms, especially when the diagnosis is early. However, this type of treatment still remains controversial, requiring further studies.

Keywords

- ▶ charcot arthropathy
- ▶ neurogenic arthropathy
- ▶ syringomyelia
- ▶ shoulder

Resumo

A artropatia de Charcot do ombro causada por siringomielia é uma doença degenerativa incomum, frequentemente subdiagnosticada e com poucos casos descritos na

received
November 15, 2022
accepted
June 21, 2023

DOI <https://doi.org/10.1055/s-0044-1779437>.
ISSN 0103-5355.

© 2024. Sociedade Brasileira de Neurocirurgia. All rights reserved. This is an open access article published by Thieme under the terms of the Creative Commons Attribution-NonDerivative-NonCommercial-License, permitting copying and reproduction so long as the original work is given appropriate credit. Contents may not be used for commercial purposes, or adapted, remixed, transformed or built upon. (<https://creativecommons.org/licenses/by-nc-nd/4.0/>)
Thieme Revinter Publicações Ltda., Rua do Matoso 170, Rio de Janeiro, RJ, CEP 20270-135, Brazil

Palavras-chave

- ▶ artropatia de charcot
- ▶ artropatia neurogênica
- ▶ siringomielia
- ▶ ombro

literatura. O diagnóstico é feito pela avaliação clínica e exames radiológicos com radiografia e ressonância magnética. No entanto, o diagnóstico e tratamento corretos são possíveis mediante avaliação médica criteriosa e podem melhorar os sintomas do paciente. Portanto, este trabalho objetiva relatar dois casos de artropatia de Charcot causada por siringomielia. Após obter correta avaliação neurocirúrgica e ressonância magnética, o diagnóstico foi feito. O primeiro caso é um homem de 53 anos com clique no ombro direito por pelo menos 12 meses, associado a edema local, dor e limitação da amplitude do movimento articular. O segundo é um homem de 45 anos com dor em membro superior direito e dificuldade de movimentação articular há pelo menos 24 meses, associada a piora progressiva da coleção e edema em membro superior ipsilateral. A descompressão da fossa posterior foi realizada, com alívio dos sintomas após a cirurgia. A descompressão da fossa posterior é um tratamento que parece eficaz na redução dos sintomas, principalmente quando o diagnóstico é precoce. Porém, esse tipo de tratamento ainda permanece controverso, necessitando de mais estudos.

Introduction

Charcot arthropathy is a chronic, normally progressive, degenerative disease caused by a sensorineural deficit that causes destruction of one or more joints.¹ Early diagnosis of Charcot neuroarthropathy is essential to prevent disease progression. Feet and ankle involvement are more prevalent in diabetics. The knee is most often affected in patients with syphilis. In syringomyelia, the shoulder and elbow joints are most commonly affected.² Syringomyelia is a chronic, progressive, and degenerative disorder of the spinal cord with formation and enlargement of a central fluid cavity (syrinx), affecting pain and thermal sensations, and generally sparing motor function and proprioception.³ The etiology of the disease can be congenital, Arnold-Chiari malformation type I, communicating hydrocephalus, trauma, spinal tumors, infection, degeneration, or vascular disease.⁴

About 5% of Charcot arthropathy cases affect the shoulder joint.⁵ Shoulder involvement in Charcot neuroarthropathy is commonly misdiagnosed and often confused with infections, rotator cuff tendon rupture, fractures, or pathological conditions with a better prognosis.⁶ The most common cause of shoulder Charcot arthropathy is syringomyelia. A quarter of patients with syringomyelia develop neuropathic arthropathy.⁷ In general, joint symptoms may appear earlier than neurological symptoms. Charcot arthropathy can develop insidiously as well as abruptly, causing rapid and progressive joint destruction.³

Despite the severity of Charcot arthropathy associated with syringomyelia if it is not diagnosed early, there are still few case reports on the subject, especially in cases related to syringomyelia. Thus, this study aimed to report two cases of Charcot arthropathy caused by syringomyelia.

Case Report**Case 1**

A 53-year-old man from the rural area of Cabrobó, in the state of Pernambuco, Brazil, presented to the emergency department

with clicking in the right shoulder for at least 12 months, associated with local swelling, pain, and limited range of joint motion. He was a former smoker (quit smoking more than 10 years prior) and had a previous prostate surgery due to urinary incontinence and benign prostatic hypertrophy. He denied high blood pressure and diabetes. Neurological examination showed predominance of right upper limb proximal monoparesis grade 3 muscle strength on the Medical Research Council (MRC) scale, and distal grade-4 muscle strength, abolished deep tendon reflexes in the upper right limb, hypotrophy of the suprascapular and lateral deltoid muscles, and inability to abduct above 90 degrees, ipsilaterally (→ Fig. 1). A radiograph of the right shoulder in anteroposterior (AP) and profile views was performed, showing significant joint destruction, with

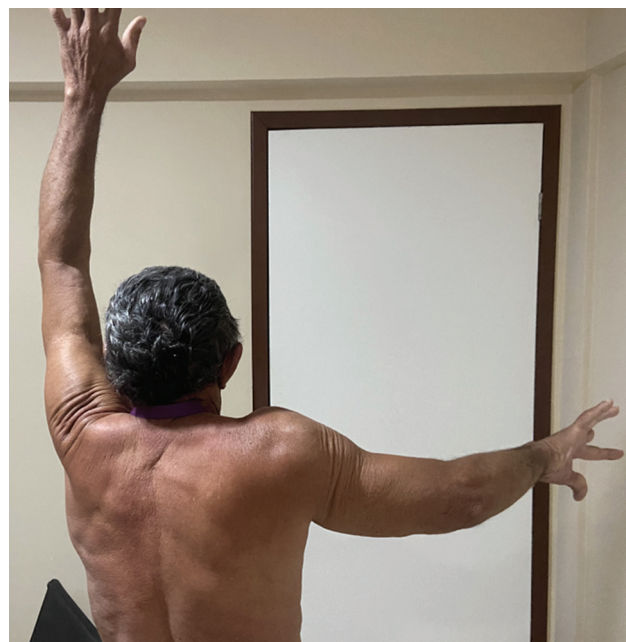

Fig. 1 Patient unable to abduct upper right limb of the arm from 90 degrees.

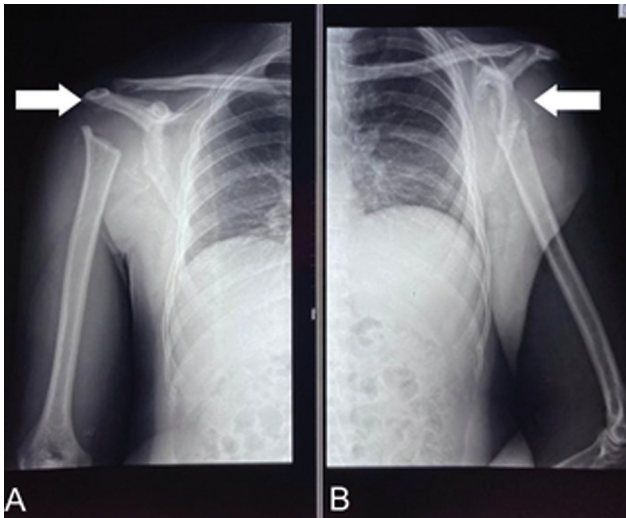


Fig. 2 Radiograph of upper limbs on coronal sections, showing destruction and absorption of the humeral head.

resorption of the head of the right humerus (► **Figs. 2A** and **2B**). The hypothesis of neoplasia and Charcot neuroarthropathy was raised, and magnetic resonance imaging (MRI) of the shoulder and cervical spine was requested. Right shoulder MRI showed bone destruction of the humeral head, with a liquid collection measuring $\sim 7.0 \times 4.7$ cm in the adjacent soft tissues (► **Fig. 3**). Cervical spine MRI showed syringomyelic cavity extending from the C2 to the T3 level and diffuse degenerative disc disease predominantly at the C5-to-T1 level (► **Fig. 4**). Neurosurgical treatment was proposed for occipitocervical decompression, but the patient refused the procedure, even though he was aware of the risks of possible neurological worsening. He is currently undergoing conservative treatment of neuroarthropathy with neuroleptics and non-steroidal analgesics.

Case 2

A 45-year-old man, a truck driver, from Salgueiro, in the state of Pernambuco, Brazil, arrived at the neurosurgical department with pain in the right upper limb and difficulty in joint motion for at least 24 months, associated with progressive worsening collection and edema in the ipsilateral upper

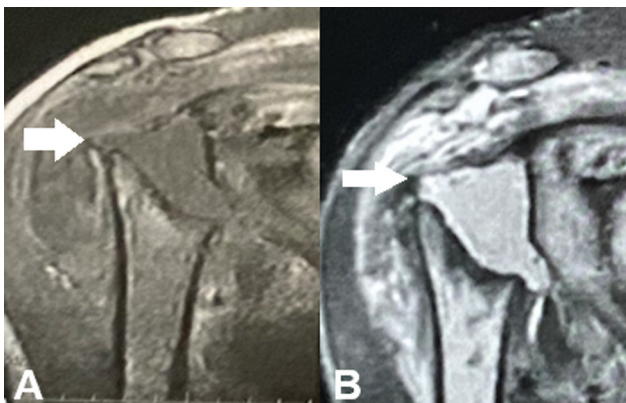

Fig. 3 Magnetic resonance imaging (MRI) of the right shoulder in T1- (A) and T2-weighted (B) sequence, in sagittal view, showing bone destruction of the humeral head with adjacent fluid collection.

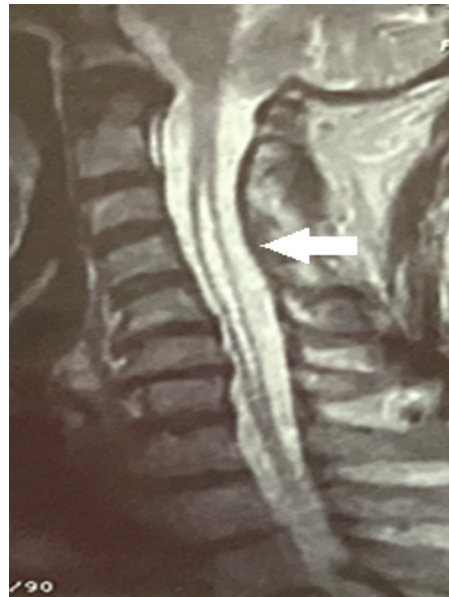


Fig. 4 Magnetic resonance imaging (MRI) of the cervical spine in T2-weighted sequence, in sagittal section, showing extensive syringomyelic cavity extending from the C2 to the T3 level.

limb. He also presented paresthesia, loss of strength, and inability to abduct the right upper limb (► **Fig. 5A**). He denied high blood pressure, smoking, or diabetes. He was referred to an orthopedist, who performed a puncture of the brachial collection. Laboratory analysis showed a nonspecific chronic inflammatory process. The orthopedist proceeded with corticosteroid infiltration and immunosuppressive treatment, with no improvement. On neurological examination, he had grade-3 strength (MRC scale) in the right upper limb, signs of hypotrophy in the deltoid muscle, and hyporeflexia grade 1 (National Institute of Neurological Disorders and Stroke scale) in the ipsilateral upper limb. The deep tendon reflexes in the other limbs were grade 3 on the National Institute of Neurological Disorders and Stroke scale. He was unable to abduct the right upper limb from 45 degrees. Humeral radiography showed complete destruction of the right humeral head with resorption and signs of a local inflammatory reaction (► **Fig. 6**). Right shoulder MRI showed marked heterogeneous fluid distension of the glenohumeral joint cavity, associated with destruction of the humeral head, glenoid and rotator cuff tendons, compatible with erosive inflammatory arthropathy (► **Fig. 7**). Cervical spine MRI showed mild invagination of the cerebellar tonsils through the foramen magnum, signs of diffuse degenerative disc disease, and extensive cervical hydrosyringomyelia from C1 to T2 (► **Fig. 8**). The right upper limb ultrasound showed a homogeneous collection involving the humerus, measuring $\sim 7.6 \times 7.0 \times 6.6$ cm (186 cm^3) on its anterior view and $7.6 \times 7.0 \times 6.1$ on its posterolateral view (172 cm^3). Thus, dissection of the biceps brachii muscle through the anterior collection (~ 3 cm above the elbow) was performed. The hypothesis of Charcot neuroarthropathy secondary to syringomyelia associated with humoral factors and chronic inflammatory response was raised. Neurosurgical treatment was performed for posterior fossa decompression, with

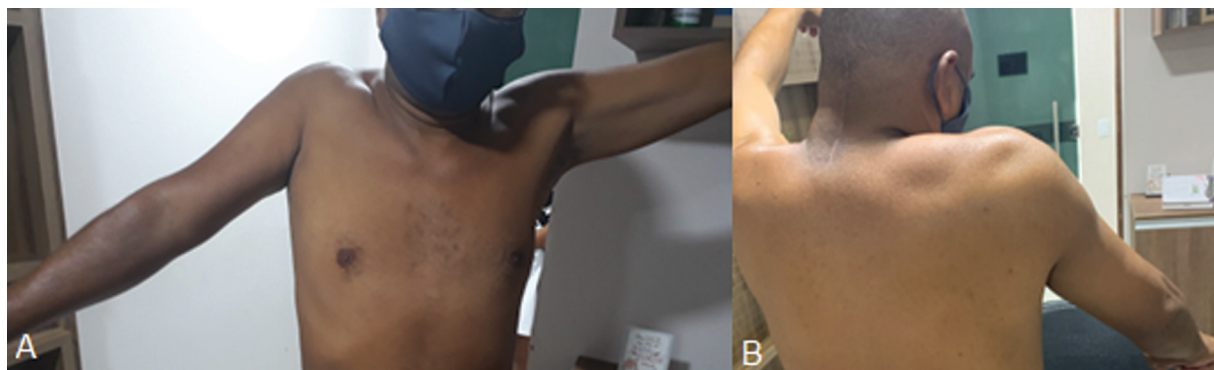


Fig. 5 Patient unable to elevate the right upper limb above 45 degrees before neurosurgical treatment (A); After posterior occipitocervical decompression (B).

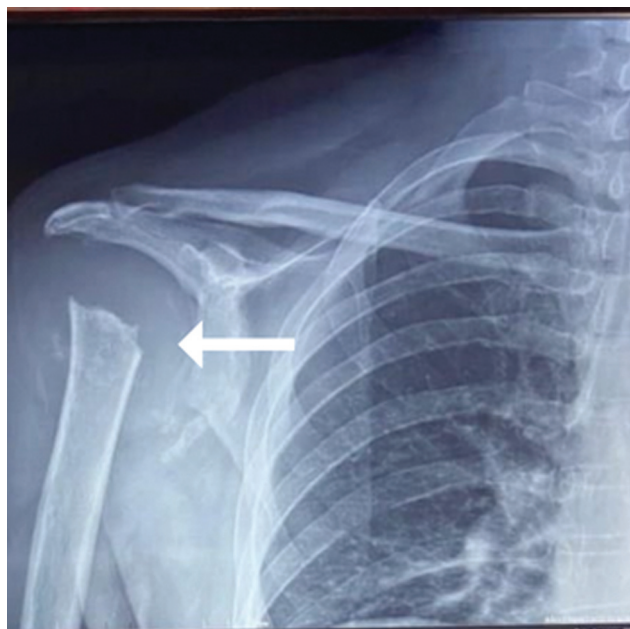

Fig. 6 Right upper limb radiograph on AP view, showing destruction and absorption of the humeral head.

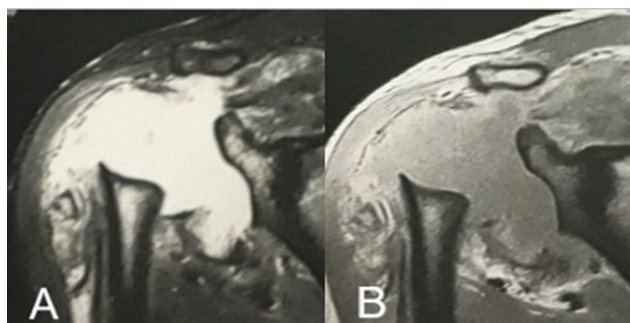


Fig. 7 Magnetic resonance imaging of the right shoulder in T2-weighted (A) and short tau inversion recovery (STIR) (B) sequence, in sagittal view, showing destruction of the humeral head, glenoid and rotator cuff tendons, with a voluminous adjacent fluid collection.

suboccipital craniectomy, C1 vertebral arch resection and duraplasty. After surgery, the patient had complete resolution of the inflammatory collection of the right brachial soft tissues and improvement in distal muscle strength (grade 4

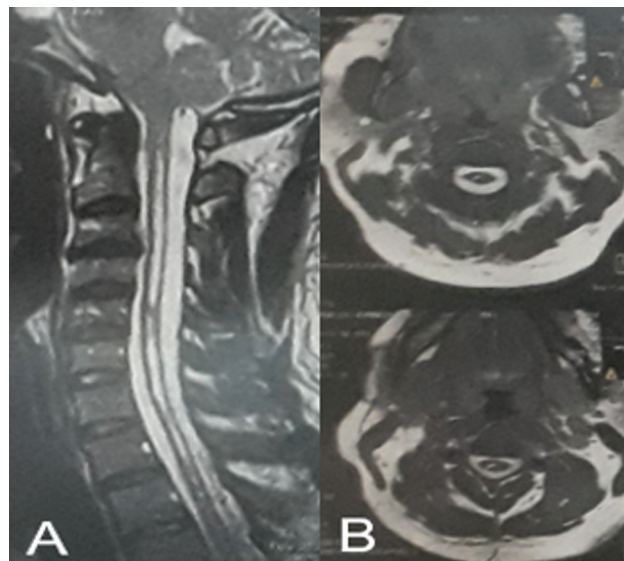


Fig. 8 Cervical spine magnetic resonance imaging in T2-weighted sequence, in sagittal (A) and axial (B) sections, showing extensive hydrosyringomyelia at the C1-to-T2 level.

on the MRC scale). Currently, the patient maintains the neurological condition and no progression of osteoarticular disease of the humerus (→ Fig. 5B).

Discussion

Neuropathic arthropathy was initially described by Mitchell in 1831, being fully characterized for the first time in 1868 by Jean-Martin Charcot, correlated, at the time, with neuropathy induced by tabes dorsalis (neurosyphilis). The first patient with neuropathic arthropathy caused by syringomyelia was described by Sokoloff in 1892.⁸ Charcot arthropathy in the shoulder is a progressive joint degeneration that develops over years and is usually diagnosed only in advanced stages of neurological diseases, the main one being syringomyelia of the cervical segments of the spinal cord.⁹

In syringomyelia, central fluid cavity present in the spinal cord causes progressive destruction of the shoulder joint either by compression effects or by abnormal conduction.¹⁰

Approximately 20 to 30% of patients with syringomyelia develop a secondary arthropathy of the shoulder.⁷ Syringomyelia is a rare disease that causes signs and symptoms such as massive bone loss, high inflammation, and neurological abnormalities such as weakness, loss of pain sensation, and arthropathy. In general, the affected shoulder presents a progressive degeneration of the humeral head and glenoid.⁵

The pathophysiology of neuropathic arthropathy is not completely proven, and there are two commonly accepted theories: neurovascular and neurotraumatic. The neurotraumatic theory claims that joint destruction is caused by repeated microtrauma, as a consequence of loss of proprioceptive and peripheral sensitivity resulting in macroscopic injuries such as fractures, dislocations, and joint deformities. The neurovascular theory suggests that peripheral neuropathy increases bone blood flow causing greater bone resorption and osteopenia by osteoclasts. Fragile bones are more susceptible to fractures, lesions, and joint destruction. Thus, it is believed that the junction of these two processes is responsible for the progression of the disease.^{1,3,5}

Early diagnosis is essential to prevent progressive joint destruction, since treatment is based on the management of syringomyelia. Magnetic resonance imaging is the gold standard for the diagnosis of syringomyelia. The progression of the disease can vary from insidious cases, in which the patient is asymptomatic or with few symptoms, to rapid progressions.⁶ The purpose of treatment for patients with neuropathic arthropathy is to slow the progression of the underlying disease and preserve joint functionality.¹¹ Conservative treatment consists of immobilizing the joint using orthosis and physical therapy to prevent further episodes of trauma. Pharmacological treatment is performed with non-steroidal anti-inflammatory drugs (NSAIDs) to decrease synovial inflammation. Bisphosphonates and calcitonin are used to reduce osteoclastic activity.¹² In the case of surgical treatment, arthroplasty or arthrodesis is contraindicated for most cases considering the high failure rates due to muscle weakness. The central goal of neurosurgical treatment is to prevent cavity enlargement and damage to the remaining parts of the spinal cord caused by syringomyelia.⁵

Conclusion

Charcot arthropathy is a differential diagnosis of pain, swelling and limited range of motion in the shoulder joint. In

patients with an unusual presentation of soft-tissue diseases, in order not to miss the disorder diagnosis, craniocervical MRI scan should be done to evaluate the presence of syringomyelia, in which the mainstay treatment is posterior fossa decompression. The correct diagnosis and treatment are possible by careful medical evaluation, and it can improve patient symptoms.

Conflict of Interests

The authors have no conflict of interests to declare.

References

- 1 Wukich DK, Sung W. Charcot arthropathy of the foot and ankle: modern concepts and management review. *J Diabetes Complications* 2009;23(06):409–426
- 2 Kim DH. Charcot Shoulder in a Patient With Tetraplegia. *PM R* 2016;8(01):82–84
- 3 Klekamp J. How Should Syringomyelia be Defined and Diagnosed? *World Neurosurg* 2018;111:e729–e745
- 4 Fernández AA, Guerrero AI, Martínez MI, et al. Malformations of the craniocervical junction (Chiari type I and syringomyelia: classification, diagnosis and treatment). *BMC Musculoskelet Disord* 2009;10(Suppl 1, Suppl 1):S1
- 5 Rickert MM, Cannon JG, Kirkpatrick JS. Neuropathic Arthropathy of the Shoulder: A Systematic Review of Classifications and Treatments. *JBJS Rev* 2019;7(10):e1–e1
- 6 Alai A, Reddy CG, Amrami KK, Spinner RJ. Charcot arthropathy of the shoulder associated with typical and atypical findings. *Clin Anat* 2013;26(08):1017–1023
- 7 Nacir B, Arslan Cebeci S, Cetinkaya E, Karagoz A, Erdem HR. Neuropathic arthropathy progressing with multiple joint involvement in the upper extremity due to syringomyelia and type I Arnold-Chiari malformation. *Rheumatol Int* 2010;30(07):979–983
- 8 Yablon CM, Duggal N, Wu JS, Shetty SK, Dawson F, Hochman MG. A review of Charcot neuroarthropathy of the midfoot and hindfoot: what every radiologist needs to know. *Curr Probl Diagn Radiol* 2010;39(05):187–199
- 9 Chakraborty PP, Datta S, Ray S, Bhattacharjee R, Chowdhury S. Unilateral neuropathic arthropathy of the shoulder secondary to syringomyelia: Diagnostic challenges. *World J Clin Cases* 2015;3(12):1017–1020
- 10 Jones J, Wolf S. Neuropathic shoulder arthropathy (Charcot joint) associated with syringomyelia. *Neurology* 1998;50(03):825–827
- 11 Petrova NL, Edmonds ME. Medical management of Charcot arthropathy. *Diabetes Obes Metab* 2013;15(03):193–197
- 12 Rastogi A, Bhansali A, Jude EB. Efficacy of medical treatment for Charcot neuroarthropathy: a systematic review and meta-analysis of randomized controlled trials. *Acta Diabetol* 2021;58(06):687–696