



# Physical Principles of Elastography: A Primer for Radiologists

Sayantana Patra<sup>1</sup> Shabnam Bhandari Grover<sup>1,2</sup>

<sup>1</sup>Department of Radiology and Imaging, Vardhman Mahavir Medical College and Safdarjung Hospital, New Delhi, India

<sup>2</sup>Department of Radiology and Imaging, Sharda School of Medical Sciences and Research, Sharda University, Greater Noida, Delhi NCR, India (current)

Address for correspondence Shabnam B. Grover, MD, DNBE, MNAMS, MRCC, (UK), FICMU, FICR, E-81, Kalkaji, New Delhi 110019, India (e-mail: Shabnamgrover@yahoo.com).

Indographics 2022;1:27–40.

## Abstract

Elastography is the noninvasive method of qualitative and quantitative evaluation of strain and elastic modulus distribution in soft tissues. In simpler terms, elastography is the science of measuring tissue stiffness, the deviation of which correlates with pathology of the tissue/organs being evaluated. Whereas, elasticity, refers to the property of solid matter to return to their original shape and size after removal of the deforming forces. In all forms of elastography, irrespective of the types of deforming forces or moduli, the deformation of tissue occurs in the form of shear deformation. The velocity of shear waves in the deformed tissue depends on its density and on the shear modulus. The direction of propagation of shear wave is perpendicular to the inciting mechanical or acoustic wave. The shear wave is then subsequently tracked using multiple tracking pulses, which measures tissue displacement in response to the passing shear wave. The calculated speed of the shear wave is then converted to conventional Young's modulus for the purpose of computing the tissue stiffness.

The currently used elastography techniques are static or quasi-static elastography and dynamic elastography. Strain elastography (a form of static or quasi-static elastography) is based on the principle of acquisition of radio-frequency (RF) signals before and after the application of a deforming force in the form of slight compression of tissue by a transducer. RF signals are compared between the pre-compression image data set and the post-compression image data set and correlated between the two data sets. Dynamic elastography may be either ultrasound (US) based or magnetic resonance (MR) based. The types of dynamic US elastography are: acoustic radiation force impulse imaging (ARFI), transient elastography (TE), point shear wave elastography (pSWE), and shear wave elastography (SWE). ARFI uses a standard transducer to produce and propagate rapid bursts of long focused ultrasound pulses, also called as “push pulses” which cause tissue deformity, the propagation of which is tracked using radio-frequency echo tracking. In TE, a probe mounted on a vibrator is used to produce a small thump by piston like motion of transducer. The shear wave which arises from the edges of the transducer is tracked using high pulse repetition frequency tissue Doppler

## Keywords

- ▶ elastography
- ▶ strain elastography
- ▶ ARFI
- ▶ transient elastography
- ▶ point Shear wave elastography
- ▶ shear wave elastography
- ▶ MR elastography

DOI <https://doi.org/10.1055/s-0042-1742575>.

© 2022. Indographics. All rights reserved.

This is an open access article published by Thieme under the terms of the Creative Commons Attribution-NonDerivative-NonCommercial-License, permitting copying and reproduction so long as the original work is given appropriate credit. Contents may not be used for commercial purposes, or adapted, remixed, transformed or built upon. (<https://creativecommons.org/licenses/by-nc-nd/4.0/>)

Thieme Medical and Scientific Publishers Pvt. Ltd., A-12, 2nd Floor, Sector 2, Noida-201301 UP, India

and computed using M-mode for display of quantitative parameters. Point shear wave, also known as quantitative ARFI, uses shear waves generated using transient tissue displacement caused by ARFI and are subsequently subjected to tracking by Doppler. Shear wave elastography is based on the principles of imaging shear wave speed. An acoustic radiation force impulse is transmitted along the acoustic axis to produce tissue displacement and deformation at points of acoustic axis. The generated shear wave is imaged using RF echo tracking over a grid of points, which is translated into a real time image. MR elastography is a dynamic technique and the basic principles of MR elastography are the same as other forms of dynamic elastography. MR elastography has limited utility in iron-overload states and in addition, due to the large amount of time required for acquisition, the technique is not suitable for unstable patients. This review presents a simplified summary of the principles of elastography along with definition of the terms and the types of elastography which are currently available to radiologists for clinical application and concludes with a brief on the newer developments for the future.

## Introduction

Palpation is an ancient but subjective technique for manual assessment of tissue stiffness which has been practiced since ancient times. Palpation is based on assessment of hardness or stiffness of abnormal tissues. Elastography can be considered as an extension of palpation, and it is the imaging evaluated representation of tissue stiffness which may be performed using a variety of imaging modalities. In technical terms, elastography is the noninvasive method of qualitative and quantitative evaluation of strain and elastic modulus distribution in soft tissues. In simpler terms, elastography is the science of measuring tissue stiffness, the deviation of which correlates with pathology of the tissue/organs being evaluated. As an instance, a process which involves fat deposition causes reduced tissue stiffness, while a process causing fibrosis or scirrhous tissue deposition results in increased tissue stiffness. Since changes in tissue stiffness (or elasticity) usually precede morphological changes, therefore, this technique provides for early diagnosis of disease processes and tissue characterization.<sup>1-3</sup>

## Evolution of Ultrasound Elastography

The pioneers to foray into the realm of ultrasound elastography were from England in the late 1980s, principal work being done by Tristram et al.<sup>2</sup> Initial attempts at quantification of tissue elasticity and deformability ventured into ultrasound-based subjective methods like motion quantification and visual inspection of B- and M-mode images, with little, if any success. The principal drawback for these methods were the absence of a standardized initial driving force which caused nonuniformity and interobserver variations in quantification of resulting deformability.<sup>1</sup> Subsequently by 1988, researchers from University of Rochester developed a system to track tissue movement using modified color Doppler. Doppler signals were used to generate tissue stiff-

ness-based images in a process which was christened “sonoelasticity” imaging. In sonoelasticity imaging, areas of altered elasticity were delineated with dark color against a green background. Subsequent evolution of elasticity measurements used two vibratory devices to create a shifting interference pattern, then termed as “crawling waves.” The latter technique estimated shear wave velocity and computed tissue stiffness from it.<sup>2</sup>

The first recognized strain elastography technique was innovated and implemented in 1991 by Ophir et al, from University of Texas Medical School in the United States. This method that underwent a lot of revisions is currently in a state of maturity and available with most high-end equipment.<sup>1,2</sup>

The subsequent development was in the field of dynamic elastography in the form of a nonimaging FibroScan device for the express purpose of estimating liver stiffness in the late 1990s.<sup>4</sup> FibroScan used the principles of transient elastography for the measurement of tissue stiffness.<sup>5</sup> The next most important development in dynamic elastography was the advent of shear wave elastography (SWE) which is under widespread investigation and presently the most employed technique and has garnered a lot of interest with the current generation imaging modalities. This because of the added advantages of independence from subjective variations and ability for definitive quantification, as is the case for strain elastography.<sup>2</sup> This review presents a simplified summary of the principles of elastography along with definition of the terms and the types of elastography which are currently available to radiologists for clinical application and a concludes with a brief on the newer developments for the future.

## Definition of Elasticity and the Basic Physics

Elasticity, in physical terms, refers to the property of solid matter to return to their original shape and size after removal of deforming forces. The principle of elasticity is derived from the terms of Hooke's law which is classically described as

“Stress is proportional to strain.” Here, stress is defined as the deforming force applied to matter, while strain is the change in dimensions (size) of the matter. In mathematical terms, Hooke’s law is expressed as:

$$F = -k \Delta x$$

Where,

*F*: force applied per unit area or stress, expressed in newton per square meter or pascal.

*k*: constant of proportionality which is unit less.

$\Delta x$ : change in spatial dimension (size), expressed in centimetres.<sup>6</sup>

### Definition of Elastic Moduli (Deforming Forces) and Their Types

The coefficient expressing the relationship between stress and strain is called as elastic modulus. Elastic modulus is a property of the atoms and molecules making up an object and does not depend on the size or shape of the object itself. To simplify, a block of wood and a block of iron of the same shape and dimensions will have different elastic moduli. Three types of elastic moduli are recognized based on the direction of deforming forces. These three types find application in different forms of elastography. In **Young’s modulus**, the force is **perpendicular** to opposing faces of object (►Fig. 1A) which is the type of modulus applicable to **strain elastography**. In **shear modulus**, the force is **tangential** to one face of object (►Fig. 1B) which is the type of modulus applicable to all types of dynamic elastography. In bulk modulus, the force is perpendicular to all faces of object (►Fig. 1C), which is indispensable for speckle tracking which forms the basis of all elastography techniques. The properties of these moduli are enumerated in ►Table 1.<sup>6</sup>

### Role of Shear Deformation, Its Types, and Its Clinical Applications

In all forms of elastography, irrespective of types of moduli, the deformation of tissue occurs in the form of shear deformation. **Shear deformation is used in both static (strain) and dynamic elastography**. Since shear deformation forms the backbone of every elastography technique, a detailed discussion into types of shear deformation is warranted. There are two types of shear, one being simple shear and the other pure shear. Simple shear involves forces that simply put, causes transformation of a square into a trapezoid, as shown in ►Fig. 1B. Pure shear is a little more complex, it involves the combined effects of compressive force and simple shear. The object undergoing pure shear is a complex entity, closely approximating solid biological tissue. The object can be conceptualized to consist of a square inside a cube as shown in ►Fig. 2. The applied force has two components, compressive and tangential. The compressive component causes reduction of vertical dimension while causing lateral expansion to preserve volume. The tangential component causes deformation of the inner square into a trapezoid. The complex interplay of force and solid tissue like object is depicted in ►Fig. 2.<sup>7,8</sup>

### Production and Propagation of Shear Waves

During elastography, a directional deforming force is applied to tissue. The force causes generation and propagation of shear deformation in the examined solid organ, in the form of a shear wave. The velocity of shear waves in the deformed tissue, depend on its density ( $\rho$ ) and shear modulus (*G*). The shear wave during elastography is usually produced in response to traversal of tissue by either mechanical waves or acoustic compression waves. The direction of propagation of shear wave is perpendicular to the inciting mechanical or acoustic wave. The shear wave is then subsequently tracked using multiple tracking pulses which measures tissue displacement in response to the passing shear wave. It is important to note that nonviscous fluids do not propagate shear waves, hence cysts appear as signal voids.<sup>2,7</sup>

The calculated speed of the shear wave is then converted to conventional Young’s modulus for the purpose of computing the tissue stiffness using the equation:

$$E = 3\rho V^2$$

Where,

*E*: Young’s modulus of elasticity.

$\rho$ : density of tissue or medium.

*V*: velocity of propagation of shear wave or shear wave speed (SWS).

The calculated shear wave velocity and tissue elasticity is displayed as a color overlay on the greyscale image with either blue or red denoting stiff tissues. An illustration demonstrating shear wave propagation is shown in ►Fig. 3.<sup>2,7</sup>

### Techniques of Elastography

The currently used elastography techniques are static or quasistatic elastography and dynamic elastography.

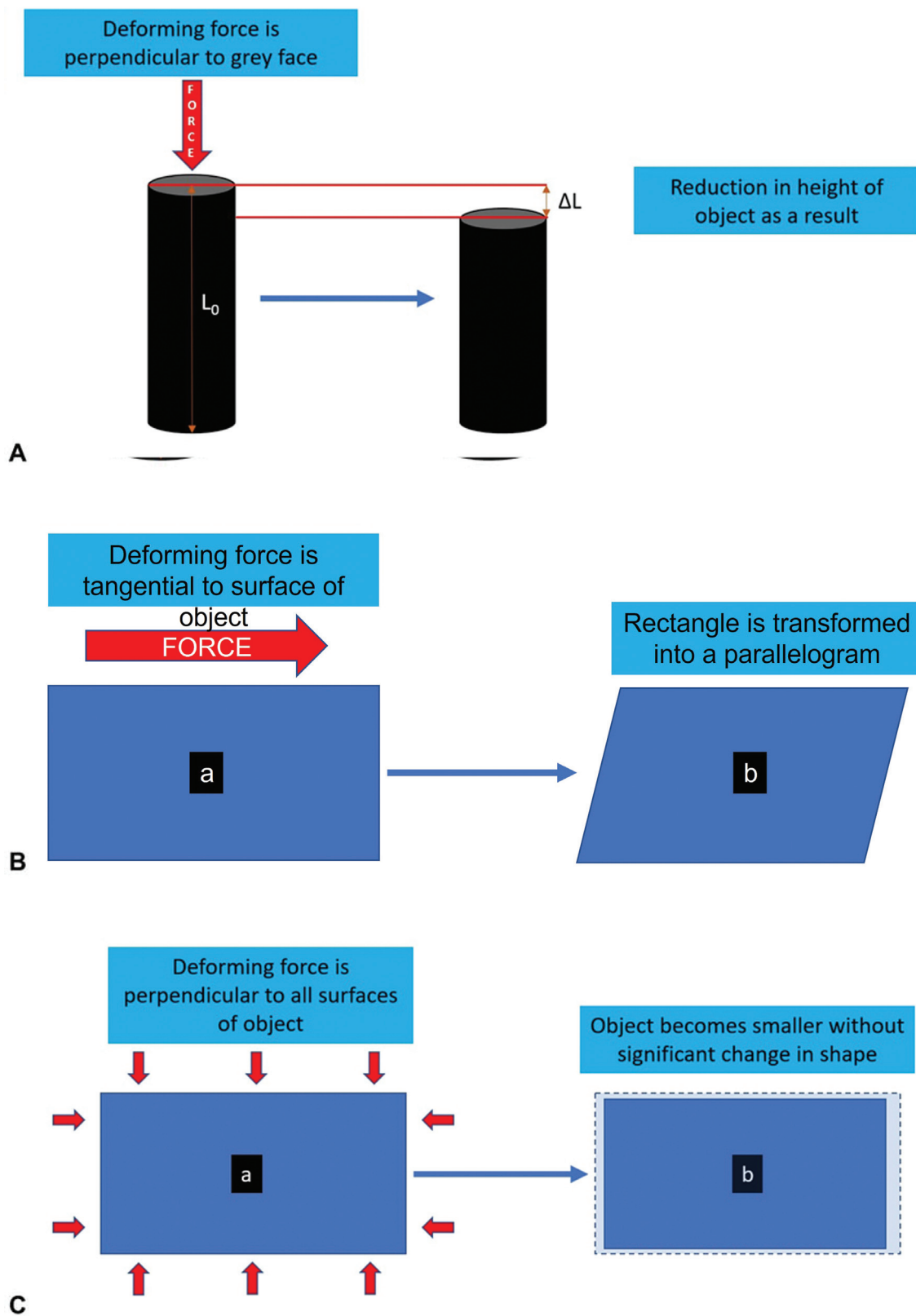
- Static elastography may be of two types: strain-encoding elastography and stimulated-echo elasticity imaging, both of which are forms of ultrasound elastography.<sup>9</sup>
- Dynamic elastography may be either **ultrasound based or magnetic resonance (MR) based**. The types of dynamic ultrasound elastography are: acoustic radiation force impulse imaging or acoustic radiation force imaging (ARFI), transient elastography (TE), point SWE (pSWE), and SWE.<sup>9</sup>

Types of elastography are represented in ►Fig. 4.

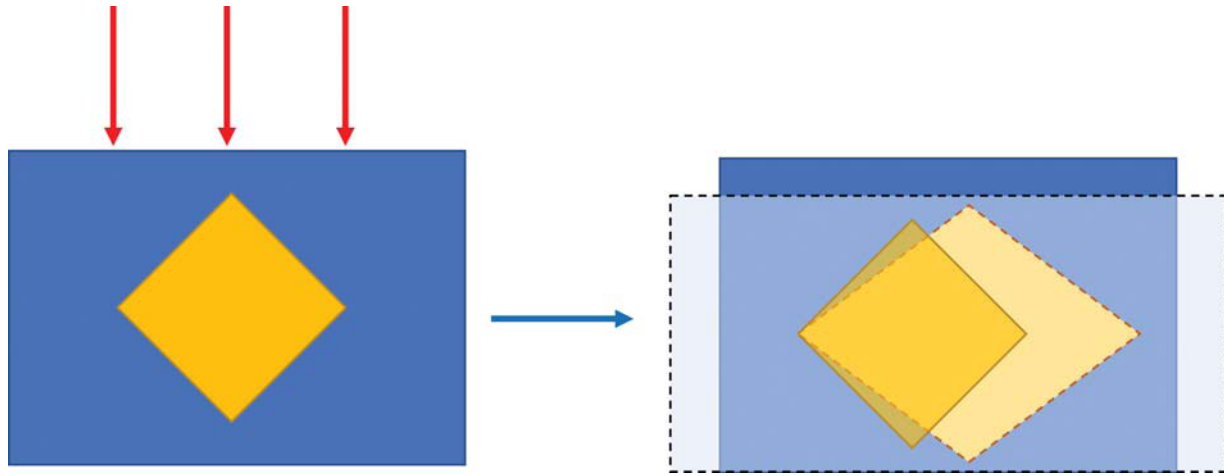
### Ultrasound Elastography

#### Role of Speckle Tracking in Ultrasound Elastography

Ultrasound elastography is based on the principle of estimation of tissue displacement or speckle tracking. A speckle is a point where there is a transition of tissues with different density and bulk modulus of elasticity. Speckles serve as image markers for shear deformation and are tracked using high-frequency and high-velocity ultrasound. In newer and advanced equipment, point-to-point real-time speckle tracking is performed which forms the basis of real-time elastography.<sup>7</sup>



**Fig. 1** (A) Illustration showing Young's modulus. A deforming force perpendicular to the gray face of a cylindrical object causes reduction of  $\Delta L$  amount of length. The ratio of  $\Delta L:L_0$  is termed the Young's modulus. (B) Illustration showing shear modulus. A deforming force parallel to the surface of a rectangular object (A) causes deformation into a parallelogram (B). This modulus is called shear modulus. (C) Illustration showing bulk modulus. A deforming force perpendicular to all surfaces of a rectangular object (a) causes shrinkage of the rectangle without significant change in shape, illustrated in (B). This modulus is called bulk modulus.



**Fig. 2** Diagrammatic representation of the principles of pure shear. Figure conceptualizes the effect of pure shear. The object is a cube with a square at the center. The applied force has a compressive component and a tangential component. The compressive component causes reduction of vertical dimension, while causing lateral expansion to preserve volume. The tangential component causes deformation of the square into a trapezoid.

Tissue displacement or speckle tracking may be performed by three different techniques as follows: (1) direct imaging, (2) strain imaging, and (3) speed of shear waves.

There are four different underlying principles of speckle tracking as follows: (1) radiofrequency echo correlation based tracking, (2) Doppler processing, (3) echo envelope tracking, and (4) echo envelope fluctuation rate.

A detailed discussion on these techniques would require engineering expertise and is beyond the scope of the present article.

The current discussion will emphasize on the two most commonly used forms of ultrasound-based computation of tissue stiffness, strain elastography and SWE. The unifying

characteristic present in all forms of ultrasound elastography is measurement of shear elastic modulus of tissue, through ultrasound assessment of time-varying tissue displacement.

### Static Elastography

#### Strain Elastography

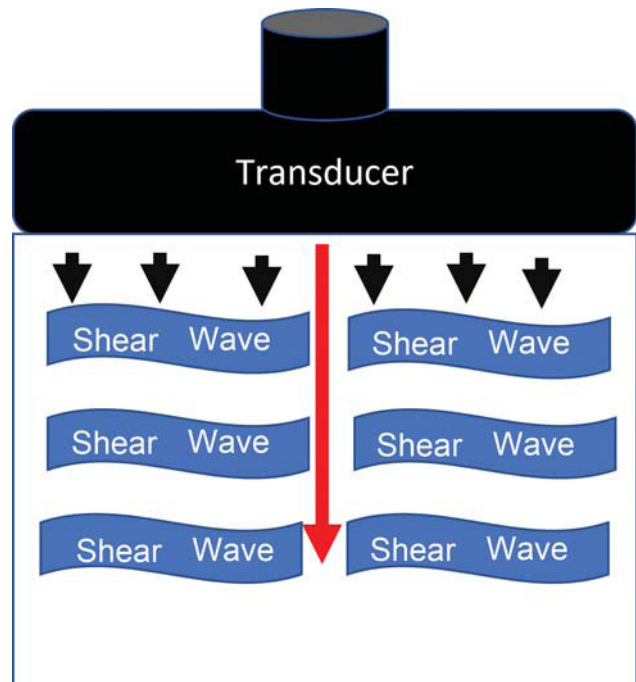
Strain elastography (a form of static or quasistatic elastography) is presently the most evolved and standardized technique available with majority of manufacturers. Strain elastography

**Table 1** Types of elasticity moduli

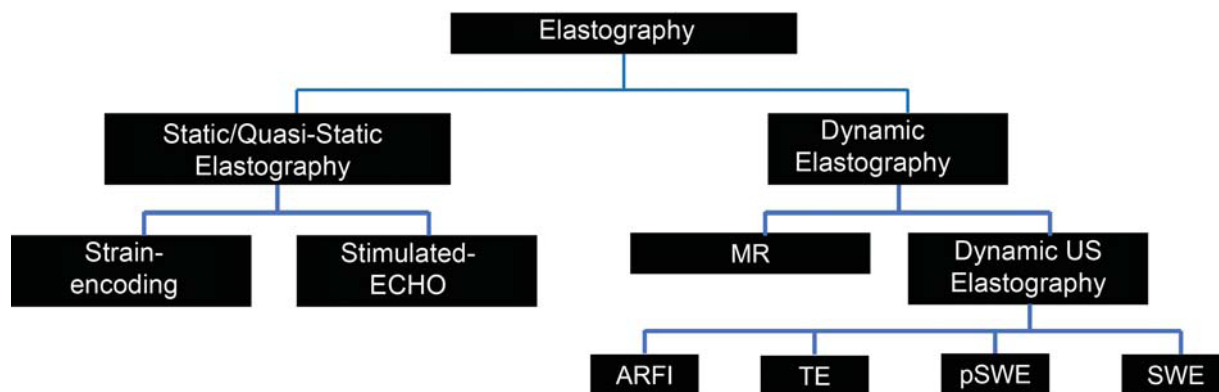
Modulus	Symbol	Stress	Strain	Configuration change
Young's	E or Y	Perpendicular to opposing faces (► Fig. 1)	Length $\epsilon = \Delta L/L_0$	Longer and thinner or shorter and fatter (► Fig. 1)
Shear	G or S	Tangential to surface of object (► Fig. 2)	Tangent $\gamma = \Delta X/Y$	Rectangle becomes parallelogram (► Fig. 2)
Bulk	K or B	Perpendicular to all faces of object	Volume $\Theta = \Delta V/V$	Change in volume, but not to shape (► Fig. 3)

Note:

1. E and Y are abbreviations representing Young's modulus. Epsilon ( $\epsilon$ ) is its mathematical representation, calculated as the ratio between alteration of length ( $\Delta L$ ) over initial length ( $L_0$ ).
2. G and S are abbreviations representing shear modulus. Gamma ( $\gamma$ ) is its mathematical representation, calculated as the ratio between alteration of length ( $\Delta X$ ) over initial length (Y).
3. K and B are abbreviations representing bulk modulus. Theta ( $\Theta$ ) is its mathematical representation, calculated as the ratio between alteration of volume ( $\Delta V$ ) over initial volume (V).



**Fig. 3** Diagrammatic representation of the principles of shear wave elastography. A "push pulse" is sent through the object being imaged (represented by the red arrow). The push pulse generates shear waves perpendicular to the direction of its propagation (represented by the blue waves). Tracking pulses (represented by black arrowheads) from the transducer allows tracking of these generated shear waves.



**Fig. 4** Classification of elastography techniques. ARFI, acoustic radiation force imaging; MR, magnetic resonance; pSWE, point shear wave elastography; SWE, shear wave elastography; TE, transient elastography; US, ultrasound.

measures tissue stiffness by applying external pressure, which causes deformation termed strain. Strain elastography is based on the principle of acquisition of radio frequency (RF) signals before and after deforming force application in the form of slight compression of tissue by a transducer. RF signals are compared between the precompression image dataset and the postcompression image dataset and correlated between the two datasets. In the next step, the rate of change of tissue displacement is compared with the depth or distance from the transducer. This results in larger displacement of a soft lesion compared with that of a hard lesion, as hard lesions move as a whole unit without deforming while soft lesions show both deformation and displacement. The nature of this relationship between object hardness and results of stress elastography is shown in **►Figs. 5 and 6.**<sup>2</sup> Strain elastography comprises two types based on method of tissue excitation – either using excitation by an internal or external method, or using an acoustic push pulse.<sup>10</sup>

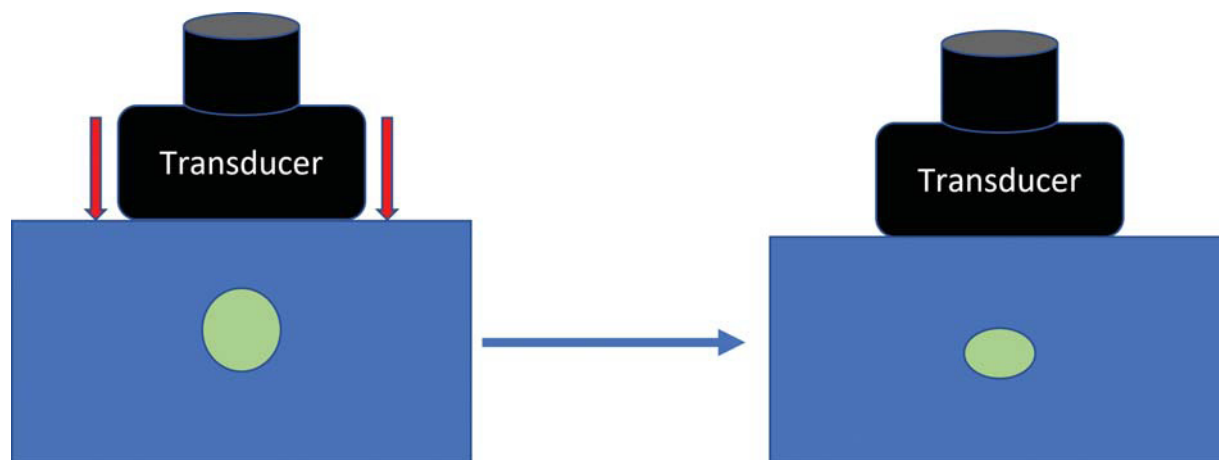
#### Strain Elastogram

The resultant strain is displayed in a color-coded map and is called a strain elastogram. However, quantitative tissue stiffness

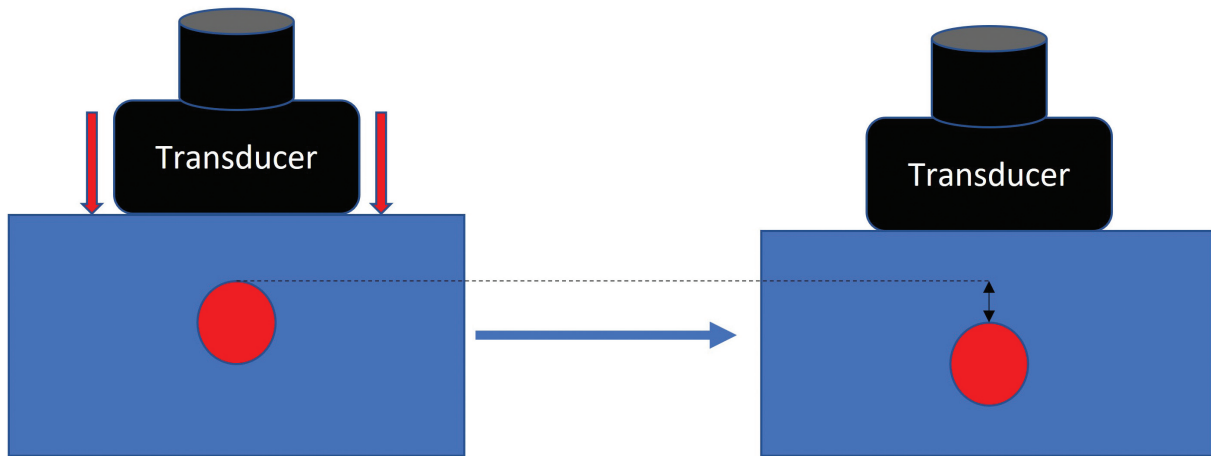
values are difficult to determine. This makes strain elastogram excellent for focal lesions like masses, while also making it completely inadequate for evaluation of diffuse abnormalities.<sup>2,7</sup>

#### Strain Quantification

Although there have been numerous studies for the application of semi-quantitative assessment (like the Tsukuba score) of tissue stiffness using strain elastography, there exists no linear relationship between degree of tissue stiffness and brightness/color code on the strain elastogram.<sup>11</sup> For this reason, quantification is not easily achieved and requires use of either one of two strategies. One involves using a pressure sensor to estimate Young's modulus, at the cost of degrading the image quality. The second method is estimation of strain ratio – calculated as a ratio between strain in a particular tissue or region of interest and a region considered normal for the purposes of comparison. The latter method may be improved upon by using particular emphasis on distance from lesion of interest and direction of placement of comparison ROI.<sup>2</sup> As an instance, for a breast lesion, two ROIs are placed – one within the lesion of interest and a comparative



**Fig. 5** A soft round lesion (in green) is shown, which shows deformation in response to red forces of the transducer into an oval shape and backward displacement of both the front and the back end.



**Fig. 6** A hard round lesion (in red) is shown, which shows displacement of both the front and the back end, but no deformation.

ROI within normal breast parenchyma at the same depth from the skin as lesion itself. Other methods of semi-quantitative assessment of strain elastograms are as follows – lesion to background strain contrast, pattern of strain distribution, histogram analysis for strain heterogeneity and elastography-to-B-mode size ratio, for comparing the lesion dimensions on strain elastogram and on grey scale ultrasound.<sup>12</sup>

#### Strain Rate Imaging

Strain rate imaging is a variant of strain imaging implemented in scanners with tissue Doppler capabilities, and specifically applied to study of muscular contraction and relaxation. The purpose of strain rate imaging is to distinguish between actively contracting and passively moving tissue. This technique finds use in study of gastrointestinal tract wall which remains the only present indication.<sup>7</sup>

#### Artifacts on Strain Imaging

Knowledge of a few artifacts related to strain imaging is essential for proper image interpretation. The first is **stress concentration or the Maltese cross artifact**. This artifact is based on the underlying principle that softer tissue tends to exhibit falsely high strain value when in proximity to harder tissue. The second is edge-enhancement artifact. Although the underlying cause of edge-enhancement is the same as Maltese cross artifact, the result is increased brightness at edges of a hard lesion due to poorly defined boundary between two structures. A third type of artifact, described as strain image characteristic is observed when the poorly defined edges of solid tissue also called in common parlance as “slippery boundary.” Nonlinearity of mechanical property of tissue also produces an artifact, the more the stress applied, the greater the stiffness of tissue, represented as an exponential relationship in mathematical terms. This type of artifact is called prestress artifact. Another artifact, called the egg-shell effect is seen as a falsely high tissue stiffness in a necrotic area within a hard lesion.<sup>7</sup>

Certain artifacts related to cysts deserve specific mention. Two characteristic appearances are described for cysts, bull’s eye or target sign and rapidly fluctuating strain. The bull’s

eye or target sign is produced when a cyst appears dark and the anterior/posterior areas appear bright on strain elastogram called as “bright ups.” The underlying cause of this appearance is stress concentration artifact. Several methods have been proposed to reduce cyst related artifacts. These include reduction of palpatory stress, reduction of stress persistence to zero, maximize gain and minimize quality rejection settings. Use of a dedicated cyst detection mode is also an option with some manufacturers of equipment.<sup>7</sup>

#### Strain Image Optimization

Certain important image optimizations are necessary for obtaining a good quality strain imaging as follows:<sup>2,7</sup>

- Proximity of ROI to transducer.
- No anatomical planes anterior to or within imaged part.
- Moderate distance of ROI from organ boundary.
- No vascular structure in proximity to ROI.
- Broader stress area compared with ROI.
- Limited number of target lesions.

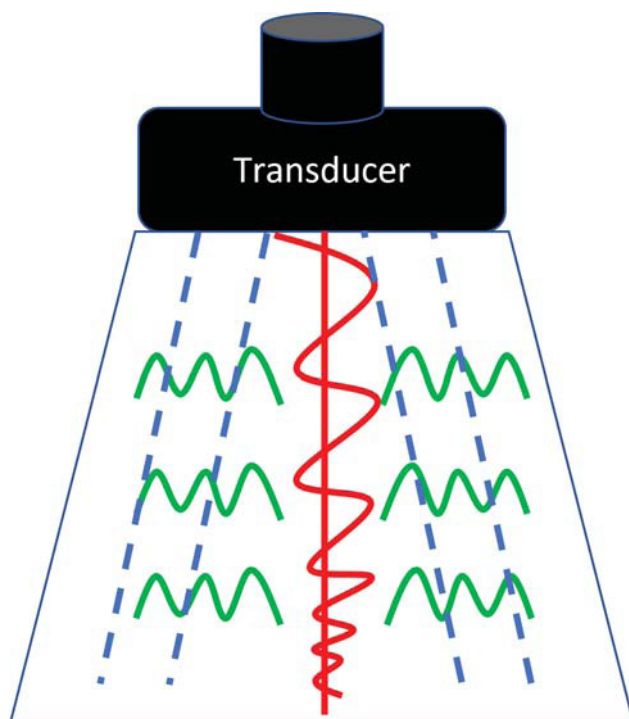
#### Dynamic Elastography

Dynamic elastography is based on application of dynamic forces which may be performed using either ultrasound or MR imaging (MRI). There are four recognized techniques for performing dynamic ultrasound elastography: ARFI, transient elastography, pSWE, and SWE.<sup>2,7</sup>

#### Acoustic Radiation Force Imaging

##### Principle

ARFI or acoustic radiation force impulse imaging was introduced as the first form of dynamic elastography. A standard transducer is used to produce and propagate **rapid bursts of long focused ultrasound pulses, also called as “push pulses.”** These “push pulses” cause tissue deformity, the propagation of which is tracked using radiofrequency echo tracking. The results are displayed within a small box as a qualitative elastogram. A diagrammatic representation of ARFI is shown in **Fig. 7**.<sup>7,13</sup>



**Fig. 7** Diagrammatic representation of acoustic radiation force impulse (ARFI) elastography. An ARFI wave is sent from the transducer (represented as the red line with red waveform). The ARFI wave induces green shear waves perpendicular to the direction of propagation (represented as green waves). The shear waves are then imaged with detection pulses (depicted as blue dotted lines).

#### Advantages

The principal advantage of this technique is production of better quality elastograms which surpass the spatial resolution of conventional strain elastography. The technique is also user independent, in contrast to conventional strain elastography. Additionally, there are also no artifacts related to cysts.<sup>7</sup>

#### Limitations

The principal limitation of ARFI is limited depth penetration, the technique shows inability to displace tissue sufficiently at depths greater than 6 cm. Displacement depends on absorption and reflection of pushing beam. Transducer heating due to rapid push pulses also limits the number of frames.<sup>7</sup>

### Transient Elastography

#### Principle

In transient elastography, a probe mounted on a vibrator is used to produce a small thump by piston-like motion of transducer. Shear wave arises from the edges of the transducer as a response to this transient thump like motion. A component of this shear wave travels along the ultrasound axis. The propagation of this component of shear wave is tracked using high pulse repetition frequency tissue Doppler. The resultant shear displacement is plotted against depth using unidimensional correlation tracking. There after the shear wave velocity is computed using M-mode. It is important to note that velocity measurements are applicable only to the middle

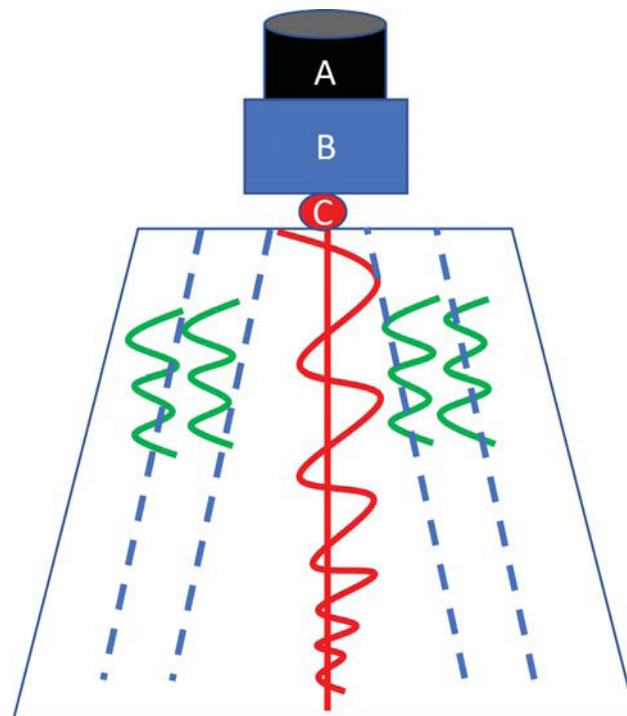
part of tissue, while the proximal part where the shear wave first arrives and the distal part where there is significant decay of shear wave are not considered in the measurement. Since the technique does not involve conventional ultrasound, no image is produced, instead quantitative parameters are displayed on the screen. The principles of transient elastography are diagrammatically represented in ► Fig. 8.<sup>7,13,14</sup>

#### Advantages

Reduced confounding findings are present when the measurement is taken intercostally for liver as this allows limitation of prestress (which causes falsely high stiffness values), as the ribs prevent any transmission of compression. The method also has limited thermal and mechanical indices compared with ARFI.<sup>7,13</sup>

#### Limitations

The absence of a guiding image is the chief limitation of this method which also makes it unsuitable for assessment of focal lesions. The method is also not suitable in presence of generalized ascites or localized fluid collections. The method also finds limited application in obese patients, with a standard 3.5-MHz probe. However, some of this limitation has been addressed by replacement of low penetration 3.5-MHz probe with a lower frequency and higher penetration 2.5-MHz probe. In addition, there is limited utility in dysmorphic livers, as imaging guidance is not available for appropriate positioning of ROI. The technique has been largely replaced with other dynamic elastography techniques.<sup>14</sup>



**Fig. 8** Diagrammatic representation of transient elastography. A probe (black, A) consisting of a vibrator (blue, B) and a transducer (red, C) is used to send a “thump” by piston like movement of the transducer, represented in red. The thump induces vertical shear waves (represented in green), which are subsequently tracked using trackers (represented by dotted blue lines).



## Point Shear Wave Elastography

### Principle

Point shear wave is also known as quantitative ARFI. In this technique, shear waves are generated using transient tissue displacement caused by ARFI. The generated shear waves travel outward in a cylindrical fashion from the ARFI wave. The shear waves are subsequently subjected to correlation tracking or Doppler, used to measure small shear wave displacements and detect its arrival at particular points. The time taken for travel across particular point in an ROI is taken into account. These two quantities are combined to obtain the shear wave velocity which is converted to Young's modulus and displayed.<sup>7,13</sup>

### Advantages

Point shear wave is a quantitative method of elastography which is displayed with an image overlay, so it can be used for both focal and diffuse diseases. The ARFI wave is not limited by ascites or fluid collections. There is also no limitation in obese patients. Since a guiding image is usually present, there is also no limitation in dysmorphic solid organs.<sup>7,13</sup>

### Limitations

The technique is not real time and hence has been replaced by shear wave velocity measurement or two- or three-dimensional (2D/3D) SWE which provides a real-time assessment.<sup>7,13</sup>

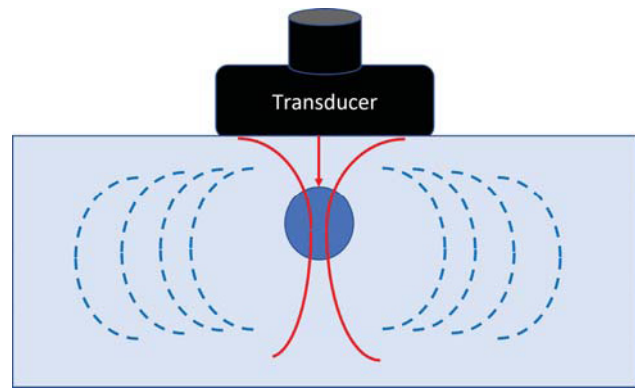
## Shear Wave Elastography

### Principle

While strain imaging measures the physical tissue displacement parallel to the applied normal stress, Shear Wave Imaging or SWI, makes use of a dynamic stress to generate shear waves either in the parallel or the perpendicular directions. Shear wave speed measurements provide both, qualitative and quantitative estimates of tissue elasticity. There are three technical varieties of SWI: the first one being 1-dimensional transient elastography or 1D-TE, which is the technology used in Fibroscan; while point shear wave elastography or pSWE which is the version used side by side with conventional ultrasound, whereas 2D shear wave elastography, or 2D-SWI, is the version which represents the most recent advancement of SWI. This technique uses an acoustic radiation force over multiple focal zones in rapid succession, which is faster than the shear wave speed and therefore creates a cylindrical shear wave cone or a "Mach cone." The generated shear waves are measured using RF echo tracking over a grid of points, which is translated into a real time image. The image is created from a map of the shear wave arrival time at different focal positions which is then subsequently displayed as a semi-transparent color overlay on the gray-scale image.<sup>2,7,15</sup> This technology allows for a real time dynamic elastography. The technology is available with a few manufacturers such as Siemens, Philips and Supersonic Imagine. A diagrammatic representation of the principles of SWE is shown in ► Fig. 9.

### Advantages

The Mach cone produced in SWE has the advantage of being less susceptible to decay, allowing better depth penetration



**Fig. 9** Diagrammatic representation of shear wave elastography. The transducer sends an acoustic wave in the form of a Mach cone (represented in red) with its center around the blue circle. In response shear waves are produced to propagate perpendicular to the direction of the Mach cone (represented with dotted blue lines). The shear waves so produced are imaged for their velocity of propagation.

(up to 8 cm). In addition to being an almost real-time quantitative method, SWE has the advantage of lack of stress concentration artifacts compared with other techniques. The method is also capable of measuring viscous component of shear modulus which is based on the assumption that biological tissues are viscoelastic. Reduced operator dependence and low incidence of prestress are other added advantages of this technique.<sup>7</sup>

### Limitations

The technique has less spatial resolution compared with strain imaging. Partial volume averaging artifacts plague image quality, causing image degradation. Shear wave propagation in certain areas violate the assumed relationship between elastic modulus and shear wave speed, especially near boundaries and within thin layers. Other potential sources of error, which violate preliminary assumptions include tissue heterogeneity, tissue attenuation, and any external precompression applied. Also, erroneous estimates of shear wave velocity have been reported in certain focal lesions, most commonly in breast, leading to misclassification of malignant lesions as benign. Certain manufacturer level software manipulations usually herald an erroneous estimate: error messages, indicator for shear wave speed out of range, flagging unreliable estimates with a special color or black. An initiative is currently underway for ironing out inconsistencies and establishing elastography standards by the quantitative imaging biomarker alliance (QIBA) formed by Radiological Society of North America (RSNA).<sup>2,7,13</sup>

► **Table 2** summarizes the different types of elastography techniques (adapted from Bamber et al).<sup>7</sup> ► **Table 3** aims to summarize, compare, and contrast strain elastography and SWE techniques, the two most popular methods of ultrasound elastography (adapted from Garra).<sup>2</sup>

## Magnetic Resonance Elastography

MR elastography is a rapidly emerging noninvasive diagnostic technique for interrogation of biomechanical properties

**Table 2** Types of commercially available elastography

Type	Applied force	Property imaged	Qualitative or quantitative	Imaging or measurement
Strain elasto and strain rate imaging	Mechanical, either active external or passive physiological internal	Strain or strain rate	Both—color coding is qualitative and strain ratios are semiquantitative	Full area image, high refresh rate
ARFI	Focused radiation force at depth	Displacement	Qualitative	Single image within box
Transient elastography	Thump at tissue surface	Shear wave speed	Quantitative	Single measurement, beam line average
Point shear wave elastography	Ultrasound focused radiation impulse at depth	Shear wave speed	Quantitative	Single measurement, ROI average
Shear wave elastography	Ultrasound induced radiation force in form of impulses or Mach cones	Shear wave speed	Quantitative	Single image within color box

Abbreviations: ARFI, acoustic radiation force imaging; ROI, region of interest.  
Note: Adapted from Bamber et al.<sup>7</sup>

of tissue, in both health and disease. MR elastography is a dynamic technique which is based on quantification of shear stress. The basic principles of MR elastography are the same as other forms of dynamic elastography.<sup>3,9</sup>

The underlying physical principles of MR elastography may be broken down into three basic steps listed below:

1. Generation of mechanical waves.
2. Imaging of propagating waves.
3. Estimation of mechanical parameters.

### Generation of Mechanical Waves

Mechanical waves of a single frequency are generated by external drivers. The generated mechanical waves are synchronized to the MR pulse sequence used for imaging. There

are four commonly used drivers that generate the mechanical waves as follows:<sup>9</sup>

1. Voice coils, also known as pressure activated driver.
2. Electromechanical driver.
3. Piezoelectric stack driver.
4. Focused ultrasound-based radiation force driver.

The most commonly used driver system is voice coils and electromechanical types.

Voice coils or pneumatic system in turn consists of three different components, a non-MRI compatible active driver, an MRI compatible passive driver and a connecting air-filled plastic tube. During operation, a loudspeaker and audio amplifier which forms the active driver, kept outside the MRI scanner room generate continuous acoustic wave motion. The generated signal is transmitted through the connecting air-filled plastic tube to the MRI compatible passive driver kept in contact with the body surface. The passive driver is usually a drum- or disc-shaped device, secured in any desirable position on body surface by rubber straps. For instance, in hepatic applications, the passive driver would be in a transcostal or subcostal position. There are two limitations of voice coils. The first is its susceptibility to delay of transmission of acoustic wave motion, thereby causing poor synchronization with MR sequence. The second is reduction of effectiveness beyond 300 Hz. A diagram of pressure activated driver system is shown in **Fig. 10A**.<sup>3,9</sup>

Electromechanical systems consists of a drive coil which swings around the axis of a horizontal support bar, as represented in **Fig. 10B**. Entire electromechanical system is positioned along the direction of the main magnetic field, away from the region being imaged, usually at a fixed position relative to the main magnetic field. Certain advantages are conferred by using an electromechanical system, over a pneumatic or pressure activated driver system. The

**Table 3** Comparison of strain and shear wave elastography

Characteristic	Strain elastography	Shear wave elastography
Availability	Widely available	Limited availability
Image quality	Excellent	Variable (good to excellent)
Real time imaging capability	Very good	Limited with low frame rates
Depth resolution	Good	Poor
Quantification	Relative using strain ratio	Direct quantification
Application	Better for focal disease	Better for diffuse disease
Operator dependence	Considerable	Negligible

Note: Adapted from Garra.<sup>2</sup>

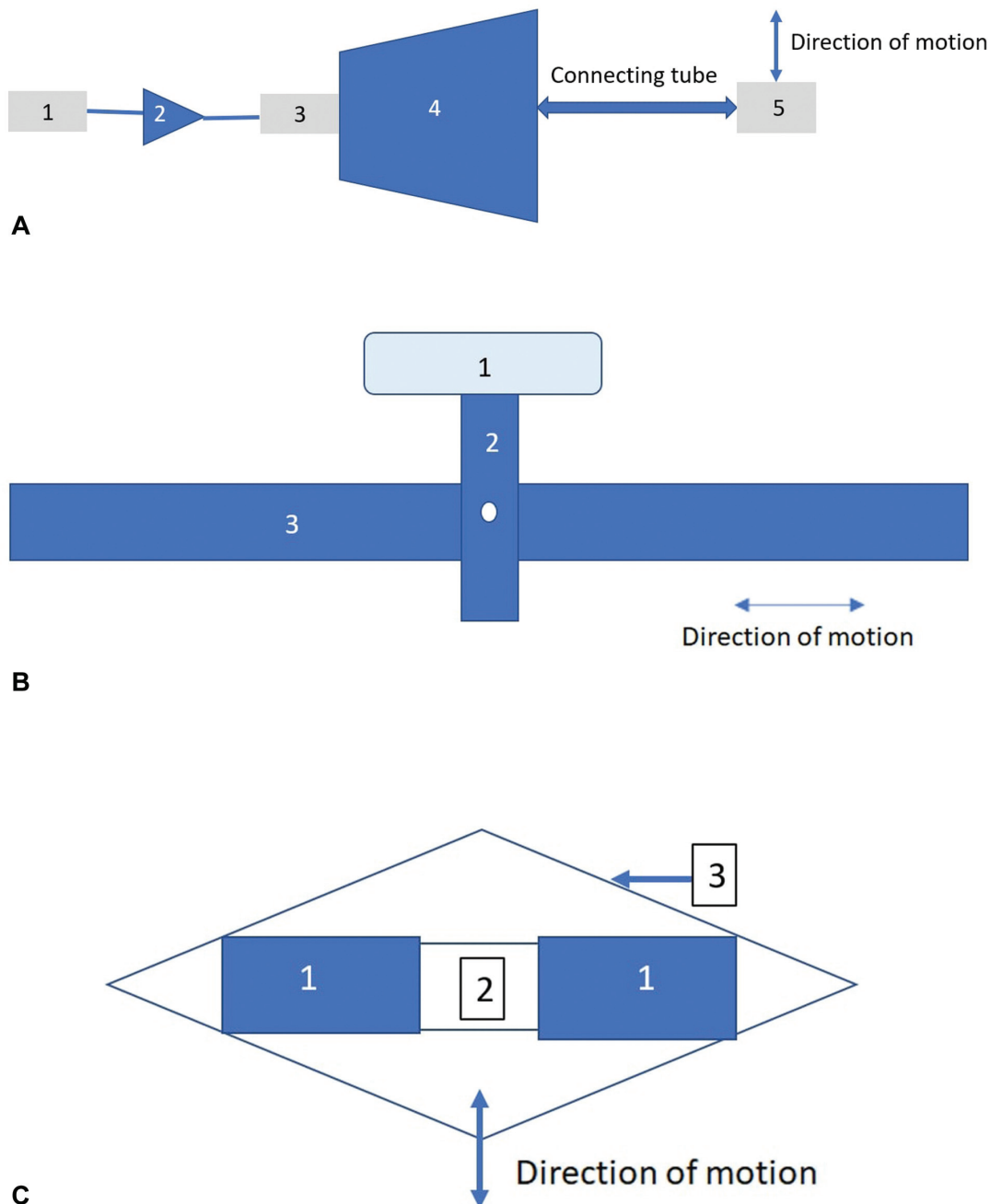
first being better synchronization with the MR sequences. Second, the amplitude of excitation is also much higher than a pressure activated driver system. However, the system is not without certain disadvantages, eddy current is induced in the system, which causes imaging artifacts. Additionally heating effect is reported to be more by using this technique.<sup>3,9,13</sup>

Both piezoelectric stack driver and focused ultrasound-based radiation force driver are sparingly used in literature. Both are based on the principle of mechanical excitation

using ultrasound waves. Both the systems have the advantage of being very stable and precise, in addition to being capable of generating high excitation frequency up to 500 Hz. However, the techniques are comparatively more expensive than the other systems. A diagrammatic representation of the piezoelectric driver system is shown in **Fig. 10C**.<sup>3,9</sup>

### Imaging of Propagating Waves

Shear waves are imaged using phase-contrast MRI (PC MRI), using a special sequence known as oscillating motion



**Fig. 10** (A) Shows the components of a pressure activated driver system. 1 represents the function generator, from where signals originate. 2 represents an audio amplifier. 3 represents a mechanical driver. 4 represents an air-filled cavity. 5 represents the passive driver which moves in vertical direction. (B) Shows the components of an electromagnetic driver system. 1 represents the drive coil, which moves around the axis of a pivot point, represented by the white circle and mounted on a vertical bar, represented by 2. 3 represents a horizontal support bar. (C) Shows the components of a piezo-electric driver system. 1 represents the piezo-stack and 2 represents a spacer. The entire assembly is held in position by a flex-tensional tube, represented in 3. (Adapted from Mariappan et al<sup>9</sup>).

sensitizing gradient (MSG) or motion encoding gradient (MEG). The integration of MSG can be done into a wide variety of sequences, namely, gradient echo (GE), spin echo (SE), balanced steady state free precession (bSSFP), or echo-planar imaging (EPI). All the sequences come with their set of advantages and disadvantages, but gradient echo remains the most preferred sequence in majority of sources. The MSG measures tissue deformity or motion along a specific direction. To be able to accurately measure the motion, the driver system and the MSG have to be set to the same frequency. Usually, MSGs are applied in all three orthogonal planes to capture an entire 3D wave vector.<sup>3</sup>

The underlying working principles of motion encoding are as follows:

- Driver system generates mechanical waves in the body surface.
- The mechanical waves induce the formation of shear waves at the tissue interfaces.
- The shear wave propagates within a solid tissue causing tissue deformity, the velocity of shear propagation being dependent on the viscoelastic properties of that particular tissue.
- Deformation of solid tissue causes cyclical spin displacement of protons.
- Spin displacement is read by synchronized and paired MEGs.
- The spin displacement is encoded by MEG as phase shifts.
- The phase shifts are quantified and encoded using phase contrast MRI.

A simplification of the process described above is given in flow diagram in ►**Fig. 11**. Two important things must be remembered, (1) MEGs are placed between RF excitation of sample and measurement of induced signal, and (2) only MEGs along frequency encoding axis will be encoded into image phase. Two different wave data are generated in this instance, a longitudinal wave and a shear wave. Curl filters or

band pass filters are then applied to remove the longitudinal wave data. Alternatively, some algorithms neglect the smaller longitudinal component in favor of the shear wave.<sup>9</sup>

Temporal relationship between MEG and induced sinusoidal motion of tissue is changed using phase offsets. Typically, three- to eight- phase offsets are used to generate snapshots of the propagating waves. The snapshots of propagating waves are used to generate a spin displacement map or a “wave image” of the shear wave. Several different wave images are generated depending on the duration of phase offset. The wave image is then transformed using post-processing algorithms for generation of an elastogram.<sup>3,16</sup>

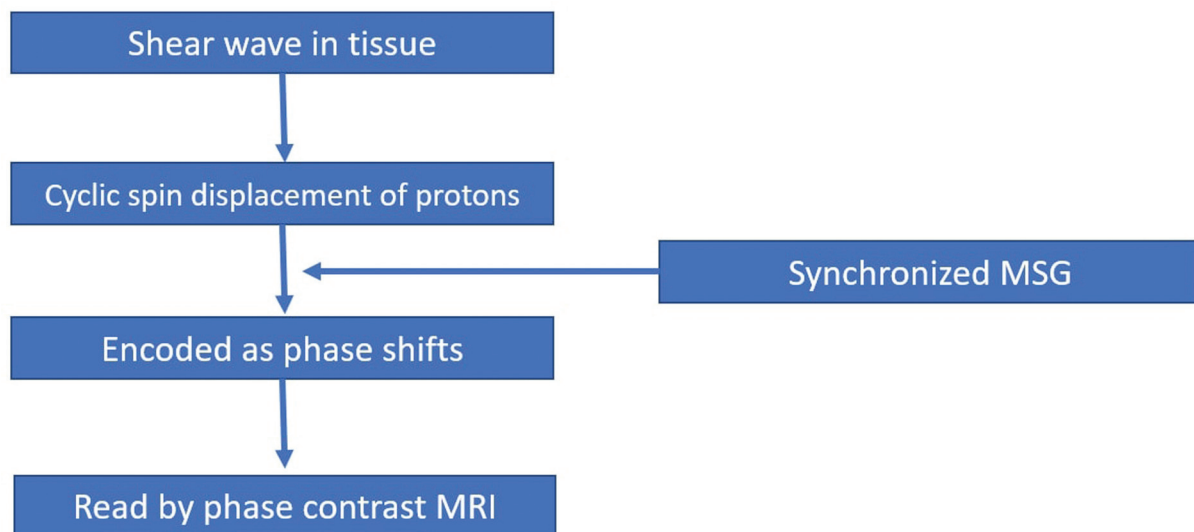
### Estimation of Mechanical Parameters

Mathematical inversion algorithms are applied to the generated wave image for calculation of shear modulus. Two most commonly used inversion algorithms are frequency estimation and algebraic inversion. Regardless of the type of inversion algorithm used, there are two basic assumptions that come into play, one simple and one complex assumption.

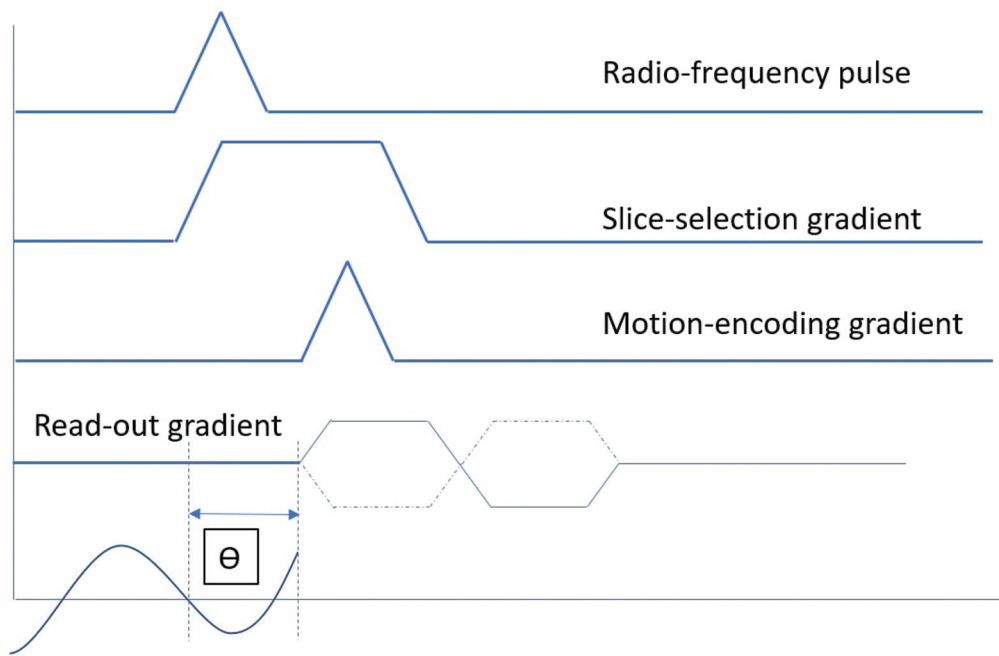
The simple assumption considers the medium propagation to be isotropic, homogeneous, and incompressible. Accordingly, the number of parameters using this assumption are two in number, coefficient of elasticity for longitudinal strain and coefficient of elasticity for shear strain. The complex assumption assumes the wave image as a tensor quantity with as many as 21 variables. To avoid unnecessary hassles, the simple assumption is used in most commercially used algorithms.<sup>16</sup>

Application of inversion algorithms allow for the generation of a color-coded elastogram map. The map is then assessed by placement of ROIs at positions deemed important for obtaining elasticity values. Certain precautions are followed for ROI placement:

- ROI should be farther than half of SWE wavelength from the organ boundary.



**Fig. 11** Flow diagram showing principles of MR elastography. MR, magnetic resonance; MRI, MR imaging; MSG, motion sensitizing gradient.



**Fig. 12** MR elastography GRE sequence. A bipolar gradient is shown for motion encoding gradient, which has a positive component, represented as a solid line and a negative component, represented as a dotted line. The motion waveform and its temporal relationship with phase-offset of  $\Theta$  MR, magnetic resonance.

- ROIs should avoid large vessels.
- ROIs should avoid areas affected by motion artifacts.

A diagrammatic representation of the MR pulse sequence used for elastography is shown in ► **Fig. 12**.<sup>16</sup>

### Limitations of Magnetic Resonance Elastography

MR elastography has limited utility in iron-overload states, especially while using gradient recalled echo (GRE) sequences. In addition, due to the large amount of time required for acquisition, the technique is not suitable for unstable patients. Morbidly obese patients are also a problem due to the fact they cannot be easily accommodated into the scanner. Ferro-metallic objects are contraindicated in MR elastography, just like in other forms of MRI. (Low et al).<sup>3</sup>

There are certain conditions which cause increased stiffness in the absence of significant fibrosis. For instance, in case of liver, acute hepatitis, biliary obstruction, passive congestion secondary to cardiac failure, and hepatic venous outflow tract obstruction can all cause increased hepatic stiffness without significant fibrosis. Similar consideration applies to the kidney as well.<sup>3,9</sup>

### Future Directions

MR elastography suffers from significant degradation of image quality, especially with use of gradient sequences which is a potential area of improvement. MR elastography also suffers from increased duration of acquisition of sequen-

ces for measurement of stiffness.<sup>3</sup> Possibilities that may be explored, include but not limited to the following:

- Smaller K-space acquisition.
- Echo planar or parallel imaging.
- Imaging at higher field strength, greater than or equal to 3 Tesla.
- Faster inversion algorithms.
- 3D and multifrequency techniques.

There is also an urgent need of further research into focal or diffuse diseases beyond the scope of tumor imaging and diseases causing diffuse fibrosis respectively. There is also a dire need to define clinical indications beyond research settings, thus making MR elastography as mainstream as ultrasound elastography.<sup>9</sup>

### Conclusion

Elastography has received considerable attention since its introduction, as a result of its ability to provide mechanical contrast, which has a lot of potential. Elastography can provide information about tissue structure and function in addition to information about stiffness of focal lesions. It remains to be seen whether ultrasound based or MR-based techniques gain popularity in the long run, but both are in many ways complimentary to each other.

#### Funding

None.

#### Conflict of Interest

None declared.

## References

- 1 Ophir J, Cespedes I, Ponnekanti H, Yazdi Y, Li X. Elastography: A quantitative method for imaging the elasticity of biological tissues. *Ultrasonic Imaging* 1991;13(02):111–134
- 2 Garra BS. Elastography: history, principles, and technique comparison. *Abdom Imaging* 2015 Apr;40(04):680–697. Doi: 10.1007/s00261-014-0305-8. PMID: 25637125
- 3 Low G, Kruse SA, Lomas DJ. General review of magnetic resonance elastography. *World J Radiol* 2016 Jan 28;8(01):59–72. Doi: 10.4329/wjr.v8.i1.59. PMID: 26834944; PMCID: PMC4731349
- 4 Elastography - Wikipedia [Internet]. En.wikipedia.org 2021 [cited 22 December 2021]. Available from: <https://en.wikipedia.org/wiki/Elastography>
- 5 Kemp WW, Roberts SK. FibroSca and transient elastography. *Australian Family Physician* 2013;42(07):468–471
- 6 Elert G. Elasticity [Internet]. The Physics Hypertextbook 2021 [cited 22 December 2021]. Available from: <https://physics.info/elasticity/>
- 7 Bamber J, Cosgrove D, Dietrich CF, Fromageau J, Bojunga J, Calliada F, et al. EFSUMB guidelines and recommendations on the clinical use of ultrasound elastography. Part 1: Basic principles and technology. *Ultraschall in der Medizin-European Journal of Ultrasound* 2013 Apr;34(02):169–184
- 8 Cosgrove D, Piscaglia F, Bamber J, Bojunga J, Correas JM, Gilja OH, et al. EFSUMB guidelines and recommendations on the clinical use of ultrasound elastography. Part 2: Clinical applications *Ultraschall in der Medizin-European Journal of Ultrasound* 2013 Jun;34(03):238–253
- 9 Mariappan Y, Glaser K, Ehman R. Magnetic resonance elastography: A review. *Clinical Anatomy* 2010;23(05):497–511
- 10 Ozturk A, Grajo J, Dhyani M, Anthony B, Samir A. Principles of ultrasound elastography. *Abdominal Radiology* 2018;43(04):773–785
- 11 Dawood M, Ibrahim N, Elsaed H, Hegazy N. Diagnostic performance of sonoelastographic Tsukuba score and strain ratio in evaluation of breast masses. *The Egyptian Journal of Radiology and Nuclear Medicine* 2018;49(01):265–271
- 12 Franchi-Abella S, Elie C, Correas J. Ultrasound elastography: Advantages, limitations and artefacts of the different techniques from a study on a phantom. *Diagnostic and Interventional Imaging* 2013;94(05):497–501
- 13 Kwon S, Jeong M. Advances in ultrasound elasticity imaging. *Biomedical Engineering Letters* 2017;7(02):71–79
- 14 Castera L, Forns X, Alberti A. Non-invasive evaluation of liver fibrosis using transient elastography. *Journal of Hepatology* 2008; 48(05):835–847
- 15 Sigrist RMS, Liao J, Kaffas AE, Chammas MC, Willmann JK. Ultrasound Elastography: Review of Techniques and Clinical Applications. *Theranostics* 2017 Mar 7;7(05):1303–1329. Doi: 10.7150/thno.18650. PMID: 28435467; PMCID: PMC5399595
- 16 Manduca A, Bayly PJ, Ehman RL, et al. MR elastography: Principles, guidelines, and terminology. *Magn Reson Med* 2021; 85:2377–2390. <https://doi.org/10.1002/mrm.28627>