

Comparison of Sonography versus Digital Breast Tomosynthesis to Locate Intramammary Marker Clips

Vergleich der Lokalisationsbestimmung der intramammären Clipmarkierung durch Sonografie und digitale Brusttomosynthese

Authors

R. Schulz-Wendtland¹, P. Dankerl², G. Dilbat³, M. Bani⁴, P. A. Fasching⁴, K. Heusinger⁴, M. P. Lux⁴, C. R. Loehberg⁴, S. M. Jud⁴, C. Rauh⁴, C. M. Bayer⁴, M. W. Beckmann⁴, D. L. Wachter⁵, M. Uder², M. Meier-Meitinger¹, B. Brehm¹

Affiliations

The affiliations are listed at the end of the article.

Key words

- ◉ intramammary clip marker system
- ◉ ultrasound-guided core needle biopsy
- ◉ digital breast tomosynthesis (DBT)

Schlüsselwörter

- ◉ intramammäre Clipmarkierung
- ◉ sonografisch gesteuerte Stanzbiopsie
- ◉ digitale Brusttomosynthese (DBT)



Deutschsprachige
Zusatzinformationen
online abrufbar unter:
[www.thieme-connect.de/
ejournals/toc/gebfra](http://www.thieme-connect.de/ejournals/toc/gebfra)

received 22. 8. 2014
revised 8. 11. 2014
accepted 5. 12. 2014

Bibliography

DOI [http://dx.doi.org/
10.1055/s-0034-1396164](http://dx.doi.org/10.1055/s-0034-1396164)
Geburtsh Frauenheilk 2015; 75:
72–76 © Georg Thieme
Verlag KG Stuttgart · New York ·
ISSN 0016-5751

Correspondence

**Prof. Dr. med. Rüdiger
Schulz-Wendtland**
Universitäts-Brustzentrum
Franken
Radiologisches Institut
Universitätsklinikum Erlangen,
CCC ER-EMN
Universitätsstraße 21–23
91054 Erlangen
[ruediger.schulz-wendtland@
uk-erlangen.de](mailto:ruediger.schulz-wendtland@uk-erlangen.de)

Abstract

Introduction: This study aimed to compare the accuracy of sonography versus digital breast tomosynthesis to locate intramammary marker clips placed under ultrasound guidance.

Patients and Methods: Fifty patients with suspicion of breast cancer (lesion diameter less than 2 cm [cT1]) had ultrasound-guided core needle biopsy with placement of a marker clip in the center of the tumor. Intramammary marker clips were subsequently located with both sonography and digital breast tomosynthesis.

Results: Sonography detected no dislocation of intramammary marker clips in 42 of 50 patients (84%); dislocation was reported in 8 patients (16%) with a maximum dislocation of 7 mm along the x-, y- or z-axis. Digital breast tomosynthesis showed accurate placement without dislocation of the intramammary marker clip in 48 patients (96%); 2 patients (4%) had a maximum clip dislocation of 3 mm along the x-, y- or z-axis ($p < 0.05$).

Conclusion: The use of digital breast tomosynthesis could improve the accuracy when locating intramammary marker clips compared to sonography and could, in future, be used to complement or even completely replace sonography.

Zusammenfassung

Einleitung: In dieser Untersuchung sollte die Genauigkeit der Lokalisationsbestimmung der intramammären, sonografiegesteuerten Clipmarkierung sowohl durch Sonografie als auch durch digitale Brusttomosynthese verglichen werden.

Patientinnen und Methoden: Bei 50 Patientinnen wurde bei Verdacht auf ein Mammakarzinom mit einem Durchmesser von kleiner 2 cm (cT1), eine sonografisch gesteuerte Stanzbiopsie mit gleichzeitiger adaptierter Clipmarkierung in das Tumorzentrum durchgeführt. Anschließend wurde eine Lokalisationsbestimmung der intramammären Clipmarkierung sowohl durch Sonografie als auch durch eine digitale Brusttomosynthese durchgeführt.

Ergebnisse: Bei 42 der 50 Patientinnen war sonografisch keine Dislokation der intramammären Clipmarkierung diagnostizierbar (84%), bei 8 Patientinnen (16%) ergab sich eine Dislokation von max. 7 mm in x-, y- bzw. z-Achse. Die digitale Brusttomosynthese zeigte eine exakte Platzierung ohne Dislokation der intramammären Clipmarkierung bei 48 Patientinnen (96%), und hier stellte sich im Unterschied nur bei 2 Patientinnen (4%) eine Dislokation von max. 3 mm in x-, y- bzw. z-Achse dar ($p < 0,05$).

Schlussfolgerung: Der Einsatz der digitalen Brusttomosynthese könnte die Genauigkeit der Lokalisationsbestimmung einer intramammären Clipmarkierung im Vergleich zur Sonografie verbessern und diese in Zukunft ergänzen bzw. ablösen.

Introduction

Around 55 000 women develop breast cancer and 20 000 women die of it in Germany every year [1]. The individual prognosis of patients with breast cancer depends in the first instance on the extent

of disease at the time of diagnosis and on the implemented treatment plan [2–4].

According to both European treatment recommendations and the German interdisciplinary S3 Guideline for the Diagnosis, Treatment and Follow-up of Breast Cancer, at least 70% of all breast

lesions suspicious for malignancy (BI-RADS™ 4/5) should be verified histologically prior to surgery; the ideal would be to verify 90% [5,6]. The goal of preoperative investigation of suspected malignant processes is to ensure that only one surgical procedure will be required subsequently. In addition, all non-palpable breast lesions should be marked prior to the actual surgical procedure (e.g. with ultrasound-guided wire marking) [5,6].

Accurate preoperative ultrasound-guided wire marking is particularly tricky in smaller focal findings with diameters of less than 1 cm. Neoadjuvant therapy concepts represent new challenges for breast surgeons, radiologists and pathologists, as there is no target for preoperative, ultrasound-guided wire marking in patients in complete pathological remission (pCR).

This difficulty can be remedied using a marker clip to locate the primary breast tumor during ultrasound-guided core needle biopsy prior to surgical therapy or neoadjuvant chemotherapy. Clip marking of the primary tumor should be done together with the ultrasound-guided core needle biopsy to reduce re-excision rates [7–10].

Based on the findings of our previous studies and using a clip marking system we helped to develop and establish [11, 12], we investigated the accuracy of an innovative clip marking method in patients with breast cancer (cT2) scheduled to undergo neoadjuvant chemotherapy [13]. Our results confirmed that the innovation we had developed had precisely adapted the stylet length of the marking system to the single-use breast biopsy system (HistoCore™). Previously, when using the O-Twist Marker™ clip system, a pre-fabricated sliding spacer was placed directly around the stylet, and the notch length of the spacer used during marker clip placement (pushed forward through the coaxial biopsy needle in situ) had to be varied for every intervention, depending on the respective length of the biopsy needle. This approach was imprecise and semi-subjective because it was not possible to adjust the fitted spacer precisely using only the marking ring engraved at intervals of one centimeter. Our innovation offered the possibility of placing a precise marker clip for every biopsy needle length without requiring a spacer. This creates a target point for preoperative ultrasound-guided wire marking, which is particularly useful in patients in pathological complete remission (pCR) after neoadjuvant chemotherapy [7–10].

If standard control mammography (two orthogonal planes, cranio-caudal and medio-lateral oblique views) is done after stereotactic vacuum biopsy with clip marking [9], the question arises whether it is possible to detect dislocation of an intramammary marker clip after ultrasound-guided core needle biopsy with clip placement. Based on our previous experience [11–14] with intramammary clip marking systems, the aim of our current study was to investigate the accuracy of sonography and digital breast tomosynthesis to determine the location of intramammary marker clips placed in small breast cancers with diameters of less than 2 cm (cT1).

Material and Methods



Patient population

Between June 2013 and November 2013 50 patients with a suspicion of invasive breast cancer and focal findings with diameters of less than 2 cm (cT1, BI-RADS™ 4/5) were investigated at the

University Breast Center Franconia, using complementary breast diagnostics consisting of clinical examination, mammography (Selenia Dimensions3D™ [Hologic™]) and sonography (2-D, Acuson Antares, 13 MHz [Siemens™]). Lesion diameters ranged from 0.4 to 1.6 cm (median 0.9 cm) and patient age range was 31–77 years (median 54 years).

Ultrasound-guided core needle biopsy and clip marking

Invasive breast cancer was confirmed histologically in all 50 patients by ultrasound-guided core needle biopsy using a single-use breast biopsy system (HistoCore™, BIP™ Biomedizinische Instrumente & Produkte GmbH, Germany) [11]. Patients then underwent breast-conserving surgery without prior neoadjuvant chemotherapy. Intramammary clip marking was additionally done using a directly adapted clip system based on the established O-Twist Marker™ system (BIP™ Biomedizinische Instrumente & Produkte GmbH, Germany) [12, 13]. All ultrasound-guided core needle biopsies and clip markings were performed by the same two experienced investigators (RSW, BB) to exclude potential inter-investigator variability.

A single-use breast biopsy system (HistoCore™) was used with a 12-gauge, 10-cm outer cannula and a needle advance of 18 or 25 mm. After careful disinfection of the skin and administration of a local anesthetic, the single-use breast biopsy system (combination of a coaxial cannula [11 gauge] and the core biopsy needle [12 gauge]) was placed over the focal tumor. Core needle biopsy was carried out under ultrasound control tangentially to the linear 13.0-MHz transducer. The length of the needle was documented before and after the intervention on pictures and on video. Four or more core needle biopsy specimens were obtained to secure sufficient material for histological diagnosis and molecular-genetic testing. Using the coaxial needle (11 gauge) and the adapted clip system (O-Twist Marker™), a clip was placed directly in the puncture site, i.e. in the middle of the tumorous lesion, under “real-time” ultrasound guidance for subsequent control investigations of clip localization.

Location control of marker clips using sonography and digital breast tomosynthesis

Location of the intramammary marker clip was controlled by sonography (2-D, Acuson Antares, 13 MHz [Siemens™]) and digital breast tomosynthesis (Selenia Dimensions 3D™ [Hologic™]) approximately 30 minutes after the intervention. A compression bandage was used in all patients to minimize hematoma formation. As part of our study, digital breast tomosynthesis with the same radiation dose was performed in each patient (after informed consent) instead of control mammography (two orthogonal planes, cranio-caudal and medio-lateral oblique view), as recommended in the German interdisciplinary S3 Guideline for the Diagnosis, Therapy and Follow-up Care of Breast Cancer [6, 15]. Measurements were also carried out by the same two investigators (RSW, BB) to reduce inter-investigator variability.

Statistical analysis

SPSS 18.0 was used for statistical analysis. Data were initially analyzed descriptively and subsequently assessed for statistically relevant differences between investigated groups. The level of significance was $p < 0.05$.

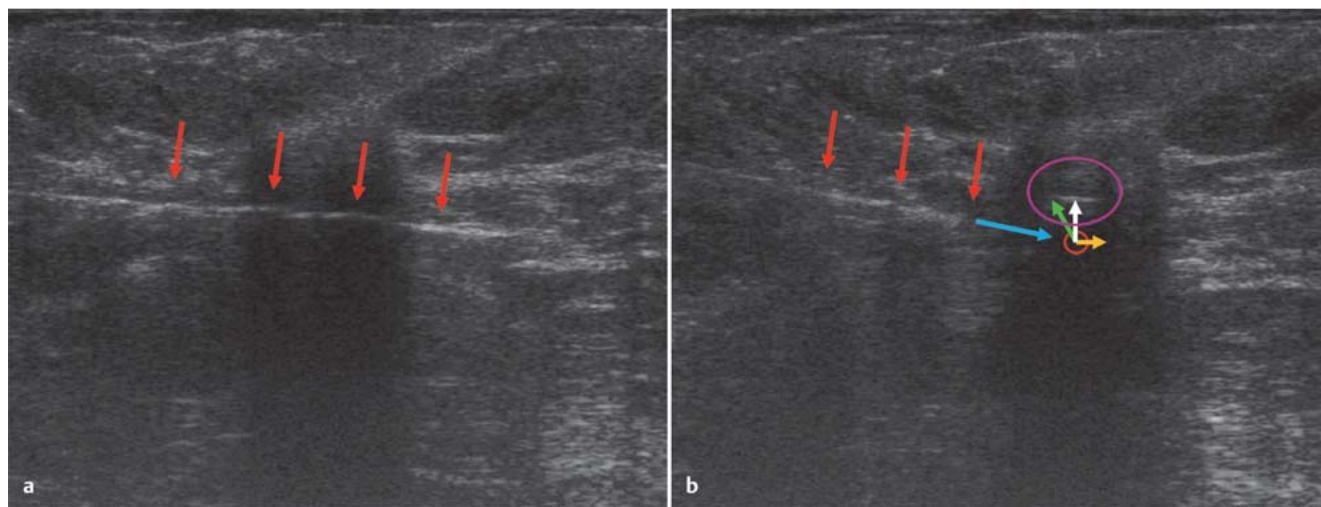


Fig. 1 a and b a Ultrasound-guided core needle biopsy of a breast cancer lesion (cT1). The biopsy needle is precisely in the center of the focal tumor (red arrow) (2D, Acuson Antares, 13 MHz (Siemens™), magnification: 3×). b Ultrasound localization of the intramammary marker clip. The biopsy needle tip is sited directly above the focal tumor (red arrows) (2D, Acuson Antares, 13 MHz [Siemens™], magnification: 3×) after placement of the marker

clip (red circle). Virtual extension of the direction of dislocation of the marker clip (light blue arrow); position of the marker clip (purple circle); dislocation of the marker clip (3D reconstruction) by 2 mm along the x-axis (white arrow), by 1 mm along the y-axis (yellow arrow), by 3 mm along the z-axis (green arrows) (dislocation).

Results

Comparison of sonography versus digital breast tomosynthesis to locate intramammary marker clips

After placing the marker clip in the center of each tumor, the location of the marker clip was controlled using both ultrasound and digital breast tomosynthesis (• Figs. 1 and 2). No dislocation of the marker clip after removal of the clip applicator was observed during ultrasound monitoring.

In 42 of 50 patients (84%), ultrasound (measurement of the tumor without the echo-rich margin) detected no dislocation of the marker clip. In eight patients (16%) ultrasound control indicated a maximum dislocation of 7 mm along the x-, y- or z-axis (• Table 1).

Digital breast tomosynthesis showed precise placement without dislocation of the marker clip in 48 patients (96%); a maximum dislocation of 3 mm along the x-, y- or z-axis was found in two patients (4%) (• Table 1). In six patients (12%) ultrasound wrongly indicated dislocation of the marker clip. The reason for this was probably that the tumor size in these patients was between 0.4 and 0.7 cm (median 0.6 cm).

The difference in the accuracy of the two imaging techniques to locate marker clips was statistically significant ($p < 0.05$). The intratumorous location of the marker clip was confirmed both by specimen x-ray done intraoperatively and by the subsequent histopathological examination of the tumor. All patients underwent breast-conserving therapy, and specimen x-rays were correlated with findings of digital breast tomosynthesis and histopathological examination of the specimens.

Discussion

The aim of this study was to investigate the accuracy of different imaging techniques when determining the precise position of marker clips placed directly in the center of intramammary lesions with diameters of less than 2 cm (cT1). Our recent develop-

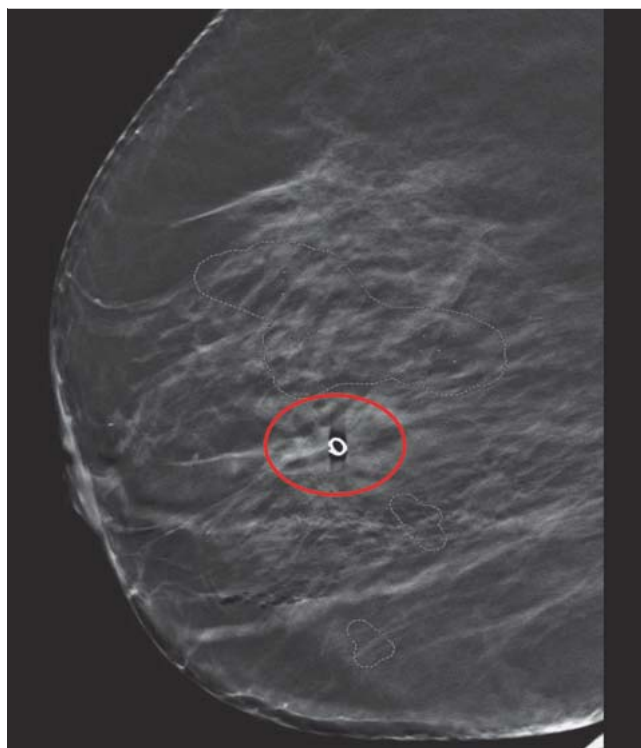


Fig. 2 Localization of the intramammary marker clip using digital breast tomosynthesis in the same patient as in • Fig. 1. The sharply delineated marker clip (circle) is located directly in the center of the lesion; no dislocation has occurred (Selenia Dimensions 3D™ [Hologic™] with CAD™ [R2™]). Secondary findings include three areas with micro-calcifications (dotted lines).

ment, which combines a single-use core biopsy needle with a precisely adapted clip marker system for the placement of marker clips through a coaxial needle in situ, allows clips to be placed accurately even in small lesions (cT1). Control imaging us-

Table 1 Measured dislocation of the intramammary marker clip in mm (along the x-, y- and z-axis); dislocation was observed in 8 patients using ultrasound and in 2 patients using digital breast tomosynthesis (DBT). The intratumorous location of the marker clip was confirmed by specimen x-ray (SX) and histopathological examination (Histo.) (out of a total of 50 examined patients).

Patient no.	Ultrasound			DBT			SX	Histo.
	X	Y	Z	X	y	z		
1	1	2	3	0	0	0	✓	✓
2	5	3	3	0	0	0	✓	✓
3	4	6	5	0	0	0	✓	✓
4	5	7	6	0	0	0	✓	✓
5	1	2	2	0	0	0	✓	✓
6	1	3	5	0	0	0	✓	✓
7	7	1	2	0	0	0	✓	✓
8	1	6	4	0	1	3	✓	✓
9	0	0	0	1	1	2	✓	✓

ing ultrasound and digital breast tomosynthesis to verify the position of the marker clip additionally confirmed the high diagnostic accuracy of digital breast tomosynthesis.

Ultrasound-guided core needle biopsy is currently the standard approach for the diagnostic workup of unclear lesions in the breast. Several studies have shown that an identical or higher degree of diagnostic certainty can be achieved with ultrasound-guided core needle biopsy compared to open biopsy of palpable and non-palpable findings, as the latter are associated with false-negative rates of between 0.3 and 8.2% [16, 17]. Other studies have shown that local rates of recurrence and the intervals to tumor recurrence did not differ between patients diagnosed using ultrasound-guided core needle biopsy and those diagnosed by primary surgical intervention [18–21].

The advantages of ultrasound-guided core needle biopsy, which can be carried out with little expenditure of time, are its limited invasiveness and lower costs [22, 23]. Knowledge of the tumor's histological characteristics allows better planning of surgical operations, if surgery is required, and a more targeted intervention, particularly with regard to axillary sentinel lymph node biopsy. This is reflected in the lower rates of follow-up surgeries for incomplete tumor resection [24]. As around three quarters of masses detected on imaging are benign, this can prevent unnecessary surgical interventions, provided that the assessment of the images of the lesion concurs with the histological findings. Although ultrasound is a well-established diagnostic method, the range of indications and the value of digital breast tomosynthesis has not yet been precisely determined [15, 25–27].

Digital image acquisition, image processing and image reproduction allows many sequences of images to be acquired within a short time. The compilation of sequentially acquired tomograms is used to create three-dimensional images of the breast, so-called digital breast tomosynthesis [25]. The radiation exposure parameters for every plane are selected to ensure that total radiation exposure corresponds to the radiation dose of two-plane mammography. Various reconstruction algorithms are used to display the breast as a series of slices at different depths or as a freely rotatable 3-dimensional image. Digital breast tomosynthesis thus redresses one of the limitations of mammography, namely, the reduction of the three-dimensional breast to a two-dimensional image [25]. Digital breast tomosynthesis should therefore be able to avoid false-positive or false-negative findings which are the result of superimpositions created with mammography. This should improve detection rates in mammographically denser breasts [15]. Digital breast tomosynthesis also appears to

be superior to both sonography and mammography for the determination of the size of breast tumors [15]. Other authors have shown that the recall rate for mammography screening was reduced when mammography was combined with tomosynthesis [28–31].

Our findings show that determination of the location of marker clips placed after ultrasound-guided core needle biopsy is significantly more precise using digital breast tomosynthesis compared to ultrasound. One reason for this could be because digital breast tomosynthesis is standardized compared to elastography or ultrasound, where the application is semi-subjective, irrespective of whether it is 2-D, 3-D, or 4-D imaging [32, 33]. It remains to be seen whether modern three-dimensional ultrasound systems such as the Automated Breast Ultrasound Scanner (ABVS) will improve the results of conventional two-dimensional ultrasound even more [34, 35].

Conclusion



Digital breast tomosynthesis is a good example of recent developments in breast imaging techniques. These developments continue to improve the quality of diagnostics and the therapy of breast cancer while reducing the rate of surgical re-excisions, particularly for small breast cancer tumors or after neoadjuvant chemotherapy with subsequent pathological complete remission (pCR). The findings of our study on locating intramammary marker clips has expanded the range of indications for digital breast tomosynthesis.

Conflict of Interest



None.

Affiliations

- ¹ Gynäkologische Radiologie, Radiologisches Institut + Universitätsklinikum Erlangen, Erlangen
- ² Radiologisches Institut, Universitätsklinikum Erlangen, Erlangen
- ³ Radiologie, Radiologie Roth, Roth
- ⁴ Frauenklinik, Universitätsklinikum Erlangen, Erlangen
- ⁵ Pathologisches Institut, Universitätsklinikum Erlangen, Erlangen

References

- 1 Robert Koch-Institut. Krebs in Deutschland 2005/2006. Häufigkeiten und Trends, Gesundheitsberichterstattung des Bundes. Berlin: Robert Koch-Institut, Gesellschaft der epidemiologischen Krebsregister in Deutschland e.V.; 2010
- 2 Eisemann N, Waldmann A, Katalinic A. Epidemiology of breast cancer – current figures and trends. *Geburtsh Frauenheilk* 2013; 73: 130–135
- 3 Lux MP, Maas N, Schütz F et al. Breast cancer 2013 – interpretation of new and known data. *Geburtsh Frauenheilk* 2013; 73: 584–598
- 4 Fasching PA, Ekici AB, Wachter DL et al. Breast cancer risk – from genetics to molecular understanding of pathogenesis. *Geburtsh Frauenheilk* 2013; 73: 1228–1235
- 5 Wallis M, Tardivon A, Helbich T et al. Guidelines from the European Society of Breast Imaging for diagnostic interventional breast procedures. *Eur Radiol* 2007; 17: 581–588
- 6 Kreienberg R, Albert US, Follmann M et al. Interdisciplinary GoR level III Guidelines for the Diagnosis, Therapy and Follow-up Care of Breast Cancer. Short version – AWMF Registry No.: 032-0450L. *Geburtsh Frauenheilk* 2013; 73: 556–583
- 7 Liberman L, Dershaw DD, Morris EA et al. Clip placement after stereotactic vacuum-assisted breast biopsy. *Radiology* 1997; 205: 417–422
- 8 Rosen EL, Vo TT. Metallic clip deployment during stereotactic breast biopsy: retrospective analysis. *Radiology* 2001; 218: 510–516
- 9 Schulz-Wendtland R, Heywang-Kobrunner SH, Aichinger U et al. [Do tissue marker clips after sonographically or stereotactically guided breast biopsy improve follow-up of small breast lesions and localisation of breast cancer after chemotherapy?]. *Rofo* 2002; 174: 620–624
- 10 Schulz-Wendtland R. Neoadjuvant chemotherapy–monitoring: clinical examination, ultrasound, mammography, MRI, elastography: only one, only few or all? *Eur J Radiol* 2012; 81 (Suppl. 1): S147–S148
- 11 Schulz-Wendtland R, Dilbat G, Bani MR et al. [HistoCore® – a new single-use breast biopsy system of the next generation in daily clinical routine]. *Senologie* 2010; 7: 265–268
- 12 Sittek H, Heske N, Kessler M et al. [O-twist marker for post-interventional marking in imaging of suspected breast lesions]. *Radiologe* 2005; 45: 223–229
- 13 Schulz-Wendtland R, Dankerl P, Dilbat G et al. Evaluation of newly adapted clip marker system in ultrasound-guided core needle biopsy for suspicion of breast cancer. *Geburtsh Frauenheilk* 2013; 73: 1135–1138
- 14 Schulz-Wendtland R, Dilbat G, Bani M et al. Full field digital mammography (FFDM) versus CMOS technology, specimen radiography system (SRS) and tomosynthesis (DBT) – which system can optimise surgical therapy? *Geburtsh Frauenheilk* 2013; 73: 422–427
- 15 Houssami N, Skaane P. Overview of the evidence on digital breast tomosynthesis in breast cancer detection. *Breast* 2013; 22: 101–108
- 16 Zannis VJ, Aliano KM. The evolving practice pattern of the breast surgeon with disappearance of open biopsy for nonpalpable lesions. *Am J Surg* 1998; 176: 525–528
- 17 Pijnappel RM, van den Donk M, Holland R et al. Diagnostic accuracy for different strategies of image-guided breast intervention in cases of nonpalpable breast lesions. *Br J Cancer* 2004; 90: 595–600
- 18 Kopans DB, Gallagher WJ, Swann CA et al. Does preoperative needle localization lead to an increase in local breast cancer recurrence? *Radiology* 1988; 167: 667–668
- 19 Diaz LK, Wiley EL, Venta LA. Are malignant cells displaced by large-gauge needle core biopsy of the breast? *AJR Am J Roentgenol* 1999; 173: 1303–1313
- 20 King TA, Hayes DH, Cederbom GJ et al. Biopsy technique has no impact on local recurrence after breast-conserving therapy. *Breast J* 2001; 7: 19–24
- 21 Hoorntje LE, Schipper ME, Kaya A et al. Tumour cell displacement after 14 G breast biopsy. *Eur J Surg Oncol* 2004; 30: 520–525
- 22 Liberman L, Feng TL, Dershaw DD et al. US-guided core breast biopsy: use and cost-effectiveness. *Radiology* 1998; 208: 717–723
- 23 Gruber R, Bernt R, Helbich TH. [Cost-effectiveness of percutaneous core needle breast biopsy (CNBB) versus open surgical biopsy (OSB) of non-palpable breast lesions: metaanalysis and cost evaluation for German-speaking countries]. *Rofo* 2008; 180: 134–142
- 24 Liberman L, LaTrenta LR, Dershaw DD. Impact of core biopsy on the surgical management of impalpable breast cancer: another look at margins. *AJR Am J Roentgenol* 1997; 169: 1464–1465
- 25 Schulz-Wendtland R, Wenkel E, Lell M et al. Experimental phantom lesion detectability study using a digital breast tomosynthesis prototype system. *Rofo* 2006; 178: 1219–1223
- 26 Schulz-Wendtland R, Hermann KP, Wacker T et al. [Current situation and future perspectives of digital mammography]. *Radiologe* 2008; 48: 324–334
- 27 Schulz-Wendtland R, Wenkel E, Wacker T et al. Quo vadis? Trends in digital mammography. *Geburtsh Frauenheilk* 2009; 69: 108–117
- 28 Skaane P, Bandos AI, Gullien R et al. Prospective trial comparing full-field digital mammography (FFDM) versus combined FFDM and tomosynthesis in a population-based screening programme using independent double reading with arbitration. *Eur Radiol* 2013; 23: 2061–2071
- 29 Skaane P, Bandos AI, Gullien R et al. Comparison of digital mammography alone and digital mammography plus tomosynthesis in a population-based screening program. *Radiology* 2013; 267: 47–56
- 30 Ciatto S, Houssami N, Bernardi D et al. Integration of 3D digital mammography with tomosynthesis for population breast-cancer screening (STORM): a prospective comparison study. *Lancet Oncol* 2013; 14: 583–589
- 31 Heywang-Kobrunner S, Bock K, Heindel W et al. Mammography screening – as of 2013. *Geburtsh Frauenheilk* 2013; 73: 1007–1016
- 32 Weismann C, Mayr C, Egger H et al. Breast sonography – 2D, 3D, 4D ultrasound or elastography? *Breast Care* 2011; 6: 98–103
- 33 Weismann CF, Forstner R, Prokop E et al. Three-dimensional targeting: a new three-dimensional ultrasound technique to evaluate needle position during breast biopsy. *Ultrasound Obstet Gynecol* 2000; 16: 359–364
- 34 Golatta M, Franz D, Harcos A et al. Interobserver reliability of automated breast volume scanner (ABVS) interpretation and agreement of ABVS findings with hand held breast ultrasound (HHUS), mammography and pathology results. *Eur J Radiol* 2013; 82: e332–e336
- 35 Wojcinski S, Gyapong S, Farrokh A et al. Diagnostic performance and inter-observer concordance in lesion detection with the automated breast volume scanner (ABVS). *BMC Med Imaging* 2013; 13: 36