

# A Staged Treatment Algorithm for Spinal Infections

Carsten Stürer<sup>1,2</sup> Michael Stoffel<sup>1,2</sup> Judith Hecker<sup>2</sup> Florian Ringel<sup>1,2</sup> Bernhard Meyer<sup>1,2</sup>

<sup>1</sup>Department of Neurosurgery, Technische Universität München, Klinikum rechts der Isar, Munich, Germany

<sup>2</sup>Department of Neurosurgery, Rheinische-Friedrich-Wilhelms University Bonn, Bonn, Germany

**Address for correspondence** Carsten Stürer, MD, Department of Neurosurgery, Klinikum rechts der Isar, Ismaningerstr. 22, Munich 81675, Germany (e-mail: carsten.stueer@lrz.tum.de).

J Neurol Surg A 2013;74:87–95.

## Abstract

**Background and Study Aim** Spinal pyogenic infections occur frequently in today's neurosurgical routine. Conservative therapy often proves to be insufficient against an aggressive disease that affects patients who tend to be elderly and debilitated with complex comorbidity. Treatment, or lack of treatment, carries risks of persistent disability, sepsis, and death. In this study, we propose a tailored and staged algorithm for treating such spinal infections and present results of this approach.

**Patients and Methods** We retrospectively analyzed 52 patients (33 male, 19 female; median age: 68 years) who had undergone cervical, thoracic, or lumbar surgery for spinal infections according to the proposed staged treatment algorithm.

**Results** Most of the 52 patients were severely disabled (35% with quadri- or paraparesis, 31% with sepsis and catecholamine dependency, 17% with a single motor deficit, and 10% with meningitis). We surgically treated multilevel and multisegmental spinal infections via 23 nonstabilizing and 57 stabilizing ventral or dorsal approaches to the cervical, thoracic, or lumbar spine. The mean follow-up time was 24 months. Overall mortality was 19%. Surgery-related complications occurred in 11.5% of patients; recurrence of infection occurred in 3.8%. Motor function improved in 61.7%; bladder and sphincter dysfunction remitted completely in 50.0%.

**Conclusions** Depending on the patient's health status and neurological condition, surgery in complex spinal infections provides a good outcome in most cases. Nevertheless, indication must be individualized; for this, the proposed algorithm seems to be an excellent tool. We find that surgery should be discussed as a treatment of first choice for today's often complex spinal infections.

## Keywords

- ▶ spinal infections
- ▶ septic osteomyelitis
- ▶ elderly patients
- ▶ comorbidity
- ▶ spinal stabilization

## Introduction

In the late 1970s, the incidence of spontaneous pyogenic spinal infections was estimated to be 1 in 250,000, and 5.5 in 250,000 in the late 1980s, but a further rise was confirmed by several studies of the past 15 years.<sup>1–4</sup> In Germany from 1999 to 2003, hospital admissions due to infection of the vertebral

column rose continuously from 5800 to 6700 per 80,000,000 inhabitants per year.<sup>5</sup>

While spinal infections as an iatrogenic complication of spinal surgery remain at less than 3%, simple forms of infection in elderly, debilitated patients, and infectious complications of the spine following minimally invasive spinal procedures such as intramuscular, peridural, or intrathecal

received

June 13, 2011

accepted after revision

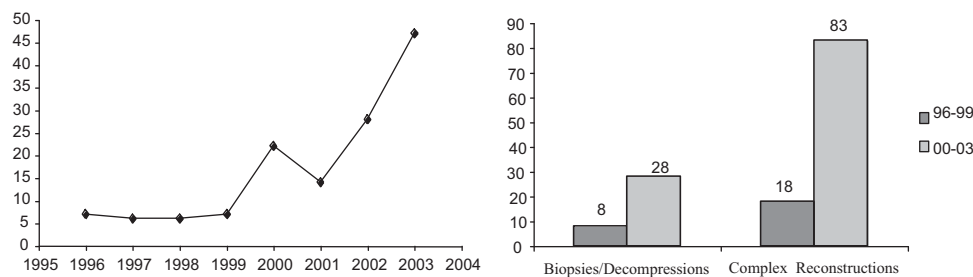
February 15, 2012

published online

February 12, 2013

© 2013 Georg Thieme Verlag KG  
Stuttgart · New York

DOI <http://dx.doi.org/10.1055/s-0032-1320022>.  
ISSN 2193-6315.



**Fig. 1** The increasing amount of operative therapies at our institution is remarkable (left). The number of simple (transpedicular biopsy, decompression) and complex (dorsoventral stabilization, corporectomy, etc.) procedures approximately quadruplicated in 2000 to 2003 compared with 1996 to 1999 (right).

injections seem to have increased<sup>6</sup>; thus at our institution, simple and complex reconstructive spinal surgery has quadrupled within the past 5 years (►Fig. 1).

Pyogenic infection most commonly affects the lumbar spine (48 to 60%), followed by the thoracic spine (23 to 36%), and the cervical spine (10 to 18%).<sup>3,7</sup> Herewith, several entities must be distinguished: 1. Isolated infections of the intraspinal compartments presenting as epidural or subdural empyemas and pyogenic myelitis (very rare). 2. Isolated infections of the vertebral column itself (vertebral body and disc space) presenting as spondylitis and spondylodiscitis. 3. Combined spinal/intraspinal/paraspinal infections.

The optimal strategy for treating spinal pyogenic infections remains controversial. Because patients' concomitant diseases may cause a high rate of surgical morbidity and mortality, many authors propose conservative therapy (bed rest, intravenous antibiotics, and external immobilization)<sup>8</sup> and recommend surgical treatment only for patients with neurologic deterioration, failed conservative therapy, and spinal instability or deformity.<sup>9-12</sup>

Usually, spontaneous spinal infections involve immunocompromised elderly patients suffering from diabetes mellitus, chemotherapy, or cardiac risk factors, and young patients with HIV infection or intravenous drug abuse.<sup>9,13,14</sup> In such patients, a surgical approach without taking comorbidities or septic conditions into account might result in prolonged hospital stays and associated increased morbidity and high mortality, respectively.<sup>15</sup>

Our institution is aiming for a treatment strategy tailored for the patient's general condition ("Grading of patients for surgical procedures" by American Society of Anesthesiologists (ASA), Karnofsky, comorbidity) and for the clinical and radiological extent of disease. The purpose of this study was to retrospectively evaluate the results of the surgical arm of this management strategy.

## Patients and Methods

### Patient Population

We retrospectively analyzed the hospital and outpatient clinic charts of all adult patients operated on for pyogenic spinal infection between January 2000 and December 2003. Patients with previous surgery for lumbar disc herniation, spinal infections secondary to other spinal surgical procedures, and patients with successful conservative treatment

were excluded. Diagnosis was established with compatible (1) image findings on magnetic resonance imaging (MRI)/computed tomography (CT), (2) clinical picture (local/radicular pain, deficit, laboratory findings), and (3) pre- or postoperative microbiological evidence of a causative agent. All data were stored in a data bank of a commercially available personal computer for offline analysis. Patient data extracted were demographic data, signs, symptoms, and neurological findings. Furthermore, we assessed comorbidities, extent of infection, laboratory test findings, surgical treatment, duration of hospital stay, kind and duration of antibiotic treatment, and outcome (surgical and neurological complications, infection, and pain).

### Operative Treatment

Our basic strategy was to favor surgery except in two types of situations: if patients are oligosymptomatic, and if patients are in septic condition with catecholamine dependency. In such cases, we favored conservative treatment (►Fig. 2). The underlying algorithm for surgery of spinal infections is provided in ►Fig. 2 and explained in the caption.

The used surgical approaches to the cervical, thoracic, and lumbar spine are shown in ►Table 1.

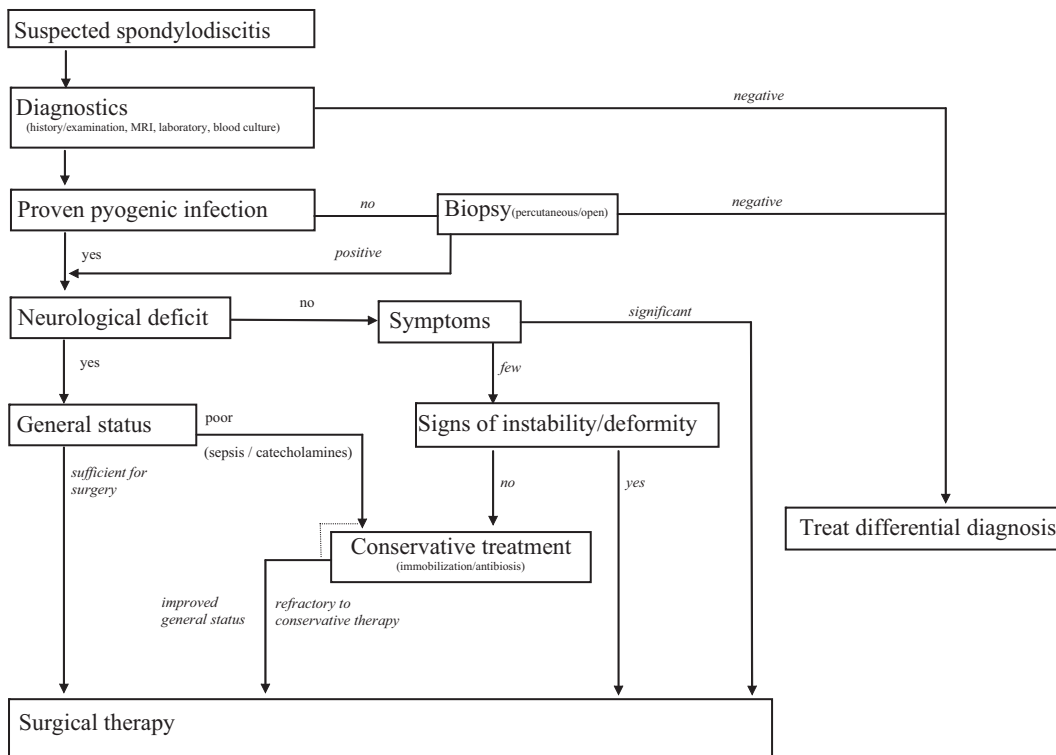
## Results

### Demographic Data, Signs, Symptoms, and Neurological Findings

A total of 52 patients (33 male and 19 female) with a median age of 68 years (range: 27 to 84) underwent cervical, thoracic, or lumbar surgery. The median duration from onset of symptoms to hospital admission was 24 days (range: 4 to 500 days). The median preoperative Karnofsky score at hospital admission was 60 (range: 30 to 90). The signs, symptoms, and neurological findings (including Frankel neurological performance scale) at admission were as shown in ►Table 2.<sup>16</sup> Sixteen patients (30.8%) had undergone previous therapeutic procedures (i.e., infiltration of facet joints, epidural catheterization, or intramuscular injections), and 16 patients (30.8%) had been treated conservatively before admission.

### Comorbidities, Extent of Infection, and Laboratory Test Findings

Comorbidity was as shown in ►Fig. 3. Preoperative laboratory testing (erythrocyte sedimentation rate, C-reactive protein,



**Fig. 2** Synopsis of the staged treatment algorithm for patients harboring spinal pyogenic infections with/without neurological deficit depending on their health status. Provided that clinical diagnostics—history, examination, magnetic resonance imaging, and blood results—leave no doubt of an underlying spinal infection, our operative strategy follows a staged policy. In unclear cases, pyogenic infection of the spine is to be proven by open/percutaneous biopsy of the segment. After confirmation, further strategy depends on whether a neurological deficit exists. Neurological deterioration, spinal instability, and a refractory course of disease demand operative treatment (internal immobilization, eradication of the infected focus, and fusion), usually a complex dorsoventral reconstruction. Patients without neurological deficit but with significant symptoms due to the infection are chosen for surgery; conservative treatment is indicated in oligosymptomatic patients. Conservative refractory disease, spinal instability or deformity, or progressive development of septic conditions (dotted line) leads to surgery. Patients with neurological deficit and stable health status can be operated on. We first treat those with massively impaired health status, septic conditions, or catecholamine dependency conservatively. In case of recovery and improvement of health status, surgery is indicated and performed to eradicate the infected focus.

**Table 1** Surgical strategy of spinal infections

Segment	Procedure
Cervical spine	
> Atlantodental joint	Dorsal C1/2 stabilization (lateral mass/isthmic screws) and additional reposition
> Subaxial cervical spine (with discitis)	Mono/bisegmental > ACD + cage
	> Corporectomy + cage/iliac-crest bone + osteosynthesis
	Multisegmental
	> Dorsal decompression + stabilization, or
	> Corporectomy + dorsal stabilization (in case of ventral mass)
Thoracic and lumbar spine	Mono- and multisegmental
> Intraspinal empyema	> Dorsal decompression + evacuation
> Discitis	> Stabilization + PLIF (with autograft bone)
> Discitis and septic liquefaction of endplates	> Stabilization and ventral interbody fusion (AIF with xenograft) in a second surgical step after some days of recovery

ACD, anterior cervical decompression; AIF, anterior interbody fusion; PLIF, posterior lumbar interbody fusion.

**Table 2** Summary of signs and symptoms of the spinal infection leading to hospital admission

Symptoms	Number of patients (%)
Back pain/radicular pain	33 (63.5)/27 (51.9)
Single motor <sup>a</sup> /sensory deficit	7 (13.5)/5 (9.6)
Paraparesis	13 (25.0)
Quadriparesis	5 (9.6)
Bladder/sphincterdysfunction	16 (30.8)
Meningitis	5 (9.6)
Sepsis	17 (32.7)

Sepsis is defined as body temperature > 39°C, cardiovascular impairment or subject to catecholamines, or germ-positive blood cultures. <sup>a</sup>According to the Frankel neurological performance scale: Grade A (complete neurological injury) 5.8% (3 patients). Grade B (preserved sensation only) 0%. Grade C (paresis, nonfunctional) 25.0% (13 patients). Grade D (paresis, functional) 51.9% (27 patients), Grade E (normal motor function) 15.3% (8 patients).

and white-blood-cell count) was pathologic in 31 patients (60.0%). Eight patients (15.4%) had a multilevel pyogenic spinal infection. The extent of spinal infections was found as shown in ▶Table 3. Blood cultures from the septic patients were all without affirmative evidence of any causative agent according to the previous antibiotic treatment. Altogether (including the microbiological findings of the referring hospitals), positive bacteriological cultures were achieved in 42 patients (80.8%) (▶Fig. 4).

**Surgical Treatment**

As a primary therapy 36 patients (69.2%) underwent surgery. In 16 cases (30.8%), surgery was the secondary therapy because of progress of infection and neurological deterioration following conservative treatment. Because of an initially uncertain diagnosis, 12 patients were biopsied transpedicularly for microbiological evaluation.

**Table 3** Summary of the extent of the spinal infection

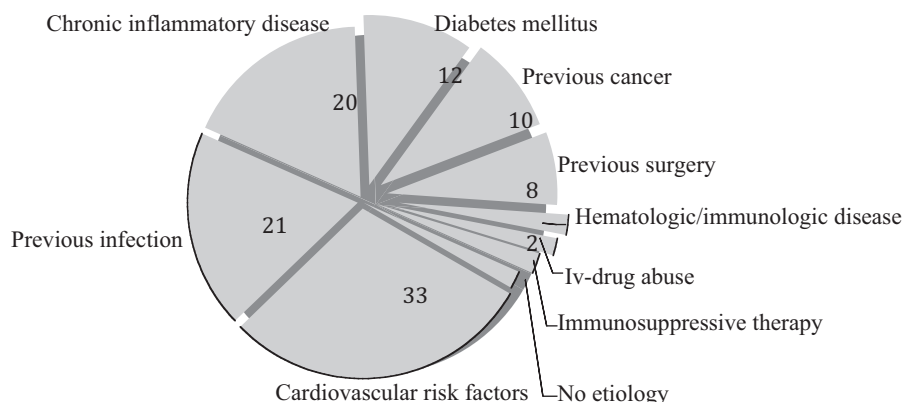
Affected spinal compartment	Number of patients (%)
Isolated spondylodiscitis	25 (48.1)
Isolated epidural empyema	9 (17.3)
Combined spondylodiscitis with epidural empyema	15 (28.8)
Subdural empyema	2 (3.8)
Osteomyelitis of the facet joints	1 (1.9)
Concomitant paravertebral abscesses	15 (28.8)

In 11 cases, we performed single dorsal decompression and drainage and debridement of an epi- or subdural infectious mass without any stabilizing procedure.

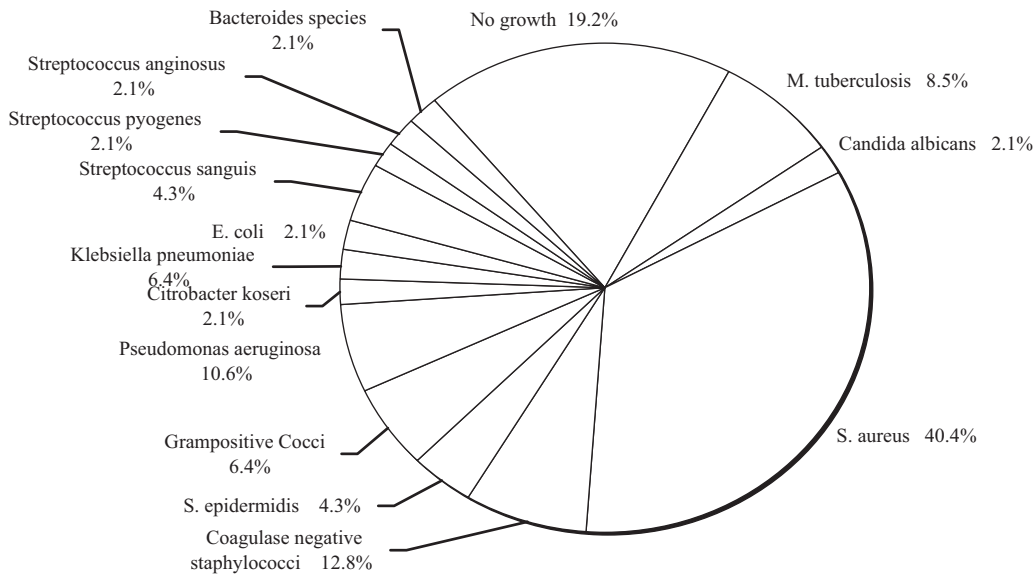
A total of 33 patients (63.5%) harboring 76 infected segments (15 cervical, 29 thoracic, and 32 lumbar) underwent a pedicle-screw-based dorsal stabilization (ConKlusion, Signus Medizintechnik GmbH, Alzenau, Bavaria, Germany) at the thoracic and lumbar levels, and a pedicle or lateral mass-screw-based stabilization (Neon, Ulrich GmbH, Ulm, Baden-Württemberg, Germany) at cervical levels in 38 procedures, either percutaneously (14 procedures: 7 thoracic or thoracolumbar junction and 7 lumbar) or via an open approach (24 procedures: 5 cervical, 7 thoracic, and 12 lumbar or lumbosacral junction) (▶Table 4).

During the same stabilizing operation, nine patients were posteriorly fused PLIF (posterior lumbar interbody fusion) in one segment using an iliac-crest bone autograft, and one patient in two segments using titanium cages (Zientek, Marquardt Medizintechnik, Spaichingen, Baden-Württemberg, Germany) filled with an iliac-crest bone graft.

The indication for fusion was the pyogenic osseous destruction of the disc space. Finally, in 14 cases (1 cervical, including ventral osteosynthesis, 8 thoracic, 1 thoracolumbar, and 4 lumbar) we completed dorsoventral reconstruction of



**Fig. 3** Comorbidities, presumed sources of systemic infection and concomitant infectious processes of 52 patients with spinal infections. Previous surgery: cancer of the hypopharynx, aortocoronary bypass, or a Zenker diverticle within 6 months before admission. Chronic inflammatory diseases: Crohn's, vasculitis, progressive polyarthritis. Cardiovascular risk factors: arterial hypertension, obesity and hypercholesterolemia, previous cardiac arrest, and chronic heart failure. Previous significant infection: pneumonia, urinary tract infection, or multiple abscesses. Immunologic diseases: acute myeloid leukemia and Burkitt-like lymphoma.



**Fig. 4** Results of intraoperative smears and previously attained microbiological cultures. Staphylococcus species prevail as causative organisms of spinal infections. Mixed microbiological cultures were found in five cases.

18 infected segments. In five cases, we performed sole cervical anterior interbody fusion (AIF) using iliac-crest autograft and ventral osteosynthesis after infected bone resection. In three of the percutaneously stabilized patients, debridement was performed percutaneously in the same session. Via a dorsolateral transmuscular approach, the intervertebral space and adjacent infected bone were excavated under fluoroscopic control and filled with bone graft harvested at the dorsal iliac crest. We performed the procedure in this manner because the devastating clinical situation of the patients contraindicated an anterior approach. All implants were controlled by routine postoperative CT scan and X-ray.

**Table 4** Surgical procedures

Stabilizing versus nonstabilizing	Number of procedures
1. Nonstabilizing/immobilizing	
Diagnostic biopsy	12
Decompression only (via [hemi]laminectomy)	11
2. Stabilizing/immobilizing	
(a) Via dorsal stabilizing approach	Total: 38
Open screw-rod system (stabilization)	24
Stabilization + decompression	15
Stabilization + PLIF	9
Percutaneous stabilization	14
(b) Via ventral approach	Total: 19
AIF	13
ACD or corporectomy + osteosynthesis	6

PLIF, posterior lumbar interbody fusion; AIF, anterior interbody fusion; ACD, anterior cervical decompression.

**Duration of Hospital Stay**

The mean hospital stay of patients with or without neurological deficit (30 days) did not differ significantly among those with dorsal stabilization only (30 days), those with stabilization and additional intervertebral fusion (PLIF: 37 and AIF: 34), and those with sepsis (23 days) ( $p = 0.04$ ). The duration of the hospital stay for septic patients was slightly shorter because of a policy aimed at quick referral to the treating hospital. This long duration was caused partly by the preoperative trial of conservative treatment and partly because of the postoperative time necessary for a visible effect after the first surgical procedure (dorsal stabilization). Two patients had to be operated on as emergencies (for acute paraplegia) and had a hospital stay at our department of between 1 and 3 days before being referred as previously arranged to their primary treating hospitals.

**Kind and Duration of Antibiotic Therapy**

Antibiotic therapy was given to every patient suffering from spinal infection. The mean postoperative duration of antibiotic treatment was 11.5 ( ± 1.6 SD) weeks. If no causative agent was found, a calculated antibiotic therapy with clindamycin (600 mg three times daily intravenously) was given. In cases of positive microbiological cultures, antibiotic therapy was specific: antibacterial in 47 cases (combined with a second and/or third antibiotic in 20 cases), tuberculostatic (triple therapy: rifampicin [RifampicinHefa], isoniazide [Rimifon], pyrazinamide [Pyrazinamid Labatec]) in 4 cases, and antifungal in 1 case. Intravenous antibiotics were changed to oral medication as soon as C-reactive protein (CRP) and clinical complaints decreased. Antibiotic treatment was only finished after erythrocyte sedimentation rate (ESR) and CRP had declined to normal values, and proved stable for 7 days. After cessation of antibiotic treatment, inflammatory laboratory parameters were taken for a further 4 weeks to exclude a relapse of infection.

This document was downloaded for personal use only. Unauthorized distribution is strictly prohibited.

**Table 5** Outcome after surgery for spinal pyogenic infections

1. Follow-up	Mean: 24 months (SD: 16, median: 20 months, range: 1–60 months)
2. Symptom relief	
Motor range:	61.7% (i.e., 18 survivors) improved
	6.4% (i.e., 3 survivors) deteriorated after surgery
Bladder/sphincter dysfunction:	Complete remission in 50%
Back/radicular pain:	Relief of back/radicular pain in 91.1%/84.1% of the survivors
3. Recurrence	3.8%: 1 patient: recurrence of a lumbar intraspinal empyema
	1 patient: chronic relapsing multilevel spondylodiscitis due to lacking compliance regarding antibiotic therapy
4. Complications	Surgery related: 11.5% (i.e., 6 patients)
	2 patients: screw misplacement, postop deficit and reoperation
	1 patient: myelopathy by the autograft and reoperation
	1 patient: screw dislocation during follow-up and reoperation
	1 patient: persistent dysphagia following ACD
	1 patient: single level spondylodiscitis after evacuation of a lumbar epidural empyema
5. Mortality	19.2% (i.e., 10 patients)
	2 patients in the immediate postoperative period (1 septic complications, 1 blast crisis of acute myelocytic leucemia)
	8 patients during follow-up period (myocardial infarction, multiple metastasized cancer, pulmonary embolism)

ACD, anterior cervical decompression.

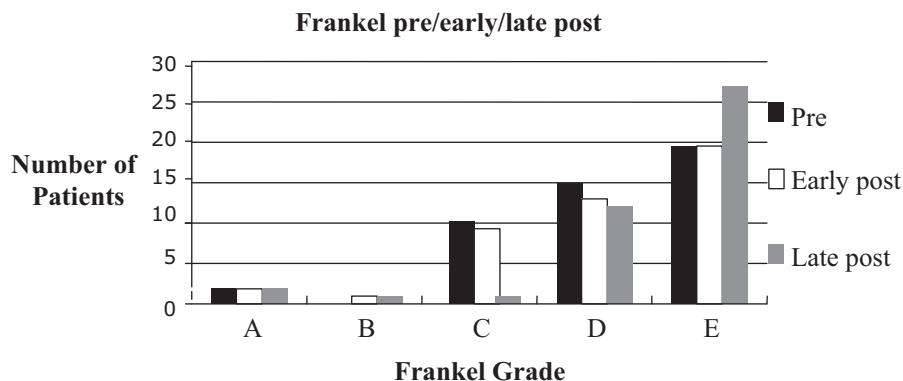
### Outcome (Surgical and Neurological Complications, Infection, and Pain)

The mean follow-up time was 24 months ( $\pm 16$  SD, median: 20 months, range: 1 to 60). ESR, CRP, clinical presentation, and plain radiographs formed the basic appraisal criteria for recovery. Overall mortality within follow-up was 19.2%. In the immediate postoperative period (i.e., 10 days), two patients died (one due to septic complications and one due to blast crisis based on acute myelocytic leukemia), and eight patients died during follow-up for reasons other than pyogenic infection (myocardial infarction, multiple metastasized

cancer, and pulmonary embolism). Surgery-related complications occurred in six patients (11.5%), as shown in ►Table 5.

Recurrence of infection occurred in two (3.8%) patients (►Table 5). Thus, in terms of eradication of the infected focus, recovery from the pyogenic spinal infection was achieved in 97.6% of the patients still alive.

At last follow-up, patients were graded using the Frankel's scale, as follows: (A) 3 (6.4%); (B) 1 (2.1%); (C) 1 (2.1%); (D) 13 (27.7%); (E) 29 (61.7%) (►Fig. 5). None of the Frankel A-patients improved, whereas 11 (40.7%) of the Frankel D-patients did. Thus, 61.7% (i.e.,  $n = 18$  of the surviving



**Fig. 5** Preoperative, early (during hospital stay) and late (at 24 months follow-up investigation) postoperative neurological status according to the Frankel grading scale. Three patients deteriorated during the postoperative follow-up, 18 patients improved (3 early postoperatively and 15 at last follow-up investigation).



patients) improved in motor function, whereas 6.4% ( $n = 3$ ) deteriorated after surgery. Bladder (acute urinary retention) and sphincter dysfunction remitted completely in 50.0% of the affected patients. In 50.0% there was no improvement of this dysfunction (mostly sphincter dysfunction). Radicular pain and back pain persisted in 15.9 and 8.9%, respectively (► **Table 5**). In patients with spondylodiscitis, sagittal alignment (Cobb angle) was maintained in 42 patients (80.8%), whereas 10 (19.2%) showed increased kyphosis without clinical symptoms at the operated level.

## Discussion

Spinal pyogenic infections mostly take a severe clinical course. Neurological deficits are reported in up to 30% of cases,<sup>12</sup> and patients in a septic state with potential for multiorgan failure and death if untreated are admitted to hospitals in as many as 31% of cases.<sup>2,17</sup> Mortality rates are reported as high as 20%, and regarding neurological outcome, permanent disability rates ranged between 15 and 46%.<sup>12,17–19</sup>

Surgery seems to be definitely indicated in cases of neurological deficit, loss of spinal stability, or infection intractable to conservative treatment.<sup>3,9,20</sup> Moreover, surgery is effective for radical debridement of the infected focus<sup>11,21,22</sup> and safe for neurological outcome<sup>17,23</sup> and leads to better quality-of-life scores.<sup>6</sup>

In our study, surgery was indicated according to the proposed algorithm (► **Fig. 2**). Details of indications to surgery at the cervical, thoracic, and lumbar spine have been provided above. The signs, symptoms, and neurological findings in our study, as well as comorbidities and duration of hospital stay and of symptoms without diagnosis of a spinal infection, are comparable to those found in the literature.<sup>7,11,12,19,24</sup> Surgical therapy for an isolated intraspinal empyema has been described elsewhere and requires no further discussion.<sup>25,26</sup> Standards of calculated antibiotic therapy in the absence of causative germ growth differ among institutions,<sup>2</sup> and studies are too heterogeneous to allow comparisons because no randomized trials exist. We followed the antibiotic regimen recommended by the local Department of Microbiology. Based on this regimen, we achieved a low rate of recurrence. Gouliouris et al suggest antimicrobial regimens according to causative organism and susceptibilities. Though, they conclude that due to a lack of an adequate follow-up and randomized trials, as well as low studies' population volume, the optimal duration of antibiotics, and route of administration, and the role of a combination therapy is not clear.<sup>2</sup>

The patients' ages at diagnosis (median: 68 years) is somewhat higher in the present than in previous studies, and may be a result of demographic development within Germany. Based on our algorithm, we can show a low perioperative mortality rate (3.8%). The deaths of eight patients during the follow-up for reasons other than pyogenic infection underline the complex problems of underlying diseases and comorbidities with spinal pyogenic infections. Surgery was beset with complications (11.5%), and unfortu-

nately this led to neurological deterioration in three patients. In contrast, 61.7% of the surviving patients improved in motor function; bladder and sphincter dysfunction remitted completely in 50.0% of affected patients, and radicular pain and back pain were persistent in only 15.9 and 8.9%, respectively, compared with 63.5 and 51.9% initially. These results are consistent with those of previous studies that focus on surgical eradication of the infected focus, immobilization, and restoration of spinal stability.<sup>17,27,28</sup> All authors reached a good outcome with their surgical policy, even though mortality and morbidity seem high.<sup>20,29</sup> Mann et al had seven septic patients in their series, and none of these died postoperatively.<sup>17</sup> However, two patients with initial para- or tetraplegia died as a result of their disease.

The mostly hidden progress of infection which is made possible by immunocompromising conditions (e.g., diabetes mellitus, long-term steroid use, previous cancer, or chronic infectious diseases) results in a high incidence of severely deteriorated neurological deficits.<sup>30</sup> Graft infection after spinal fusion is rare but shows a direct correlation to comorbidity and the patient's age.<sup>31</sup> To prevent such complications, aggressive anterior debridement extending toward vital bone to provide the graft with good blood supply should be emphasized.<sup>9,28</sup>

In the present study, most patients in a septic state were subject to aggressive surgical treatment, partly because of their devastating neurological condition and partly because of their rapid general deterioration under conservative treatment.

Even though the clinical impression suggests that spinal infections occur frequently among patients admitted with sepsis (in our own series, 32.7%), scarce data are available in the literature on this topic. Moreover, optimal treatment of these patients remains controversial: some authors refrain from surgery in these high-risk patients; others regard acute sepsis as an indication for surgery, while others treat patients with antibiotics for several weeks before surgery.<sup>22,32,33</sup> Unfortunately, those studies that recommend antibiotic therapy do not provide details about catecholamine therapy and optimal time of surgery. Only a few studies describe the incidence of sepsis on admission; percentages between 31.3 and 23.8% were reported.<sup>6,17,32,33</sup> In one of these studies, organ failure was seen in 17 of 32 patients during their postoperative course, resulting in two deaths from multiorgan failure in a septic state.<sup>22</sup> Another series reports reduced general condition and sepsis before admission in 34.6% of patients.<sup>10</sup> In the present study, none of the 17 patients in a septic condition on admission died during their hospital stay; 4 of them died during follow-up as a result of pre-existing diseases. The surviving patients had good outcomes. The median Karnofsky score at last follow-up investigation was 80 (range: 40 to 100), and the median age of this group was slightly younger (63 years; range: 27 to 81) compared with the study population (median age: 68 years).

As a way out of the discussion concerning the optimal treatment for these severely ill patients, we developed intermediate strategies to offer tailored surgical opportunities. It seems feasible and less encumbering to treat patients who are

neurologically intact (especially those with multisegmental and multilevel infections) in a first stage using dorsal thoracic and lumbar stabilization, via percutaneous approaches as first described in 1994 and meanwhile used in spinal infections surgery.<sup>34,36</sup> Here, the authors saw no correction loss, and in 15 of 23 patients, percutaneous fixation was a definitive treatment. In two cases, anterior debridement and fusion had to be performed because of progressive bony destruction. In clinical situations in which an anterior approach is contraindicated, Fayazi et al mention a posterior transforaminal or posterior lumbar interbody debridement with concomitant fusion in predominant lumbar discitis and minimal vertebral involvement<sup>32</sup>; however, in our series, the infected focus persisted when the general medical condition of debilitated patients improved after initial stabilization. After clinical improvement, we performed anterior debridement and interbody fusion using iliac-crest bone autograft at the upper lumbar and thoracic spine, as reported in another study of our group.<sup>35</sup> Akbar and coworkers proposed a classification system focusing on the optimal surgical therapy.<sup>9</sup> Based on radiological aspects, they suggest combined ventrodorsal or dorsoventral procedures using expandable titanium cages in severe pyogenic cases with progressive deformity. Focusing on secondary loss of correction and the rate of pseudarthrosis, the use of bone autograft seemed inferior.

## Conclusion

The treatment of pyogenic spinal infections of the mostly comorbid patient remains a challenge, especially in cases of sepsis and rapid general and neurological deterioration. Those patients should be considered candidates for tailored surgical treatment. As previous studies, this series shows that surgery of these debilitated patients is efficacious, and that even septic patients in devastating general condition can attain a good outcome and do not have to be withdrawn from surgery. Future prospective randomized trials are necessary.

### Conflict of Interest

None

## References

- Digby JM, Kersley JB. Pyogenic non-tuberculous spinal infection: an analysis of thirty cases. *J Bone Joint Surg Br* 1979;61(1):47–55
- Gouliouris T, Aliyu SH, Brown NM. Spondylodiscitis: update on diagnosis and management. *J Antimicrob Chemother* 2010;65 (Suppl 3):iii11–iii24
- Hadjipavlou AG, Mader JT, Necessary JT, Muffoletto AJ. Hematogenous pyogenic spinal infections and their surgical management. *Spine* 2000;25(13):1668–1679
- Jensen AG, Espersen F, Skinhøj P, Frimodt-Møller N. Bacteremic *Staphylococcus aureus* spondylitis. *Arch Intern Med* 1998;158 (5):509–517
- German Federal Bureau of Statistics. Public Health Service. 2005; Series 12: 1–79

- Weinstein MA, McCabe JP, Cammisa FP Jr. Postoperative spinal wound infection: a review of 2,391 consecutive index procedures. *J Spinal Disord* 2000;13(5):422–426
- Quiñones-Hinojosa A, Jun P, Jacobs R, Rosenberg WS, Weinstein PR. General principles in the medical and surgical management of spinal infections: a multidisciplinary approach. *Neurosurg Focus* 2004;17(6):E1
- Calderone RR, Larsen JM. Overview and classification of spinal infections. *Orthop Clin North Am* 1996;27(1):1–8
- Akbar M, Lehner B, Doustdar S, et al. [Pyogenic spondylodiscitis of the thoracic and lumbar spine: a new classification and guide for surgical decision-making]. *Orthopade* 2011;40(7):614–623
- Rath SA, Neff U, Schneider O, Richter HP. Neurosurgical management of thoracic and lumbar vertebral osteomyelitis and discitis in adults: a review of 43 consecutive surgically treated patients. *Neurosurgery* 1996;38(5):926–933
- Suess O, Weise L, Brock M, Kombos T. Debridement and spinal instrumentation as a single-stage procedure in bacterial spondylitis/spondylodiscitis. *Zentralbl Neurochir* 2007;68(3):123–132
- Woertgen C, Rothoerl RD, Englert C, Neumann C. Pyogenic spinal infections and outcome according to the 36-item short form health survey. *J Neurosurg Spine* 2006;4(6):441–446
- Przybylski GJ, Sharan AD. Single-stage autogenous bone grafting and internal fixation in the surgical management of pyogenic discitis and vertebral osteomyelitis. *J Neurosurg* 2001; 94(1, Suppl):1–7
- Wang Z, Lenehan B, Itshayek E, et al. Primary pyogenic infection of the spine in intravenous drug users: a prospective observational study. *Spine* 2012;37(8):685–692
- Roques F, Nashef SA, Michel P, et al. Risk factors and outcome in European cardiac surgery: analysis of the EuroSCORE multinational database of 19030 patients. *Eur J Cardiothorac Surg* 1999;15 (6):816–822, discussion 822–823
- Frankel HL, Hancock DO, Hyslop G, et al. The value of postural reduction in the initial management of closed injuries of the spine with paraplegia and tetraplegia. I. Paraplegia 1969;7(3):179–192
- Mann S, Schütze M, Sola S, Piek J. Nonspecific pyogenic spondylodiscitis: clinical manifestations, surgical treatment, and outcome in 24 patients. *Neurosurg Focus* 2004;17(6):E3
- Chan CT, Gold WL. Intramedullary abscess of the spinal cord in the antibiotic era: clinical features, microbial etiologies, trends in pathogenesis, and outcomes. *Clin Infect Dis* 1998;27(3):619–626
- Reihsaus E, Waldbaur H, Seeling W. Spinal epidural abscess: a meta-analysis of 915 patients. *Neurosurg Rev* 2000;23(4):175–204, discussion 205
- Ogden AT, Kaiser MG. Single-stage debridement and instrumentation for pyogenic spinal infections. *Neurosurg Focus* 2004; 17(6):E5
- Lee MC, Wang MY, Fessler RG, Liauw J, Kim DH. Instrumentation in patients with spinal infection. *Neurosurg Focus* 2004;17(6):E7
- Schinkel C, Gottwald M, Andress HJ. Surgical treatment of spondylodiscitis. *Surg Infect (Larchmt)* 2003;4(4):387–391
- Lerner T, Hackenberg L, Rösler S, Joosten U, Halm H, Liljenqvist U. [Surgical therapy of unspecific and specific Spondylodiscitis]. *Z Orthop Ihre Grenzgeb* 2005;143(2):204–212
- O'Daly BJ, Morris SF, O'Rourke SK. Long-term functional outcome in pyogenic spinal infection. *Spine* 2008;33(8):E246–E253
- Löhr M, Reithmeier T, Ernestus RI, Ebel H, Klug N. Spinal epidural abscess: prognostic factors and comparison of different surgical treatment strategies. *Acta Neurochir (Wien)* 2005;147(2):159–166, discussion 166
- Martin RJ, Yuan HA. Neurosurgical care of spinal epidural, subdural, and intramedullary abscesses and arachnoiditis. *Orthop Clin North Am* 1996;27(1):125–136
- Carragee EJ. Instrumentation of the infected and unstable spine: a review of 17 cases from the thoracic and lumbar spine with pyogenic infections. *J Spinal Disord* 1997;10(4):317–324



- 28 Isenberg J, Jubel A, Hahn U, et al. [Multistep spondylosyndesis-surgical management of progressive spondylodiscitis in patients with critical physical status]. *Orthopade* 2005;34:159–166
- 29 Barnes B, Alexander JT, Branch CL Jr. Cervical osteomyelitis: a brief review. *Neurosurg Focus* 2004;17(6):E11
- 30 Eismont FJ, Bohlman HH, Soni PL, Goldberg VM, Freehafer AA. Pyogenic and fungal vertebral osteomyelitis with paralysis. *J Bone Joint Surg Am* 1983;65(1):19–29
- 31 Niedhart C, Miltner O, Zilkens KW, Niethard FU. [Bacterial osteitis. Special considerations in immunocompromised patients]. *Orthopade* 2004;33(3):297–304
- 32 Fayazi AH, Ludwig SC, Dabbah M, Bryan Butler R, Gelb DE. Preliminary results of staged anterior debridement and reconstruction using titanium mesh cages in the treatment of thoracolumbar vertebral osteomyelitis. *Spine J* 2004;4(4):388–395
- 33 Hempelmann RG, Mater E, Schön R. Septic hematogenous lumbar spondylodiscitis in elderly patients with multiple risk factors: efficacy of posterior stabilization and interbody fusion with iliac crest bone graft. *Eur Spine J* 2010;19(10):1720–1727
- 34 Deininger MH, Unfried MI, Vougioukas VI, Hubbe U. Minimally invasive dorsal percutaneous spondylodesis for the treatment of adult pyogenic spondylodiscitis. *Acta Neurochir (Wien)* 2009;151(11):1451–1457
- 35 Ringel F, Stoffel M, Stürer C, et al. Endoscopy-assisted approaches for anterior column reconstruction after pedicle screw fixation of acute traumatic thoracic and lumbar fractures. *Neurosurgery* 2008;62(5 Suppl 2):ONS445–ONS452
- 36 Jeanneret B, Magerl F. Treatment of osteomyelitis of the spine using percutaneous suction/irrigation and percutaneous external spinal fixation. *J Spinal Disord* 1994;7(3):185–205