Endoscopic ultrasound-guided gastroenterostomy versus duodenal stenting for malignant gastric outlet obstruction: an international, multicenter, propensity score-matched comparison

Authors

Roy L. J. van Wanrooij[1], Giuseppe Vanella[2], Michiel Bronswijk[3,4], Peter de Gooyer[5], Wim Laleman[3], Hannah van Malenstein[3], Francesco Vito Mandarino[2], Giuseppe Dell'Anna[2], Paul Fockens[1,5], Paolo G. Arcidiacono[2], Schalk W. van der Merwe[3], Rogier P. Voermans[5]

Institutions

1 Department of Gastroenterology and Hepatology, Amsterdam UMC, Vrije Universiteit, Amsterdam Gastroenterology Endocrinology and Metabolism, Amsterdam, The Netherlands
2 Pancreatobiliary Endoscopy and Endosonography Division, Pancreas Translational and Clinical Research Centre, IRCCS San Raffaele Scientific Institute and University, Milan, Italy
3 Department of Gastroenterology and Hepatology, University Hospitals Gasthuisberg, University of Leuven, Leuven, Belgium
4 Department of Gastroenterology and Hepatology, Imelda General Hospital, Bonheiden, Belgium
5 Department of Gastroenterology and Hepatology, Amsterdam UMC, University of Amsterdam, Amsterdam Gastroenterology Endocrinology and Metabolism, Amsterdam, The Netherlands

submitted 17.10.2021
accepted after revision 1.2.2022
published online 24.3.2022

Bibliography
Endoscopy 2022; 54: 1023–1031
DOI 10.1055/a-1782-7568
ISSN 0013-726X

Georg Thieme Verlag KG, Rüdigerstraße 14, 70469 Stuttgart, Germany

Table 1 s, Fig. 1 s
Supplementary material is available under https://doi.org/10.1055/a-1782-7568

Scan this QR-Code for the author commentary.

Corresponding author
Roy L. J. van Wanrooij, MD, PhD, Department of Gastroenterology and Hepatology, Amsterdam UMC, Vrije Universiteit, Amsterdam Gastroenterology Endocrinology and Metabolism, de Boelelaan 1118, 1081 HV Amsterdam, The Netherlands
rl.vanwanrooij@amsterdamumc.nl

ABSTRACT

Background Endoscopic duodenal stenting is the current standard treatment for malignant gastric outlet obstruction (GOO) in patients with limited life expectancy. However, duodenal stenting is prone to stent dysfunction. Endoscopic ultrasound-guided gastroenterostomy (EUS-GE) is a novel technique with potentially superior stent patency. We compared clinical success, safety, and stent dysfunction of EUS-GE and duodenal stenting in patients with malignant GOO using propensity score matching.

Methods This international, multicenter, retrospective study analyzed consecutive patients undergoing EUS-GE or duodenal stenting for GOO between 2015 and 2021 in three European centers. Primary outcomes were clinical success (GOO scoring system [GOOSS] ≥2) and stent dysfunction (GOOSS ≤1 after initial clinical success). A propensity score matching (1:1) analysis was performed using age, sex, underlying disease, disease stage, ascites, and peritoneal carcinomatosis as variables.

Results 214 patients underwent EUS-GE (n = 107) or duodenal stenting (n = 107). After propensity score matching, 176 patients were matched and compared. Technical success rates for EUS-GE and duodenal stenting were 94% (95%CI 89%–99%) vs. 98% (95%CI 95%–100%), respectively ($P = 0.44$). Clinical success rates were 91% (95%CI 85%–97%) vs. 75% (95%CI 66%–84%; $P = 0.008$). Stent dysfunction occurred in 1% (95%CI 0–4%) vs. 26% (95%CI 15%–37%) of patients ($P < 0.001$). Adverse event rate was 10% (95%CI 4%–17%) vs. 21% (95%CI 12%–29%; $P = 0.09$).

Conclusion EUS-GE had higher clinical success and lower stent dysfunction, with similar safety, compared with duodenal stenting, suggesting that EUS-GE may be preferred over duodenal stenting in patients with malignant GOO.

Introduction

Gastric outlet obstruction (GOO) is a common complication of malignant tumors arising from the pancreas and gastric antrum. Less commonly, GOO may also arise due to malignant infiltration or external compression from tumors arising from bile ducts, gallbladder, duodenum, ampulla, retroperitoneum, or metastases. This may lead to recurrent vomiting, dehydration, malnourishment, and inability to tolerate chemotherapy, which severely impair quality of life [1]. Only a minority of patients with malignant GOO present with a resectable tumor; most often GOO is indicative of locally advanced disease and requires palliative treatment [2]. Traditionally, treatment options for GOO consisted of surgical (open/laparoscopic) gastroenterostomy or endoscopic duodenal stenting. Three underpowered randomized controlled trials comparing surgical management with endoscopic duodenal stenting yielded inconsistent results [3–5]. This has led various societies including the American Gastroenterology Association and American Society for Gastrointestinal Endoscopy (ASGE) to advise laparoscopic gastroenterostomy in clinically fit patients with an expected survival of more than 2–6 months because of long-term patency of the surgical anastomosis, whereas duodenal stenting is reserved for patients with an expected survival of less than 2–6 months [6, 7]. Duodenal stenting leads to rapid relief of symptoms and shows low morbidity compared with surgical gastroenterostomy but has been associated with a high rate of stent dysfunction due to tumor ingrowth, which requires reintervention [8]. However, in daily clinical practice, survival can be notoriously difficult to predict and surgeons are often reluctant to subject patients with malignant GOO to surgical interventions. This, together with patient preference, likely contributes to duodenal stenting still being used in the majority of patients with malignant GOO.

Endoscopic ultrasound-guided gastroenterostomy (EUS-GE) is a relatively new, minimally invasive technique that provides rapid relief of symptoms associated with low morbidity and long-term patency of the anastomosis. Recently, multiple retrospective series comparing EUS-GE with surgical gastroenterostomy have indeed shown similarly high technical and clinical success rates, with significantly faster relief of symptoms, shorter hospital stay, and lower morbidity with EUS-GE [9–12]. Data comparing EUS-GE and duodenal stenting are limited, with most studies not controlling for confounders, making interpretation of outcomes data difficult [13, 14]. More data on this matter are needed to define the most optimal treatment strategy in these frail patients. The aim of the current study was to compare efficacy, safety, and stent dysfunction rate of EUS-GE vs. duodenal stenting in patients with malignant GOO with propensity score matching to correct for confounders.

Methods

Patients and study design

A multicenter retrospective analysis was performed of all consecutive procedures involving either EUS-GE or duodenal stenting for GOO between January 2015 and May 2021 at the Amsterdam University Medical Center (Amsterdam UMC) in the Netherlands, IRCSS San Raffaele Scientific Institute in Italy, and University Hospitals Leuven in Belgium. Patients were identified by searching local endoscopic electronic databases. The EUS-GE group included patients from our previous multicenter analysis in which EUS-GE was compared with laparoscopic gastroenterostomy [9]. The study protocol was approved by the Institutional Review Board of Amsterdam UMC as well as in each participating center.

Inclusion criteria were: 1) symptomatic malignant GOO; 2) endoscopic and/or radiological confirmation of an obstruction at the gastric antrum or duodenum; and 3) primary intended intervention of either EUS-GE or duodenal stenting. Exclusion criteria were: 1) previous duodenal stenting, EUS-GE, or surgical gastroenterostomy; and 2) follow-up data for less than 30 days post-procedure.

Data collection

Data collection was conducted by manually extracting data from the electronic patient charts. Data storage, statistical analysis, and the matching procedure were performed using IBM SPSS statistics for windows version 26.0 (IBM, Armonk, NY, USA).

Study definitions and end points

The two primary end points were clinical success and stent dysfunction. Both primary end points were based on the gastric outlet obstruction scoring system (GOOSS). The GOOSS is an ordinal scoring system ranging from 0 to 3, which is based on the highest intake tolerability without vomiting (0 = no intake; 1 = liquid only; 2 = soft solids; 3 = full diet) [15].

Clinical success was defined as a GOOSS score of at least 2 after the initial intervention (EUS-GE or duodenal stenting). Stent dysfunction was defined as recurrence of obstructive symptoms (GOOSS ≤ 1) after initial clinical success.

Secondary end points included technical success, length of hospitalization after initial EUS-GE or duodenal stenting, adverse events (AEs), and overall survival. Technical success was defined as successful placement of a duodenal stent crossing the obstruction site or successful creation of a gastroenteric anastomosis by means of a lumen-apposing metal stent (LAMS). Intervention-related AEs such as perforation, stent migration, clinically relevant bleeding requiring intervention and/or blood transfusion, cholangitis, sepsis, pneumonia, post-procedural fever, and post-procedural pain that occurred within 30 days following the procedure were scored through the ASGE lexicon as mild, moderate, severe, or fatal [16].

Study procedures

EUS-GE

All procedures were performed under deep propofol sedation or general anesthesia. Prophylactic broad-spectrum antibiotic therapy was routinely administered. EUS-GE procedures were performed using the wireless EUS-gastroenterostomy simplified technique (WEST), as described previously [17]. In short, a 7-Fr nasobiliary drain or enteral feeding tube was advanced be-

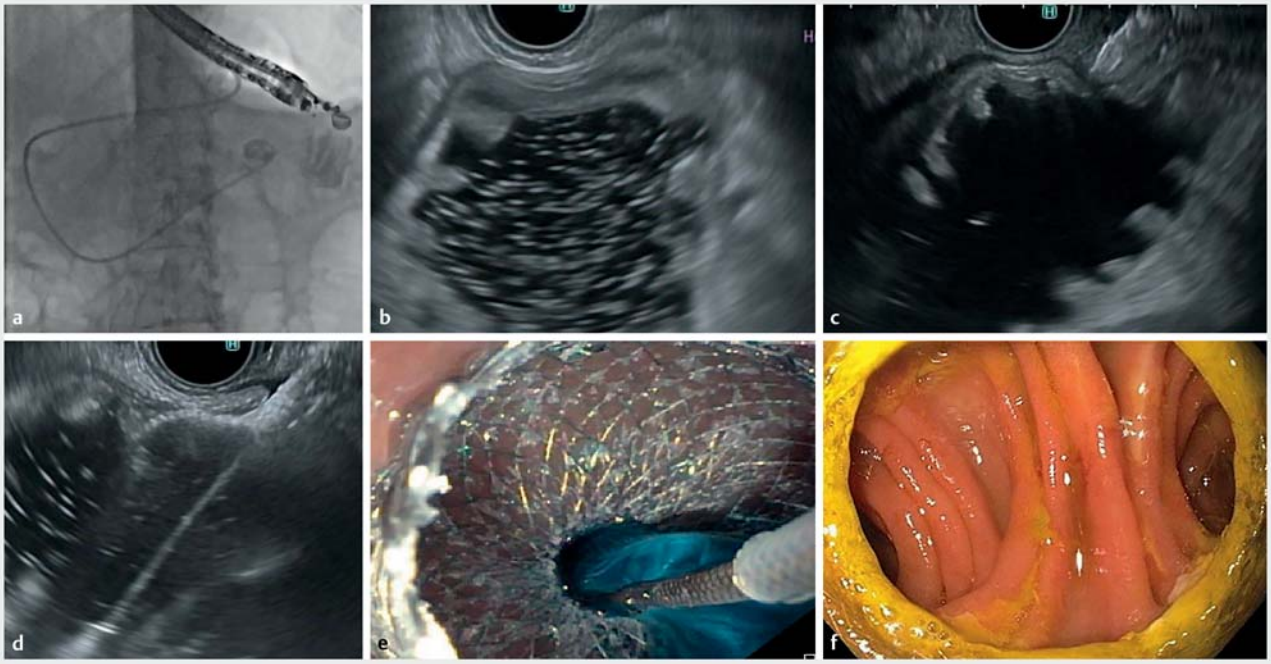

▶ **Fig. 1** Stepwise approach to endoscopic ultrasound (EUS)-guided gastroenterostomy. **a** Fluoroscopic image: placement of a 7-Fr nasobiliary catheter or enteral feeding tube through the gastric or duodenal stenosis at Treitz ligament. The EUS scope was positioned close to the catheter. **b** EUS image: the flow of fluid could be seen immediately after saline infusion, which confirmed visualization of a proximal jejunal bowel loop. **c** EUS image: dilated jejunal bowel loop after infusion of saline. The electrocautery-enhanced lumen-apposing metal stent (LAMS) was positioned in line with the small bowel loop. Using pure-cutting current the stent was brought into the jejunal lumen. **d** EUS image: the distal flange was released under EUS guidance. The device was then retracted onto the gastric wall. The proximal flange was deployed inside the working channel of the endoscope, and slowly pushed out of the endoscope while at the same time gently pulling back the endoscope from the gastric wall. **e** Endoscopic image: saline infused through the nasobiliary catheter was, in this case, dyed with methylene blue and appeared in the gastric lumen after successful LAMS placement. **f** Endoscopic view from the stomach showing a patent gastroenteric anastomosis 3 months after LAMS placement.

yond the stenosis into the proximal jejunum (▶ **Fig. 1a**). The nasobiliary drain inside the jejunal loop was identified by EUS. Infusion of saline solution (with or without blue dye) through the drain or feeding tube resulted in dilation of the jejunal bowel loop (▶ **Fig. 1b**). The electrocautery-enhanced LAMS (Hot Axios; Boston Scientific Corp., Marlborough, Massachusetts, USA) was advanced through the gastric wall into the enteric loop using pure cutting current (100–150 W) (▶ **Fig. 1c**). After successful entry into the jejunum, the distal flange was deployed under EUS guidance and carefully retracted against the intestinal wall, creating direct contact between the gastric and enteral walls (▶ **Fig. 1d**). The proximal flange was subsequently deployed inside the endoscope working channel and was then gently pushed out of the endoscope while simultaneously rotating away the endoscope from the gastric wall. Successful creation of the gastroenteric anastomosis was confirmed either by (blue dyed) water entering the gastric lumen, or by direct endoscopic visualization of small intestinal mucosa and/or fluoroscopy (▶ **Fig. 1e,f**). Either a 15-mm or 20-mm LAMS was used at the discretion of the endoscopist and according to availability.

Endoscopic duodenal stenting

Endoscopic duodenal stenting was performed under propofol sedation or general anesthesia. A therapeutic gastroscope or pediatric colonoscope was advanced to the site of gastric or duodenal obstruction (▶ **Fig. 2a**). A double-lumen catheter and guidewire were then advanced through the stricture (▶ **Fig. 2b**). Contrast injection under fluoroscopy was used to determine the length of the stricture, relation to the papilla, and preferable size of the stent (▶ **Fig. 2c**). An uncovered self-expandable metal stent (SEMS) was then advanced over the wire and deployed under endoscopic and fluoroscopic guidance (▶ **Fig. 2d**). Wallflex duodenal stents (Boston Scientific) and Cook Evolution duodenal stents (Cook Medical, Bloomington, Indiana, USA) 6, 9, and 12 cm in length were used. The diameter of the stent was 22 mm in all cases. Adequate positioning of the stent was confirmed by means of fluoroscopy and endoscopy (▶ **Fig. 2e,f**).

Statistical analysis.

Categorical and binary variables were reported as frequencies (%) and were compared through either Fisher's exact test or Pearson's chi-squared test. Continuous variables were reported as means or median with SD or interquartile range (IQR) and

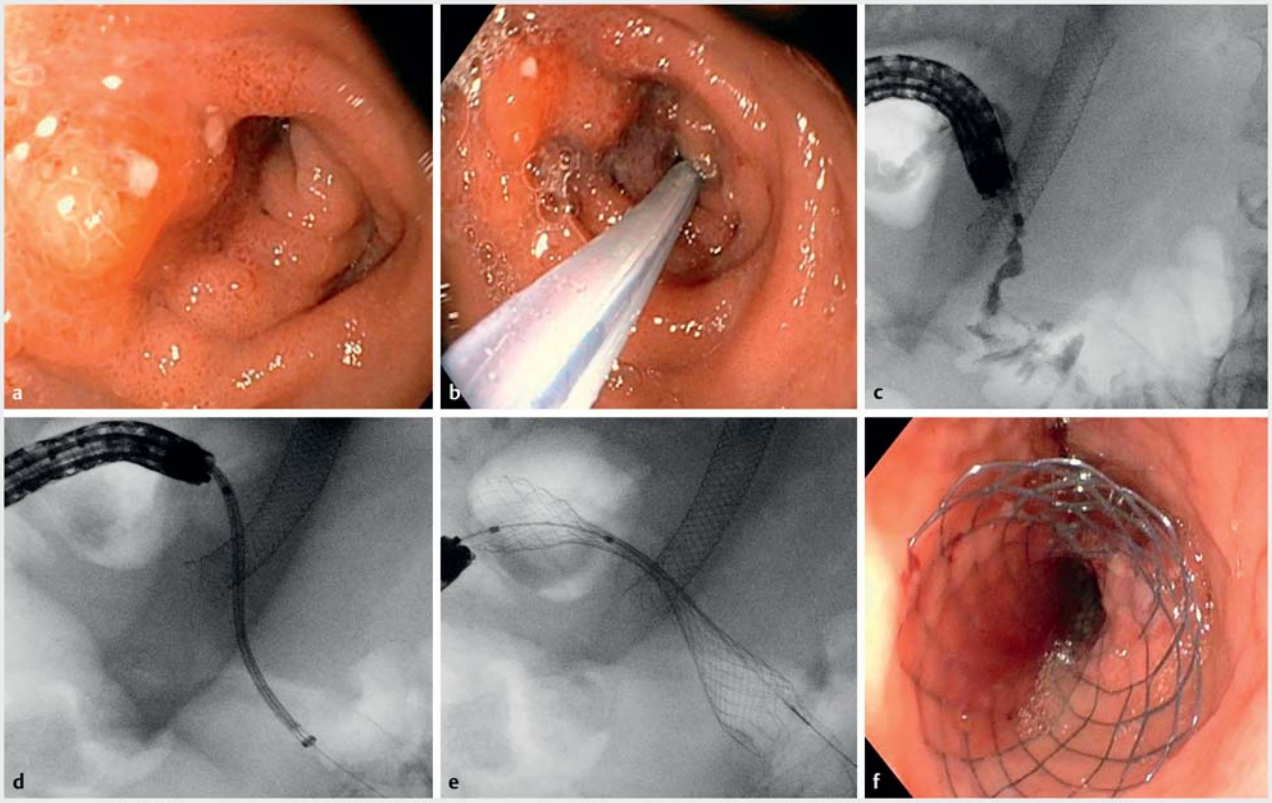

▶ **Fig. 2** Stepwise approach to endoscopic duodenal stenting. **a** Endoscopic image: malignant duodenal stenosis. **b** Endoscopic image: traversing the stricture with a double-lumen catheter and a guidewire. **c** Fluoroscopic image: contrast injection through the catheter to determine the length of the stricture, relation to the papilla, and preferable size of the stent. **d** Fluoroscopic image: advancing the self-expandable metal stent over the guidewire across the stricture. **e** Fluoroscopic image: the stent was been deployed with the waist located in the middle of the stent confirming adequate position. **f** Endoscopic image: proximal side of the uncovered stent deployed proximally to the stricture.

were analyzed through unpaired *t* tests or Mann–Whitney *U* test. The reported analyses were performed in the intention-to-treat population (intended procedure EUS-GE or duodenal stenting regardless of technical success), unless explicitly mentioned as per protocol (only patients with technical success). Outcomes were reported as odds ratios (OR) with a 95 %CI. *P* values were considered statistically significant if < 0.05.

To minimize selection bias of the observed data, a propensity score matching analysis was conducted. Propensity score was based on age, sex, GOO etiology, and disease stage, presence of ascites, and peritoneal carcinomatosis. Variables were selected based on demographic discrepancies of the main cohort and expected factors of influence based on recent studies [13, 18–20]. A stringent maximum propensity score difference of 0.05 was used for matching. For the time to event data analysis, the Kaplan–Meier curve and log-rank test were used.

Results

Main cohort

A total of 246 eligible patients were identified. After excluding 32 patients in whom follow-up was less than 30 days, the EUS-GE group consisted of 107 patients (50 %) and the duodenal stenting group included 107 patients (50 %) (see **Fig. 1 s** and **Table 1 s** in the online-only Supplementary Material).

Baseline characteristics are shown in ▶ **Table 1**. Pancreatic cancer-induced GOO was more frequent in the duodenal stenting group than in the EUS-GE group (65.4 % vs. 46.7 %; *P* = 0.009). With regard to disease manifestations, peritoneal carcinomatosis was present more frequently in the EUS-GE group (41.1 % vs. 25.2 %; *P* = 0.020), while the presence of ascites did not significantly differ between the two groups (29.0 % vs. 22.4 %).

Technical success of EUS-GE and duodenal stenting was 94 % (95 %CI 90 %–99 %) vs. 98 % (95 %CI 96 %–100 %), respectively. Clinical success was 90 % (95 %CI 84 %–96 %) with EUS-GE and 77 % (95 %CI 68 %–85 %) with duodenal stenting. Stent dysfunction occurred less frequently after EUS-GE (3 %; 95 %CI 0–6 %) than after duodenal stenting (30 %; 95 %CI 14 %–46 %).

Propensity score matching analysis

Propensity score matching allocated 88 patients in each group (1:1), resulting in a total of 176 patients. No significant differences in baseline characteristics were found between the two groups (▶ **Table 1**). The overall characteristics of the propensity score-matched cohort included a mean age of 66 years (SD

▶ **Table 1** Main and matched cohort: baseline characteristics.

	Main cohort			Matched cohort		
	EUS-GE (n = 107)	Duodenal stenting (n = 107)	*P* value	EUS-GE (n = 88)	Duodenal stenting (n = 88)	*P* value
Age, years						
▪ Mean (SD)	66 (11.8)	67 (11.2)	0.54	66 (12.1)	66 (10.4)	0.98
Female sex, n (%)	54 (50.5)	58 (54.2)	0.68	44 (50.0)	48 (54.5)	0.65
Follow-up duration, median (IQR), days	90.5 (44–177)	50 (27–126)	0.01	103 (43–184)	51 (30–126)	0.01
Primary disease, n (%)						
▪ Pancreatic cancer	50 (46.7)	70 (65.4)	0.009	50 (56.8)	56 (63.6)	0.44
▪ Biliary tract cancer	15 (14.0)	7 (6.5)	0.11	11 (12.5)	5 (5.7)	0.19
▪ Gastric cancer	12 (11.2)	8 (7.5)	0.48	8 (9.1)	7 (7.9)	> 0.99
▪ Duodenal cancer	10 (9.3)	10 (9.3)	> 0.99	8 (9.1)	10 (11.4)	0.80
▪ Other	20 (18.7)	12 (11.2)	0.18	11 (12.5)	10 (11.4)	> 0.99
Disease stage, n (%)	n = 104	n = 106				
▪ Local invasion	34 (32.7)	45 (42.5)	0.16	32 (36.4)	35 (39.8)	0.76
▪ Liver metastases	20 (19.2)	17 (16.0)	0.72	20 (22.7)	15 (17.0)	0.45
▪ Peritoneal metastases	14 (13.5)	8 (7.5)	0.26	9 (10.2)	8 (9.1)	> 0.99
▪ Diffuse metastatic	36 (34.6)	36 (34.0)	> 0.99	27 (30.7)	30 (34.1)	0.78
Disease manifestations, n (%)						
▪ Ascites	31 (29.0)	24 (22.4)	0.28	23 (26.1)	22 (25.0)	0.86
▪ Peritoneal carcinomatosis	44 (41.1)	27 (25.2)	0.02	28 (31.8)	25 (28.4)	0.74

EUS-GE, endoscopic ultrasound-guided gastroenterostomy; IQR, interquartile range.

11.5), the majority being female (52.3 %), and the underlying disease being pancreatic cancer (56.8 %), while peritoneal metastasis and ascites were present in up to a third of patients.

Technical success was achieved in 83/88 (94 %; 95 %CI 89 %–99 %) EUS-GE patients and in 86/88 (98 %; 95 %CI 95 %–100 %) duodenal stenting patients, with no significant difference between the two groups ($P = 0.44$) (▶ **Table 2**). Clinical success rate was higher after EUS-GE (80/88; 91 %; 95 %CI 85 %–97 %) than after duodenal stenting (66/88; 75 %; 95 %CI 66 %–84 %; $P = 0.008$). Per-protocol clinical success was 96 % (95 %CI 92 %–100 %) after EUS-GE and 77 % (95 %CI 68 %–86 %) after duodenal stenting, which was a significant difference ($P < 0.001$). Median time to clinical success was shorter after EUS-GE (1 day [IQR 1–2]) than after duodenal stenting (2 days [IQR 2–3]; $P < 0.001$). Median length of hospitalization was similar between the two groups, at 4 days (IQR 2–10.8) after EUS-GE vs. 4 days (IQR 1–9.5) after duodenal stenting.

Median follow-up was 85 days (IQR 43–157) in the EUS-GE group and 57 days (IQR 18.5–130.5) in the duodenal stenting group. Recurrent GOO occurred in 1/80 (1 %; 95 %CI 0–4 %) EUS-GE patient due to stent migration after 243 days, and in 17/66 duodenal stenting patients (26 %; 95 %CI 15 %–37 %; $P < 0.001$). Median time to stent dysfunction was 243 days after EUS-GE and 57 days (IQR 27–169.5) after duodenal stenting. Kaplan–Meier analysis showed higher probability of dysfunction-free survival for EUS-GE (hazard ratio 27.4, 95 %CI 4.2–28.2; $P < 0.001$) with a 6-month probability of remaining recurrence free of 100 % compared with 65.0 % with duodenal stenting (▶ **Fig. 3**). Both recurrent GOO rates and stent dysfunction-free survival rate by Kaplan–Meier analyses revealed a significantly higher stent dysfunction rate after duodenal stenting compared with EUS-GE.

AEs occurred in 9/88 patients (10.2 %; 95 %CI 3.8 %–16.7 %) after EUS-GE and in 18/88 patients (20.5 %; 95 %CI 11.9 %–29.0 %) after duodenal stenting, and were similar between the two groups ($P = 0.09$). The AEs in the EUS-GE group consisted of infectious complications (aspiration pneumonia [n = 1; 1.1 %] or cholangitis [n = 3; 3.4 %]), bleeding (n = 1; 1.1 %), and post-procedural pain (n = 1; 1.1 %); in three cases (3.4 %) intraperitoneal LAMS maldeployment resulted in emergency salvage surgery. AEs after duodenal stenting comprised infectious complications, including aspiration pneumonia (n = 4; 4.5 %), cholangitis (n = 4; 4.5 %), post-procedural pain (n = 4; 4.5 %), bleeding (n = 3; 3.4 %), atrial fibrillation (n = 1; 1.1 %), and stent migration (n = 1; 1.1 %). Aspiration pneumonia occurred in four patients who were under general anesthesia with tracheal intubation, and in

▶ **Table 2** Matched cohort: outcome comparisons.

	EUS-GE (n = 88)	Duodenal stenting (n = 88)	OR (95 %CI)
Efficacy			
Primary outcomes			
▪ Technical success, n (%) [95 %CI]	83 (94) [89–99]	86 (98) [95–100]	0.39 (0.07–2.04)
▪ Clinical success, n (%) [95 %CI]	80 (91) [85–97]	66 (75) [66–84]	3.33 (1.39–8.00)
▪ Per-protocol clinical success, n (%) [95 %CI]	80 (96) [92–100]	66 (77) [68–86]	8.06 (2.30–28.57)
▪ Time to clinical success, median (IQR), days	1 (1–2)	2 (2–3)	
▪ Time to oral intake, median (IQR), days	1 (0–1)	1 (0–1)	
▪ Recurrence of obstructive symptoms, n (%) [95 %CI]*	1 (1) [0–4]	17 (26) [15–37]	0.04 (0.01–0.28)
▪ Time to recurrent obstructive symptoms, median (IQR), days	243 (N/A)	57 (27–169.5)	
Secondary outcomes			
▪ Length of hospital stay, median (IQR), days	4 (2–10.8)	4 (1–9.5)	
▪ Survival, median (IQR), days	85 (43–157)	57 (18.5–130.5)	
Safety			
Overall adverse events, n (%) [95 %CI]	9 (10.2) [3.8–16.7]	18 (20.5) [11.9–29.0]	0.44 (0.19–1.05)
ASGE AE severity grading system, n (%) [95 %CI]			
▪ Mild	2 (2.3) [0–5.5]	6 (6.8) [1.5–12.2]	0.32 (0.06–1.62)
▪ Moderate	3 (3.4) [0–7.3]	9 (10.2) [3.8–16.7]	0.31 (0.08–1.19)
▪ Severe	4 (4.5) [0.1–9.0]	2 (2.3) [0–5.5]	2.05 (0.37–11.49)
▪ Fatal	0 (0)	1 (1.1) [0–3.4]	0.99 (0.97–1.01)

EUS-GE, endoscopic ultrasound-guided gastroenterostomy; OR, odds ratio; IQR, interquartile range; N/A, not applicable; ASGE, American Society for Gastrointestinal Endoscopy; AE, adverse event.
* Per-protocol cohorts.

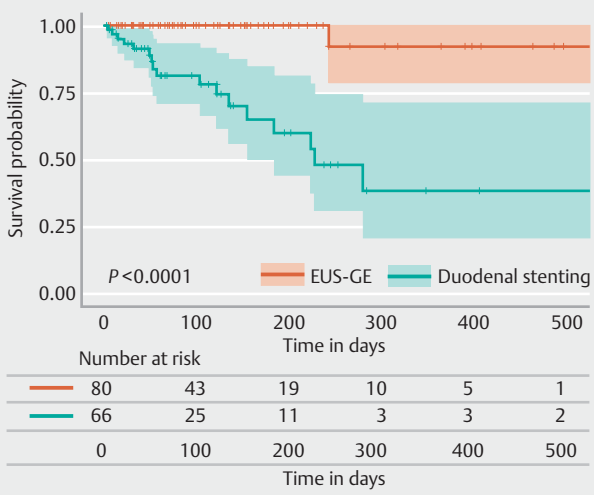

▶ **Fig. 3** Kaplan–Meier curve with time to event (stent dysfunction) analysis (log-rank test $P < 0.001$). EUS-GE, endoscopic ultrasound-guided gastroenterostomy.

one patient under deep sedation. The severity of AEs was not significantly different between EUS-GE and duodenal stenting (▶ **Table 2**). Median survival after EUS-GE was 85 days (43–157) vs. 57 days (18.5–130.5) after duodenal stenting.

Discussion

This study reports the first propensity score-matched comparison between EUS-GE and endoscopic duodenal stenting in malignant GOO, and contains, to the best of our knowledge, the largest comparative cohort published to date. Our data indicate that, while technical success was similar between the two groups, EUS-GE showed higher clinical success, superior long-term stent patency, and similar AE rates compared with duodenal stenting.

To date, two smaller unmatched retrospective studies compared EUS-GE with duodenal stenting in malignant GOO [13, 14]. A recent meta-analysis included an additional three abstracts resulting in a total of 659 patients published in the literature [21]. None of these studies used propensity score matching in an attempt to correct for confounders such as the type of underlying malignancy, peritoneal carcinomatosis, or the presence of ascites.

▶ **Table 3** Overview of largest series on endoscopic ultrasound-guided gastroenterostomy and endoscopic enteral stenting.*

First author, year [ref.]	Design, geographic area	Patients, study dates	Treatment and technical details	Efficacy, %	Safety, AEs, %	Long-term outcomes
EUS-GE						
Bejjani, 2021 [22]	Retrospective multicenter Europe (7), North America (12)	n = 267 2018–2020	EUS-GE Freehand EC-LAMS, or balloon assisted EUS-GE	Tech. success: 95.5 Clin. success: 87.0	12.4	Follow-up: 72 days (IQR 23–160) Recurrence: 6.4 %
Current study	Retrospective, multicenter Europe (3)	n = 107 2015–2021	EUS-GE Freehand EC-LAMS	Tech. success: 94.4 Clin. success: 89.7	12.1	Follow-up: 91 days (IQR 44–177) Recurrence: 3.1 %
Endoscopic enteral stent						
Lee, 2009 [24]	Prospective, single center Asia	n = 154 1998–2007	UCSEMS, PCSEMS	Tech. success: 100 Clin. success: 97.4	3.2	Follow-up: 108 days (95 %CI 60–151) Recurrence: 17.5 %
Costamagna, 2012 [23]	Prospective, multicenter Australia (1), Europe (9), North America (2)	n = 202 2006–2008	UCSEMS	Tech. success: 98.0 Clin. success: 91.0	10.9	Follow-up: 94 days (95%CI 79–112) Recurrence: 14.4%
Tringali, 2014 [25]	Prospective, multicenter Africa (1), Australia (1), Europe (3), North America (1), South America (1)	n = 106 2009–2011	UCSEMS	Tech. success: 99.1 Clin. success: 84.5	25.0	Follow-up: 47 days (range 0–195) Recurrence: 17.6 %
Current study	Retrospective, multicenter Europe (3)	n = 107 2015–2021	UCSEMS	Tech. success: 98.1 Clin. success: 76.6	17.8	Follow-up: 50 days (IQR 27–126) Recurrence: 29.3 %

AE, adverse event; EUS-GE, endoscopic ultrasound-guided gastroenterostomy; EC-LAMS, electrocautery-enhanced lumen-apposing metal stent; Tech., technical; Clin., clinical; IQR, interquartile range; UCSEMS, uncovered self-expandable metal stent; PCSEMS, partially covered self-expandable metal stent.
* Studies describing treatment of malignant gastric outlet obstruction with either EUS-GE or endoscopic enteral stent comprising > 100 cases were selected. Prospective studies were preferred over retrospective studies when available. AEs are reported using the definition of the current study.

In the current study, clinical success rates, using an intention-to-treat analysis, were significantly higher after EUS-GE than after duodenal stenting. Similar clinical success rates of EUS-GE were recently reported in a retrospective analysis of 19 centers including 267 patients (▶ **Table 3**) [22]. Clinical success rates of duodenal stenting were slightly lower compared with previous large studies on this topic, which may be related to the relatively high incidence of peritoneal carcinomatosis in our study (▶ **Table 3**) [23–25]. When comparing only technically successful procedures (per-protocol analysis) in our study, the benefit of EUS-GE with regard to clinical success was even more striking. EUS-GE has several features that may explain this superior clinical benefit. First, the short length of the LAMS (1.5 cm) is likely to facilitate food passage into the small intestine better than the longer duodenal stent (6–12 cm). Second, the LAMS in EUS-GE is placed some distance away from the tumor and expands to its full diameter, whereas compression by the tumor may prevent the SEMS from reaching its full diameter, which may impair food passage. The positive effect of a larger stent diameter was confirmed by our previous and other studies showing a superior clinical effect of the 20-mm over the 15-mm LAMS when compared with surgical gastroenterostomy [9, 22]. In addition, the time to clinical success, considered one of the most beneficial features of duodenal stenting, was even further reduced in the EUS-GE group.

Endoscopic duodenal stenting is prone to recurrent GOO due to tumor ingrowth through the meshes of the stent [23–25]. In line with these findings, almost one-third of patients with duodenal stents in the current study experienced stent dysfunction. The use of a covered SEMS instead of an uncovered SEMS has been shown to prevent tumor ingrowth and reduce stent dysfunction [26]. Covered SEMSs are, however, associated with a higher risk of stent migration and post-procedural pancreatitis due to obstruction of the papilla, and are seldom used given these concerns [27, 28]. In EUS-GE, the stent is placed at a distance from the tumor, so that stent obstruction due to tumor ingrowth is seldom a concern. In the current analysis, stent dysfunction occurred in only 1.3 % of cases, which is in line with previous published data showing that stent obstruction in EUS-GE is uncommon and generally caused by either food impaction or buried LAMS [29].

EUS-GE is a more invasive procedure than duodenal stenting, and may lead to more severe AEs such as peritonitis and perforation, even requiring salvage surgery. Yet our study showed that, in the hands of endoscopists who have received adequate training in expert high-volume settings, EUS-GE is a safe procedure [30]. Indeed, in our series, AEs associated with

EUS-GE were not more frequent nor more severe than after duodenal stenting.

The choice of therapy for frail patients with malignant GOO remains a matter of debate and will only finally be resolved once the results from adequately powered randomized controlled trials become available. Currently, based on the outcomes of previously underpowered randomized studies comparing duodenal stenting with surgical gastroenterostomy, duodenal stenting is advocated for use in patients with a prognosis of less than 2–6 months or a poor performance status (World Health Organization [WHO] performance score ≥3), whereas surgical gastroenterostomy has been advised in fitter patients with a better prognosis [6, 7]. The findings of our study suggest that EUS-GE may offer a valuable alternative to the currently employed options: EUS-GE is similar to duodenal stenting as a minimally invasive option that provides rapid symptom relief and is associated with low morbidity and early hospital discharge, yet provides an anastomosis that achieves surgical-range efficacy. Together with the significantly lower need for re-interventions due to less stent dysfunction, EUS-GE thus seems preferable over duodenal stenting. The latest guideline of the European Society of Gastrointestinal Endoscopy indeed recommends EUS-GE, when performed in an expert setting, as an alternative to duodenal stenting or surgical gastroenterostomy [31]. Duodenal stenting may potentially be reserved for patients with an ultra-limited short-term prognosis in whom EUS-GE is not feasible, for instance when the proximal jejunal loop cannot be visualized from the stomach, or when a large volume of intervening ascites obscures localization of a jejunal loop preventing safe placement. The presence of ascites also warrants attention toward underlying diffuse peritoneal metastatic disease, which increases the risk of gastrointestinal dysmotility and downstream enteral obstruction. Both may severely affect the clinical success rate of EUS-GE as well as duodenal stenting, and should be considered as a relative contraindication.

Our study has certain limitations. The retrospective design introduces confounders. However, by using propensity score matching analysis, we have tried to overcome these limitations, allowing a fair comparison between the two techniques. Although data regarding most important confounders such as etiology, presence of ascites, and (peritoneal) metastases could be reliably collected retrospectively, others, such as WHO performance scale, could not. However, overall post-procedural survival was not different between the two groups after matching, reducing the concern of different baseline frailty.

Finally, despite the promising outcomes of the EUS-GE group, generalizability of these results outside tertiary academic centers with specific expertise in interventional EUS remains difficult. Moreover, to date, the procedure includes an off-label use of the LAMS.

In conclusion, this study showed that in patients with malignant GOO, EUS-GE and duodenal stenting displayed similar technical success and AEs rates. The higher clinical success, shorter time to clinical success, and lower GOO recurrence suggest that EUS-GE should be preferred over duodenal stenting when adequate expertise is available.

Conflict of interest

RLJ van Wanrooij is a consultant for Boston Scientific. M Bronswijk is a consultant for Taewoong – Prion Medical. W Laleman is Co-Chair of the Boston Scientific Therapeutic Biliopancreatic Endoscopy group, and is a consultant for Boston Scientific and Cook. H van Malenstein is a consultant for Boston Scientific. P Fockens is a consultant for Olympus and Cook Medical. SW van der Merwe is Co-Chair of the Boston Scientific Therapeutic Biliopancreatic Endoscopy group and Chair of the Portal Hypertension group for Cook; he is also a consultant for Cook, Boston Scientific, and Pentax. RP Voermans is a consultant for Boston Scientific and has received research grants from Boston Scientific and Taewoong - Prion Medical. The remaining authors declare that they have no conflict of interest.

References

[1] Tendler DA. Malignant gastric outlet obstruction: bridging another divide. Am J Gastroenterol 2002; 97: 4–6

[2] Zu H, Wang H, Li C et al. The predictive and prognostic factors in patients with gastric cancer accompanied by gastric outlet obstruction. Gastroenterol Res Pract 2020; 2020: 6529563

[3] Fiori E, Lamazza A, Volpino P et al. Palliative management of malignant antro-pyloric strictures. Gastroenterostomy vs. endoscopic stenting. A randomized prospective trial. Anticancer Res 2004; 24: 269–271

[4] Jeurnink SM, Steyerberg EW, van Hooft JE et al. Surgical gastrojejunostomy or endoscopic stent placement for the palliation of malignant gastric outlet obstruction (SUSTENT study): a multicenter randomized trial. Gastrointest Endosc 2010; 71: 490–499

[5] Mehta S, Hindmarsh A, Cheong E et al. Prospective randomized trial of laparoscopic gastrojejunostomy versus duodenal stenting for malignant gastric outflow obstruction. Surg Endosc 2006; 20: 239–242

[6] Ahmed O, Lee JH, Thompson CC et al. AGA Clinical practice update on the optimal management of the malignant alimentary tract obstruction: expert review. Clin Gastroenterol Hepatol 2021; 19: 1780–1788

[7] Ahmed O, Lee JH, Thompson CC et al. AGA Clinical Practice Update on the Optimal Management of the Malignant Alimentary Tract Obstruction: Expert Review. Clin Gastroenterol Hepatol 2021; 19: 1780–1788

[8] van Halsema EE, Rauws EA, Fockens P et al. Self-expandable metal stents for malignant gastric outlet obstruction: a pooled analysis of prospective literature. World J Gastroenterol 2015; 21: 12468–12481

[9] Bronswijk M, Vanella G, van Malenstein H et al. Laparoscopic versus EUS-guided gastroenterostomy for gastric outlet obstruction: an international multicenter propensity score-matched comparison (with video). Gastrointest Endosc 2021; 94: 526–536

[10] Khashab MA, Bukhari M, Baron TH et al. International multicenter comparative trial of endoscopic ultrasonography-guided gastroenterostomy versus surgical gastrojejunostomy for the treatment of malignant gastric outlet obstruction. Endosc Int Open 2017; 5: E275–E281

[11] Perez-Miranda M, Tyberg A, Poletto D et al. EUS-guided gastrojejunostomy versus laparoscopic gastrojejunostomy: an international collaborative study. J Clin Gastroenterol 2017; 51: 896–899

[12] Kouanda A, Binmoeller K, Hamerski C et al. Endoscopic ultrasound-guided gastroenterostomy versus open surgical gastrojejunostomy: clinical outcomes and cost effectiveness analysis. Surg Endosc 2021; 35: 7058–7067

[13] Chen YI, Itoi T, Baron TH et al. EUS-guided gastroenterostomy is comparable to enteral stenting with fewer re-interventions in malignant gastric outlet obstruction. Surg Endosc 2017; 31: 2946–2952

[14] Ge PS, Young JY, Dong W et al. EUS-guided gastroenterostomy versus enteral stent placement for palliation of malignant gastric outlet obstruction. Surg Endosc 2019; 33: 3404–3411

[15] Adler DG, Baron TH. Endoscopic palliation of malignant gastric outlet obstruction using self-expanding metal stents: experience in 36 patients. Am J Gastroenterol 2002; 97: 72–78

[16] Cotton PB, Eisen GM, Aabakken L et al. A lexicon for endoscopic adverse events: report of an ASGE workshop. Gastrointest Endosc 2010; 71: 446–454

[17] Bronswijk M, van Malenstein H, Laleman W et al. EUS-guided gastroenterostomy: less is more! The wireless EUS-guided gastroenterostomy simplified technique VideoGIE 2020; 5: 442

[18] Hori Y, Naitoh I, Hayashi K et al. Predictors of stent dysfunction after self-expandable metal stent placement for malignant gastric outlet obstruction: tumor ingrowth in uncovered stents and migration of covered stents. Surg Endosc 2017; 31: 4165–4173

[19] Suder-Castro LS, Ramirez-Solis ME, Hernandez-Guerrero AI et al. Predictors of self-expanding metallic stent dysfunction in malignant gastric outlet obstruction. Rev Gastroenterol Mex (Engl Ed) 2020; 85: 275–281

[20] Wannhoff A, Ruh N, Meier B et al. Endoscopic gastrointestinal anastomoses with lumen-apposing metal stents: predictors of technical success. Surg Endosc 2021; 35: 1997–2004

[21] Chandan S, Khan SR, Mohan BP et al. EUS-guided gastroenterostomy versus enteral stenting for gastric outlet obstruction: systematic review and meta-analysis. Endosc Int Open 2021; 9: E496–E504

[22] Bejjani M, Ghandour B, Subtil JC et al. Clinical and technical outcomes of patients undergoing endoscopic ultrasound-guided gastroenterostomy using 20-mm vs. 15-mm lumen-apposing metal stents. Endoscopy 2021: doi:10.1055/a-1654-6914

[23] Costamagna G, Tringali A, Spicak J et al. Treatment of malignant gastroduodenal obstruction with a nitinol self-expanding metal stent: an international prospective multicentre registry. Dig Liver Dis 2012; 44: 37–43

[24] Lee KM, Choi SJ, Shin SJ et al. Palliative treatment of malignant gastroduodenal obstruction with metallic stent: prospective comparison of covered and uncovered stents. Scand J Gastroenterol 2009; 44: 846–852

[25] Tringali A, Didden P, Repici A et al. Endoscopic treatment of malignant gastric and duodenal strictures: a prospective, multicenter study. Gastrointest Endosc 2014; 79: 66–75

[26] Pan YM, Pan J, Guo LK et al. Covered versus uncovered self-expandable metallic stents for palliation of malignant gastric outlet obstruction: a systematic review and meta-analysis. BMC Gastroenterol 2014; 14: 170

[27] Maetani I, Ukita T, Tada T et al. Metallic stents for gastric outlet obstruction: reintervention rate is lower with uncovered versus covered stents, despite similar outcomes. Gastrointest Endosc 2009; 69: 806–812

[28] van Hooft JE, Uitdehaag MJ, Bruno MJ et al. Efficacy and safety of the new WallFlex enteral stent in palliative treatment of malignant gastric outlet obstruction (DUOFLEX study): a prospective multicenter study. Gastrointest Endosc 2009; 69: 1059–1066

[29] Kastelijn JB, Moons LMG, Garcia-Alonso FJ et al. Patency of endoscopic ultrasound-guided gastroenterostomy in the treatment of malignant gastric outlet obstruction. Endosc Int Open 2020; 8: E1194–E1201

[30] Jovani M, Ichkhanian Y, Parsa N et al. Assessment of the learning curve for EUS-guided gastroenterostomy for a single operator. Gastrointest Endosc 2021; 93: 1088–1093

[31] van der Merwe SW, van Wanrooij RLJ, Bronswijk M et al. Therapeutic endoscopic ultrasound: European Society of Gastrointestinal Endoscopy (ESGE) Guideline. Endoscopy 2022; 54: 185–205