



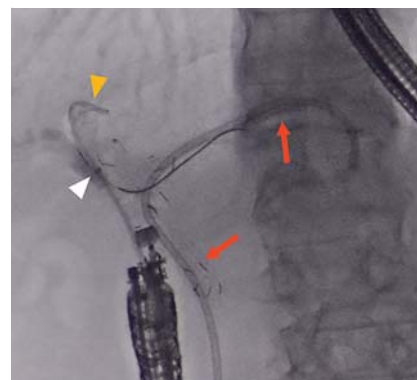
Facile and secure deployment of plastic stent through an endoscopic tapered sheath for endoscopic ultrasound-guided drainage



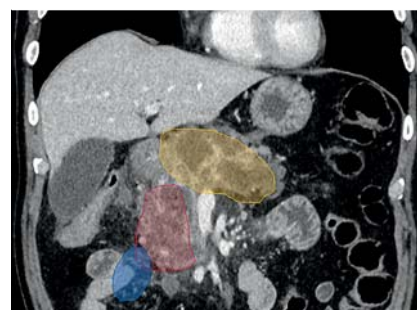
► **Fig. 1** The endoscopic tapered sheath (EndoSheather). The calibers of the inner catheter and outer sheath at the device tip had a negligible difference. The internal and external diameters of the outer sheath are 6.2 Fr (2.06 mm) and 7.2 Fr (2.44 mm), respectively. The outer sheath tip has a radiopaque marker (white arrowhead).



► **Fig. 2** Plastic stent insertion through the outer sheath of the EndoSheather (6Fr double pigtail plastic stent, lower right box).



► **Fig. 3** Fluoroscopic cholangiogram showing endoscopic ultrasound-guided hepaticoduodenostomy (Case 1). Red arrows indicate the deployed stents under endoscopic retrograde cholangiopancreatography. The 6Fr double pigtail plastic stent (yellow arrowhead) was deployed through the outer sheath of the EndoSheather. White arrowhead indicates the radiopaque marker of the outer sheath.



► **Fig. 4** Contrast-enhanced computed tomography showing the three cavities (yellow, red, and blue zones) of the walled-off necrosis in Case 2.

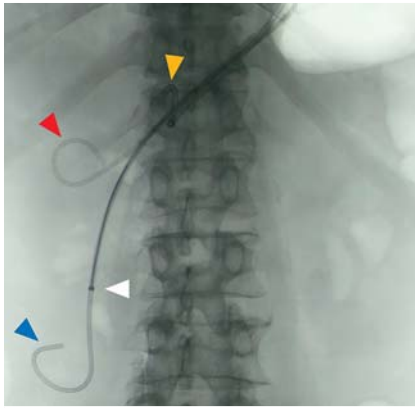
Endoscopic ultrasound (EUS)-guided drainage is a promising treatment for a variety of conditions, such as obstructive jaundice and peripancreatic fluid collection [1,2]. Despite recent improvement in stents, EUS-guided drainage is often complicated because it is sometimes difficult to pass a plastic stent, especially a double pigtail stent, through a fistula even after dilation. Therefore, we used a newly developed endoscopic tapered sheath (EndoSheather; Piolax, Inc., Kanagawa, Japan) (► **Fig. 1**, ► **Fig. 2**) [3] in two patients. This device allows fistula dilation and subsequent easy insertion of the plastic stent (up to 6Fr in diameter) through the indwelling outer sheath, which bridges to the target space, thereby eliminating the need to remove the

device. Hence, this technique may improve the outcomes of EUS-guided drainage, especially when performed by novice interventional endoscopists.


Case 1: A 90-year-old man with hilar cholangiocarcinoma and obstructive cholangitis in the posterior segmental branches of the bile duct underwent EUS-guided hepaticoduodenostomy. The B7 bile duct was punctured from the duodenum using a 19-gauge needle, and a 0.025-inch guidewire was placed. Then, the endoscopic tapered sheath was inserted into the bile duct to dilate the fistula. The inner catheter was removed, and the outer sheath was left in place inside the bile duct. Finally, a 6Fr double pigtail plastic stent (Zimmon; Cook Medical Inc., Winston-Salem, North Carolina,

USA) was deployed through the outer sheath (► **Fig. 3**).

Case 2: A 74-year-old man with three cavities of infected walled-off necrosis underwent EUS-guided transmural drainage. Multiple plastic stents were deployed through the single gate [4]. The cavity was punctured using a 19-gauge needle, and a 0.025-inch guidewire was placed. Then, the endoscopic tapered



► **Fig. 5** Fluoroscopic cholangiogram showing endoscopic ultrasound-guided transmural drainage (Case 2). Two 6Fr double pigtail plastic stents (yellow and red arrowheads) were already deployed in the cavities with the corresponding color. A 6Fr pigtail nasobiliary drainage tube (blue arrowhead) was inserted into the blue-colored cavity through the outer sheath of the EndoSheather (white arrowhead).



► **Video 1** The newly developed endoscopic tapered sheath allows fistula dilation and subsequent smooth insertion of a 6Fr double pigtail plastic stent through the indwelling outer sheath for endoscopic ultrasound-guided drainage.

sheath was used to dilate the fistula, and two additional guidewires were inserted into each cavity. Subsequently, two 6Fr double pigtail plastic stents followed by a 6Fr pigtail nasobiliary drainage tube were deployed through the outer sheath in sequence (► **Fig. 4**, ► **Fig. 5**, ► **Video 1**).

Endoscopy_UCTN_Code_TTT_1AS_2AD

Competing interests

The authors declare that they have no conflict of interest.

The authors

Yusuke Kito, Akihisa Kato, Michihiro Yoshida  **Makoto Natsume, Yasuki Hori, Itaru Naitoh, Kazuki Hayashi**
Department of Gastroenterology and Metabolism, Nagoya City University Graduate School of Medical Sciences, Nagoya, Japan

Corresponding author

Akihisa Kato, MD
Department of Gastroenterology and Metabolism, Nagoya City University Graduate School of Medical Sciences, 1 Kawasumi, Mizuho-cho, Mizuho-ku, Nagoya 467-8601, Japan
Fax: +81-52-852-0952
akihisa@med.nagoya-cu.ac.jp

References

- [1] Will U, Thieme A, Fuedner F et al. Treatment of biliary obstruction in selected patients by endoscopic ultrasonography (EUS)-guided transluminal biliary drainage. *Endoscopy* 2007; 39: 292–295
- [2] Guzmán-Calderón E, Chacaltana A, Díaz R et al. Head-to-head comparison between endoscopic ultrasound guided lumen apposing metal stent and plastic stents for the treatment of pancreatic fluid collections: a systematic review and meta-analysis. *J Hepatobiliary Pancreat Sci* 2021. doi:10.1002/jhbp.1008
- [3] Matsumori T, Uza N, Shiokawa M et al. Mapping biopsy for bile duct cancer using a novel device delivery system. *Endoscopy* 2021. doi:10.1055/a-1479-1969
- [4] Mukai S, Itoi T, Sofuni A et al. Novel single transluminal gateway transcystic multiple drainages after EUS-guided drainage for complicated multilocular walled-off necrosis (with videos). *Gastrointest Endosc* 2014; 79: 531–535

Bibliography

Endoscopy 2022; 54: E674–E675
DOI 10.1055/a-1747-3162
ISSN 0013-726X
published online 15.2.2022
© 2022. Thieme. All rights reserved.
Georg Thieme Verlag KG, Rüdigerstraße 14, 70469 Stuttgart, Germany

ENDOSCOPY E-VIDEOS
<https://eref.thieme.de/e-videos>



Endoscopy E-Videos is an open access online section, reporting on interesting cases and new techniques in gastroenterological endoscopy. All papers include a high quality video and all contributions are freely accessible online. Processing charges apply (currently EUR 375), discounts and waivers acc. to HINARI are available.

This section has its own submission website at
<https://mc.manuscriptcentral.com/e-videos>