


## Sequential endoscopic balloon dilations using a calibrated small-caliber-tip transparent hood for a patient with 10 ileal strictures secondary to Crohn's disease

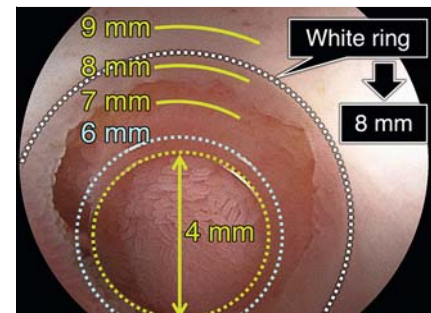
Patients with Crohn's disease may have multiple strictures of the small intestine, and surgical resection can lead to short-bowel syndrome. Endoscopic balloon dilation (EBD) is an alternative treatment to avoid surgical resection [1]; however, it is considered challenging to perform EBDs of multiple strictures. The calibrat-

ed small-caliber-tip transparent (CAST) hood (TOP Corporation, Tokyo, Japan) (► Fig. 1) [2] makes it easier to insert a guidewire and a balloon catheter through a stricture. The CAST hood enables measurement of the stricture's inner diameter (► Fig. 2), which is an important factor in choosing the appropriate size of balloon

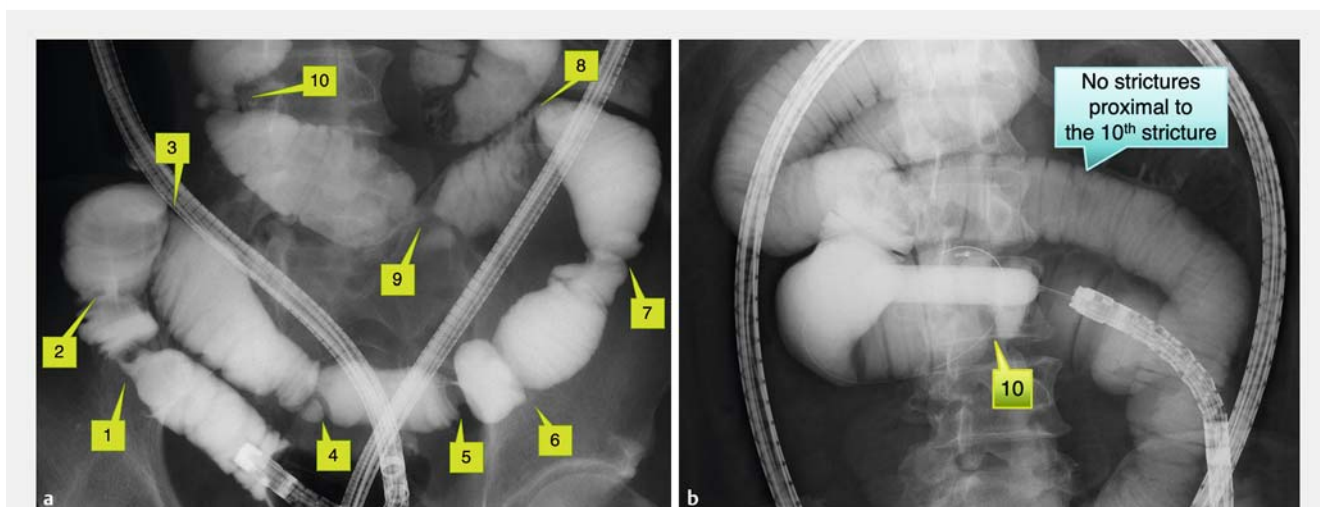
catheter for EBD. Although the passage through dilated strictures is frequently difficult, the CAST hood makes it easier to pass through post-EBD strictures. Therefore, the CAST hood makes it easier to perform EBDs of multiple strictures. Furthermore, endoscopic enteroclysis during double-balloon endoscopy (DBE)



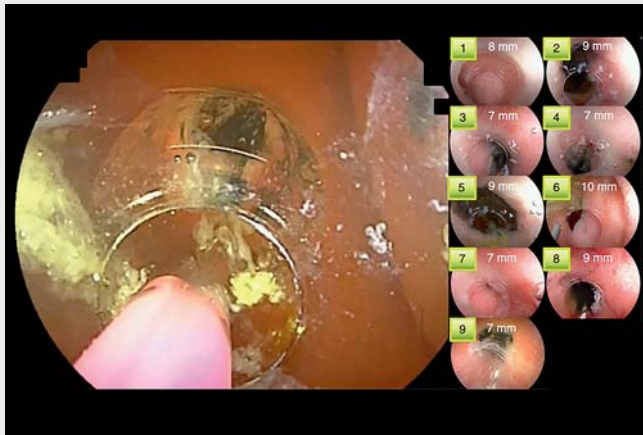
► Fig. 1 Photographs showing: **a** a close-up view of the calibrated small-caliber-tip transparent (CAST) hood; **b** the device fitted to the tip of a therapeutic-type double-balloon endoscope (EN-580T; Fujifilm, Tokyo, Japan).



► Fig. 2 Endoscopic view showing how the calibrated small-caliber-tip transparent (CAST) hood has calibration lines at 7, 8, and 9 mm on its outer wall, which enables measurement of the inner diameter of a stricture.



► Fig. 3 Radiographic images during retrograde double-balloon endoscopy showing: **a** 10 strictures revealed on endoscopic enteroclysis in a man with Crohn's disease; **b** after 6 months of induction therapy, dilation of all 10 strictures up to 13.5 mm by sequential endoscopic balloon dilation using the calibrated small-caliber-tip transparent (CAST) hood.



**Video 1** Sequential endoscopic balloon dilations using a calibrated small-caliber-tip transparent (CAST) hood for a patient with 10 ileal strictures secondary to Crohn's disease.

is helpful to evaluate multiple strictures. We can perform endoscopic enteroclysis more effectively by inflating the endoscope-tipped balloon, which blocks the backflow of contrast medium that is injected via the scope channel.

We here report a case involving multiple strictures treated by sequential EBDs. A 58-year-old man with Crohn's disease, with previous episodes of bowel obstruction, underwent a retrograde DBE. We found an ulcerated stricture at 35 cm proximal to the ileocecal valve. Endoscopic enteroclysis, in combination with the water exchange method, revealed a total of 10 strictures (► **Fig. 3 a**). Six months after remission induction therapy, we successfully performed sequential EBDs using DBE plus a CAST hood, resulting in the dilation of all 10 strictures up to 13.5 mm in a single procedure (► **Fig. 3 b**; ► **Video 1**). After this treatment, the patient's obstructive symptoms disappeared.

In conclusion, the CAST hood facilitates sequential EBDs for multiple strictures secondary to Crohn's disease. With the use of this method, the need for surgical intestinal resection might be avoided, even in patients with multiple strictures.

Endoscopy\_UCTN\_Code\_TTT\_1AP\_2AD

### Competing interests

Y. Hayashi and H. Yamamoto have patents for the calibrated small-caliber-tip transparent hood. H. Yamamoto also has patents for double-balloon endoscopy and is a consultant for Fujifilm. T. Yano and H. Sakamoto have received research funding and honoraria from Fujifilm. The remaining authors declare that they have no conflict of interest.

### The authors

**Kunihiko Oguro**<sup>1</sup> **Tomonori Yano**<sup>1</sup>   
**Hirotsugu Sakamoto**<sup>1</sup> **Manabu Nagayama**<sup>1</sup>   
**Yoshikazu Hayashi**<sup>1</sup> **Alan Kwarai Lefor**<sup>2</sup>   
**Hironori Yamamoto**<sup>1</sup>

- 1 Department of Medicine, Division of Gastroenterology, Jichi Medical University, Tochigi, Japan
- 2 Department of Surgery, Jichi Medical University, Tochigi, Japan

### Corresponding author

**Tomonori Yano, MD, PhD**  
 Department of Medicine, Division of Gastroenterology, Jichi Medical University, 3311-1 Yakushiji, Shimotsuke, Tochigi, 329-0498, Japan  
 tomonori@jichi.ac.jp

### References

- [1] Despott EJ, Gupta A, Burling D et al. Effective dilation of small-bowel strictures by double-balloon enteroscopy in patients with symptomatic Crohn's disease (with video). *Gastrointest Endosc* 2009; 70: 1030–1036
- [2] Hayashi Y, Yamamoto H, Yano T et al. A calibrated, small-caliber tip, transparent hood to aid endoscopic balloon dilation of intestinal strictures in Crohn's disease: successful use of prototype. *Endoscopy* 2013; 45: E373–E374

### Bibliography

*Endoscopy* 2022; 54: E664–E665

DOI 10.1055/a-1738-9357

ISSN 0013-726X

published online 15.2.2022

© 2022. Thieme. All rights reserved.

Georg Thieme Verlag KG, Rüdigerstraße 14, 70469 Stuttgart, Germany

### ENDOSCOPY E-VIDEOS

<https://eref.thieme.de/e-videos>



*Endoscopy E-Videos* is an open access online section, reporting on interesting cases and new techniques in gastroenterological endoscopy. All papers include a high quality video and all contributions are freely accessible online. Processing charges apply (currently EUR 375), discounts and waivers acc. to HINARI are available.

This section has its own submission website at <https://mc.manuscriptcentral.com/e-videos>