

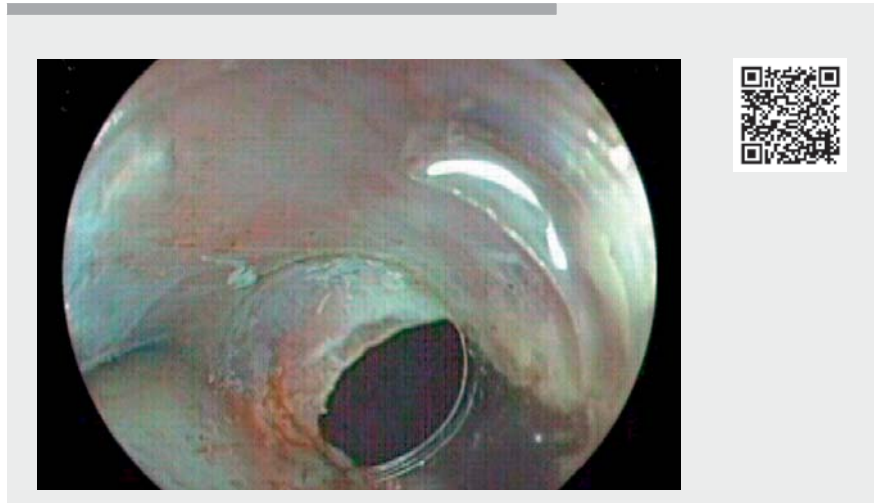## Clip-with-line traction suture method with adaptation of the mucosal flap in a large transmural defect after submucosal tunneling endoscopic resection of a submucosal tumor at the esophagogastric junction

Submucosal tunneling endoscopic resection (STER) [1] is a demanding technique that can potentially lead to serious complications [2,3]. A 51-year-old patient with solid food dysphagia underwent an esophagogastroduodenoscopy, which showed a subepithelial mass just below the esophagogastric junction (EGJ). Endoscopic ultrasound confirmed a well-demarcated 30×24mm subepithelial mass attached to the muscularis propria, predominantly hypoechoic but with some hyperechoic foci.

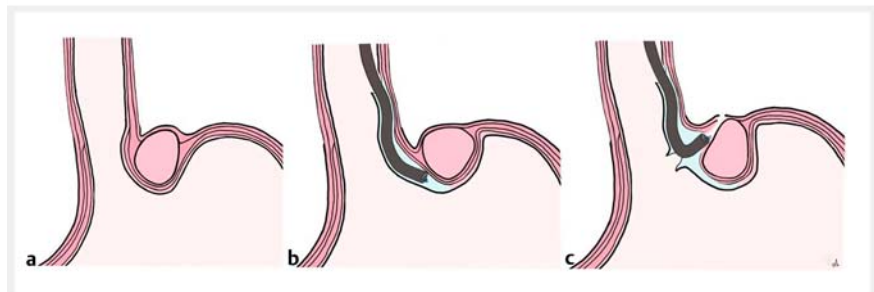
STER was performed using a Hybrid-Knife I-Type (Endocut-Q, Setting 2-3-3, Vio 300D; ERBE Elektromedizin, Tübingen, Germany) under low-flow carbon dioxide insufflation (► **Video 1**). A 2-cm longitudinal mucosal access was created in the esophagus, 4 cm proximal to the EGJ, and a submucosal tunnel was created until the submucosal lesion was found in the deep posterior muscularis propria layer (► **Fig. 1 a, b**). To avoid tumor capsule damage, the muscular layer had to be opened. Owing to the difficult position of the lesion, the scope had to be at maximum retroflexion for deep muscular layer preparation. However, a large mucosal tear was observed, caused by the traction exerted by the scope during the procedure, thus causing a large transmural perforation (► **Fig. 1 c**).

After tumor removal (► **Fig. 2 a**), a 16-mm hemostatic clip (Lockado-Clip, Microtech Europe, Duesseldorf, Germany) with medical floss was placed in the proximal margin of the mucosal flap. The floss was pulled to lift the mucosal flap upwards to cover the defect. Subsequently the tear was closed by attaching the side margins of the flap to the surrounding mucosa using 20-mm hemostatic clips (Lockado-Clip, Microtech Europe, Duesseldorf, Germany) (► **Fig. 2 b, c**).

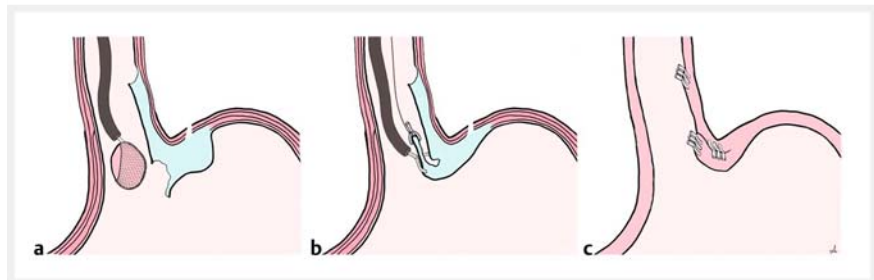
Broad-spectrum antibiotic therapy was given. The following day, an esophagram confirmed no leakage and a liquid



► **Video 1** Clip-with-line traction suture method with adaptation of the mucosal flap in a large transmural defect after submucosal tunneling endoscopic resection.



► **Fig. 1** Schema of submucosal tunneling endoscopic resection technique. **a** Submucosal tumor. **b** Submucosal tunneling. **c** Muscular layer dissection and evidence of a mucosal tear.



► **Fig. 2** Closure of the tear. **a** Complete resection and tumor removal. **b** Clip-with-line traction suture method. **c** Complete defect closure by mucosal flap and tunnel entrance closure.

diet was started. After follow-up endoscopy on Day 3, the patient received a semi-liquid diet and was then discharged on a regular diet. There were no complications during the follow-up. Histology showed a leiomyoma.

The clip-with-line traction suture method was previously described to align mucosal margins to allow easier defect closure after submucosal dissection [4]. In the current case, it was used to close the mucosal flap over the tear.

Endoscopy\_UCTN\_Code\_CPL\_1AH\_2AJ

### Competing interests

The authors declare that they have no conflict of interest.

### The authors

**Annalisa Cappello**<sup>1</sup>, **Sofia Xavier**<sup>2</sup>, **Horst Neuhaus**<sup>3</sup>, **Torsten Beyna**<sup>3</sup>, **Christian Gerges**<sup>3</sup>

1 AUSL Bologna, Bologna, Italy

2 Hospital Senhora da Oliveira, Guimarães, Portugal

3 Evangelisches Krankenhaus, Düsseldorf, Germany

### Corresponding author

**Annalisa Cappello, MD**

AUSL Bologna, Department of Gastroenterology and Interventional Endoscopy, Largo Nigrisoli 2, 40133 Bologna (BO), Italy  
annalisacappello@yahoo.it

### References

- [1] Xu MD, Cai MY, Zhou PH et al. Submucosal tunneling endoscopic resection: a new technique for treating upper GI submucosal tumors originating from the muscularis propria layer (with videos). *Gastrointest Endosc* 2012; 75: 195–199
- [2] Lv XH, Wang CH, Xie Y. Efficacy and safety of submucosal tunneling endoscopic resection for upper gastrointestinal submucosal tumors: a systematic review and meta-analysis. *Surg Endosc* 2017; 31: 49–63
- [3] Chen T, Zhang C, Yao LQ et al. Management of the complications of submucosal tunneling endoscopic resection for upper gastrointestinal submucosal tumors. *Endoscopy* 2016; 48: 149–155
- [4] Wang C, Wang Y, Li Y et al. A clip-with-line traction suture method for closing mucosal defects after endoscopic submucosal dissection. *Gastroenterol Res Pract* 2021; 2021: 8817726

### Bibliography

*Endoscopy* 2022; 54: E646–E647

DOI 10.1055/a-1731-7268

ISSN 0013-726X

published online 4.2.2022

© 2022. Thieme. All rights reserved.

Georg Thieme Verlag KG, Rüdigerstraße 14, 70469 Stuttgart, Germany

#### ENDOSCOPY E-VIDEOS

<https://eref.thieme.de/e-videos>



*Endoscopy E-Videos* is an open access online section, reporting on interesting cases and new techniques in gastroenterological endoscopy. All papers include a high quality video and all contributions are freely accessible online. Processing charges apply (currently EUR 375), discounts and waivers acc. to HINARI are available.

This section has its own submission website at

<https://mc.manuscriptcentral.com/e-videos>