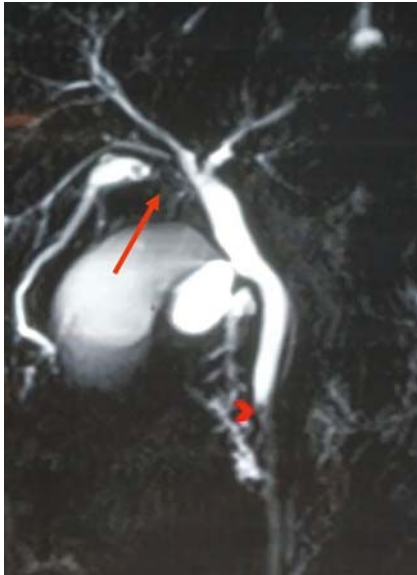

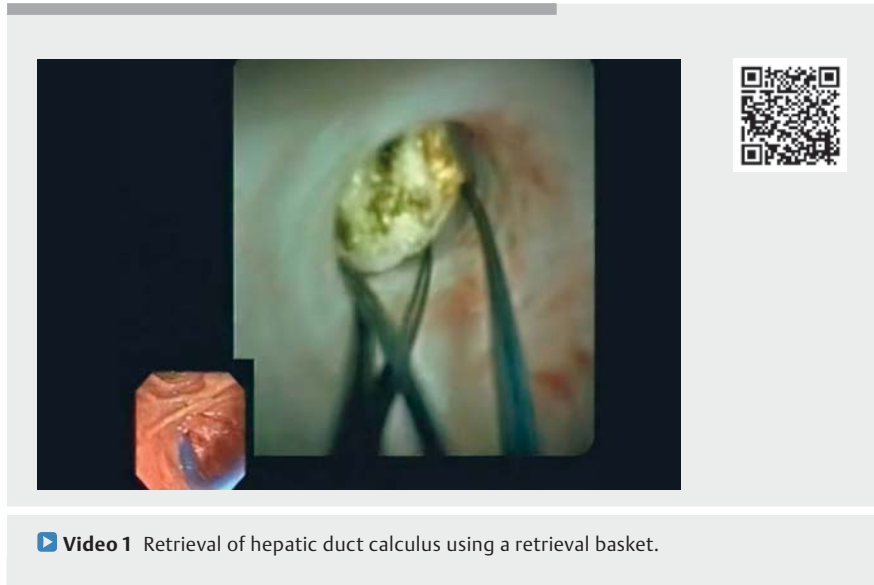
Successful extraction of hepatic duct calculus using retrieval basket under cholangioscopic guidance



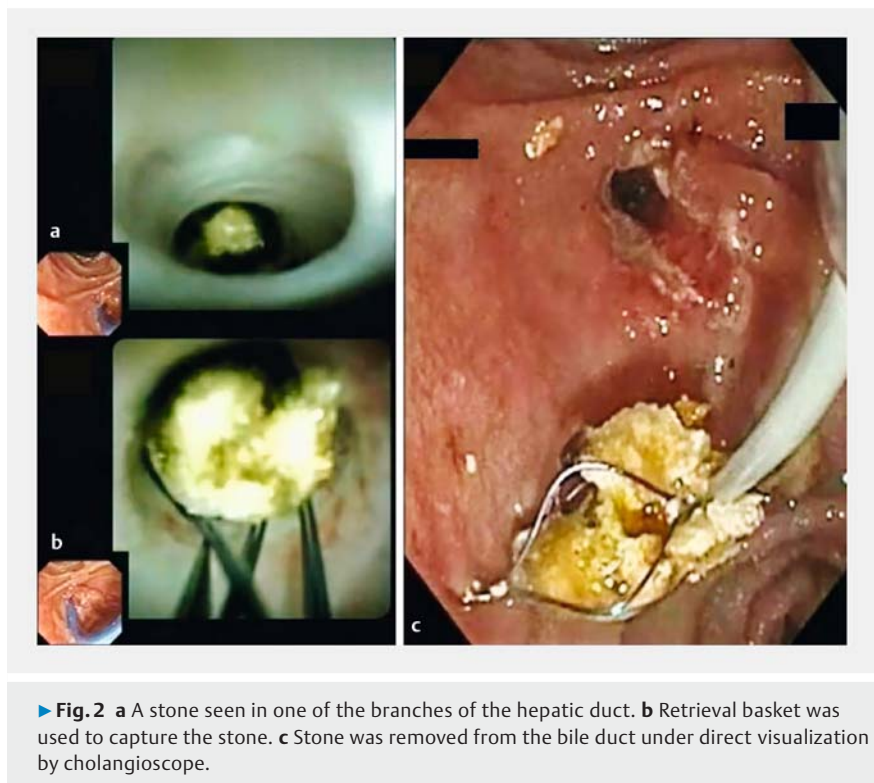
► **Fig. 1** Magnetic resonance cholangiopancreatography revealed one calculus in the right anterior sectoral duct (arrow) and another small calculus in the distal bile duct (arrow head).

Hepatoolithiasis or intrahepatic duct calculi is one of the most complex stone diseases as it poses a great challenge in treatment and also has strong propensity for recurrence. It may be complicated by bile duct strictures, cholangiolytic abscesses, and cholangiocarcinoma [1]. The main endpoint of the treatment for hepatoolithiasis would be stone clearance, stricture correction, and restoration of biliary drainage [2].

A 27-year-old woman was referred to our department for right upper quadrant pain of the abdomen and fever for 3 days. Patient was hemodynamically stable. Her blood investigations were unremarkable except for elevated liver enzymes (AST 69 IU/L, ALT 71 IU/L, and ALP 354 IU/L). Magnetic resonance cholangiopancreatography showed one calculus measuring 6 mm in the right anterior sectoral duct with upstream biliary dilatation and another small calculus in the distal bile duct (► **Fig. 1**).



► **Video 1** Retrieval of hepatic duct calculus using a retrieval basket.



► **Fig. 2** **a** A stone seen in one of the branches of the hepatic duct. **b** Retrieval basket was used to capture the stone. **c** Stone was removed from the bile duct under direct visualization by cholangioscope.

Endoscopic retrograde cholangiopancreatography (ERCP) revealed a filling defect in the lower end of the bile duct and

in the right hepatic duct. The sludge material came out after biliary sphincterotomy. A cholangioscope (SpyGlass DS;

Boston Scientific, Natick, Massachusetts, USA) was inserted into the bile duct (► **Video 1**) and a stone was seen in one of the branches of the hepatic duct (► **Fig. 2a**). The stone was captured using the SpyGlass retrieval basket (Boston Scientific) after negotiating the guide-wire (► **Fig. 2b**). Finally, the stone was removed from the bile duct under direct visualization by cholangioscope (► **Fig. 2c**).

There are only few cases of bile duct stone extraction using this retrieval basket reported in the literature [3]. Extraction of hepatic duct stones using a retrieval basket is quite challenging and reports of such cases are scarce.

Endoscopy_UCTN_Code_CCL_1AF_2AF_3AB

Competing interests

The authors declare that they have no conflict of interest.

The authors

Mahesh Kumar Goenka¹, Shivaraj Afzalpurkar¹, Gajanan Ashokrao Rodge¹, Usha Goenka²

- 1 Apollo Multispeciality Hospital, Institute of Gastrosciences and Liver, Kolkata, India
- 2 Apollo Multispeciality Hospital, Department of Clinical Imaging and Interventional Radiology, Kolkata, India

Corresponding author

Mahesh Kumar Goenka, MD

Institute of Gastrosciences and Liver, Day care, 4th floor, Apollo Hospital, 58 Canal Circular Road, Kolkata, 700054, India
mkgkolkata@gmail.com

References

- [1] Uenishi T, Hamba H, Takemura S. Outcomes of hepatic resection for hepatolithiasis. *Am J Surg* 2009; 198: 199–202
- [2] Huang ZQ, Xu LN, Tao YA et al. Hepatic resection: an analysis of the impact of operative and perioperative factors on morbidity and mortality rates in 2008 consecutive hepatectomy cases. *Chin Med J (Engl)* 2009; 122: 2268–2277
- [3] Han S, Shah RJ. Cholangioscopy-guided basket retrieval of impacted stones. *VideoGIE* 2020; 5: 387–388

Bibliography

Endoscopy 2022; 54: E656–E657

DOI 10.1055/a-1731-7223

ISSN 0013-726X

published online 15.2.2022

© 2022. Thieme. All rights reserved.

Georg Thieme Verlag KG, Rüdigerstraße 14, 70469 Stuttgart, Germany

ENDOSCOPY E-VIDEOS

<https://eref.thieme.de/e-videos>



Endoscopy E-Videos is an open access online section, reporting on interesting cases and new techniques in gastroenterological endoscopy. All papers include a high quality video and all contributions are freely accessible online. Processing charges apply (currently EUR 375), discounts and waivers acc. to HINARI are available.

This section has its own submission website at

<https://mc.manuscriptcentral.com/e-videos>